

TRABAJO DE FIN DE GRADO

Grado en odontología

CARILLAS NO-PREP

Madrid, curso 2020/2021

Número identificativo

88

RESUMEN

La preservación de tejido dentario es una de las mayores preocupaciones de la odontología en la actualidad, por ello, los tratamientos conservadores están tomando cada vez más importancia. Entre estos tratamientos se encuentran las carillas *no-prep* de porcelana, que mejora la estética de la sonrisa con una pérdida nula o escasa de estructura dentaria.

Objetivos: describir el concepto de carillas *no-prep*, así como sus ventajas y desventajas; indicaciones y contraindicaciones; y los materiales cerámicos de fabricación.

Metodología: se realizó un análisis de artículos buscados en las plataformas de *PubMed*, *Medline Complete*, *Scopus* y *Web of Science*, para evaluar las características de las carillas *no-prep*, y examinar distintos estudios y casos clínicos, en donde habían sido utilizadas.

Resultados: debido a la falta de protocolo establecido, los autores seguían su propio criterio al realizar carillas *no-prep*, pero todos coincidieron en hacer un tallado menor a 0,5mm y la mayoría de ellos, en que los materiales ideales era cerámica feldespática e ionómero de vidrio.

Conclusiones: las carillas *no-prep* tienen múltiples ventajas como la ausencia o mínima pérdida de tejido, sin embargo, la selección de pacientes es complicada debido a las limitadas indicaciones que impiden el tratamiento en muchos casos. Además, el protocolo todavía no está estandarizado y necesita más estudios para pautar una técnica correcta. La cerámica feldespática y la reforzada con ionómero de litio son los materiales de elección.

ABSTRACT

Nowadays, the preservation of dental tissue is one of the biggest concerns in dentistry, therefore, conservative treatments are increasingly becoming more important. These treatments include *no-prep* porcelain veneers, which improve the aesthetics of the smile with non or little loss of tooth structure.

Objectives: to describe the concept of *no-prep* veneers, as well as its advantages and disadvantages; indications and contraindications; and ceramic manufacturing materials.

Methodology: An analysis of articles searched on the *PubMed*, *Medline Complete*, *Scopus* and *Web of Science* platforms was carried out to evaluate the characteristics of the *no-prep* veneers, and to examine different studies and case reports where they had been used.

Results: Due to the lack of an established protocol, the authors followed their own criteria when making *no-prep* veneers, but all agreed on making a cut of less than 0.5mm and most of them that the ideal materials were feldspathic and lithium ionomer-reinforced ceramics.

Conclusions: *no-prep* veneers have multiple advantages such as the absence of tissue loss, however, the selection of patients is complicated due to the limited indications that prevent the treatment of many cases. Furthermore, the protocol still is not standardized and needs more studies to establish a correct technique. Feldspathic and lithium ionomer-reinforced ceramics are choice materials.

ÍNDICE

1. Introducción.....	1
1.1. Histología	1
1.1.1. Esmalte	1
1.1.2. Dentina	2
1.2. Definición y clasificación de carillas	2
1.3. Origen de las carillas	8
1.4. Adhesión.....	10
1.4.1. Cemento	11
1.5. Materiales de carillas no-prep: cerámica.....	12
1.5.1. Cerámica a base de sílice / carillas feldespáticas	13
1.5.2. Cerámica a base de vidrio	14
1.5.3. Cerámica de zirconia / base de óxido.....	15
1.6. Ventajas de carillas no-prep	16
1.7. Desventajas de carillas no-prep.....	17
1.8. Indicaciones de carillas no-prep.....	18
1.9. Contraindicaciones de carillas no-prep	20
1.10. Supervivencia de carillas no-prep.....	21
1.11. Enfoque interdisciplinario	22
1.12. Técnicas para mejorar el diagnóstico-pronóstico de carillas no-prep	23
2. Objetivos	24
2.1. Objetivo general	24
2.2. Objetivos específicos.....	24
3. Metodología	25
3.1. Criterios de inclusión.....	25
3.2. Criterios de exclusión.....	26
4. Discusión y resultados.....	27
4.1. Adhesión de carillas no-prep.....	27
4.2. Carillas de porcelana vs carillas de composite.....	28
4.3. Tipo de cerámica - tallado - grosor de la cerámica en carillas no-prep.....	29
4.4. Ventajas y desventajas de carillas no-prep.....	34
4.5. Indicaciones y contraindicaciones de carillas no-prep	35
5. Conclusiones	37
5.1. Limitaciones del estudio.....	38
5.2. Futuras líneas de investigación.....	38
6. Responsabilidad	39
7. Bibliografía.....	40
8. Anexos.....	45

1. INTRODUCCIÓN

A la hora de relacionarnos, nuestro rostro juega un papel muy importante ya que algunos defectos físicos pueden provocar rechazo en la sociedad, por ello, la población demanda cada vez más estética. Esto influye también en la odontología ya que los pacientes acuden con el fin de mejorar la apariencia de la sonrisa en muchas ocasiones. Además, la concienciación de los pacientes acerca de la importancia de los dientes, promueve el uso de técnicas menos invasivas para la preservación de la mayor cantidad de estructura dentaria posible, el objetivo principal de la odontología moderna. Algunos de ellos pueden ser blanqueamientos, restauraciones de resina y carillas *no-prep* o lentes de contacto de porcelana. Esta última es una de las técnicas más demandadas, debido a su escasa eliminación de estructura dentaria sana, falta de dolor y buenos resultados estéticos, quedándose la técnica de tallado obsoleta¹⁻⁶.

1.1. HISTOLOGÍA

Entender las características generales del esmalte y la dentina es fundamental para entender la técnica adhesiva que conllevan las carillas⁷.

1.1.1. ESMALTE

Predomina el contenido de materia inorgánica (hidroxiapatita) y, por consiguiente, tiene alta energía superficial y naturaleza hidrofóbica. Cuando se trata con ácido, se crean microrretenciones que actúan como capilares y aumentan la superficie de contacto con el

adhesivo. Los factores influyentes son: el tipo de ácido (ácido ortofosfórico), su concentración (35-37%), el tiempo de aplicación (15 segundos) y la propia estructura del esmalte (mejor si el ácido ataca a la cabeza de los prismas)^{7,8}.

1.1.2. DENTINA

Predomina el contenido de materia orgánica (colágeno) y agua, lo que le proporciona baja energía superficial y naturaleza hidrofílica. Contiene túbulos dentinarios que actúan como capilares, pero contienen fluidos propios de la dentina que puede condicionar la capacidad de penetración del adhesivo. Hay que tener en cuenta sus propiedades físicas, la morfología, configuración de la dentina peritubular e intertubular, la influencia de la pulpa, el barrillo dentinario o *smear layer* (0,5-5 micrómetros de espesor) y las metaloproteinasas^{7,8}.

Por todo lo expuesto anteriormente, Barbero⁷ y Nocchi Conceição⁸ consideran que el esmalte es mejor sustrato que la dentina^{7,8}.

1.2. DEFINICIÓN Y CLASIFICACIÓN DE CARILLAS

La palabra inglesa «Veneer» significa literalmente “frente” o “recubrimiento”. Este término, se refiere generalmente a diversos tipos de restauraciones indirectas en forma de láminas, fabricadas a partir de una fina capa de material (habitualmente porcelana) de color similar al de los dientes y que los recubre parcialmente (en principio la cara vestibular) a través de una unión micromecánica para mejorar defectos^{1,9,10} y así mejorar la estética¹¹. Para el éxito del tratamiento, es necesaria una buena planificación (tipo de preparación, selección del material) y un buen mantenimiento y control a lo largo del tiempo¹².

Se pueden clasificar según:

PROFUNDIDAD DE LA PREPARACIÓN ⁸	EXTENSIÓN DEL LAMINADO ⁸	COLOR DEL DIENTE POR RESTAURAR ⁸	TIPO DE CERÁMICA EMPLEADA ⁸
Sin desgaste ⁸	Parcial ³	Sin alteración ⁸	Feldespática ⁸
Desgaste en esmalte ⁸	Total ⁸	Moderada alteración ⁸	Vidrio ceramizado ⁸
Desgaste en esmalte y dentina ⁸	Total, con recubrimiento incisal ⁸	Acentuada alteración ⁸	Alto contenido de alúmina ⁸

Tabla 1 Elaboración propia a partir de los autores Nocchi Conceição y Mozayek^{3,8}

Dentro de sus características, se distinguen varios puntos:

- a) **Durabilidad:** Según la literatura, entre las restauraciones más duraderas se encuentran las carillas, cuando se realizan por odontólogos profesionales, sin embargo, cuando se trata de estudiantes u odontólogos generales, la supervivencia es menor, esto se debe a que gran parte del resultado depende de la capacidad y experiencia clínica del odontólogo a causa de: la dificultad de un resultado armónico; el riesgo de fractura durante la manipulación; y a la dificultad del proceso de adhesión por la contracción de los cementos durante la polimerización. Los tipos de fracasos pueden ser: grietas, desprendimiento, tinciones y filtraciones (cuando existe composite)¹⁰ y puede estar relacionado con determinantes como cambios en la fuerza oclusal o en las condiciones de adhesión (Obradovic-Djuricic et ál., 2014)¹.

- b) **Estética:** son las restauraciones que más se asemejan a los dientes debido a la luminosidad y la translucidez que otorga la porcelana. Además, la zona de intersección entre el material y el diente queda oculta en la zona interproximal, y en el caso de que

la posición sea inadecuada, donde la zona de transición sea visible, se puede equilibrar con las propiedades ópticas del adhesivo. Una de las mayores ventajas de las carillas en comparación con las coronas, es que no producen un oscurecimiento a nivel cervical debido a la ausencia de metal^{10,13,14}.

- c) **Preservación de estructura dentaria:** se pueden fabricar carillas con grosores mayores o menores dependiendo de cada situación: en caso de dientes pequeños o lingualizados, se podrá prescindir de una preparación; en el caso contrario, habrá que tallar hasta conseguir el espacio mínimo, pudiendo llegar hasta la dentina¹⁰.

Debido a que la clasificación para las carillas sin preparación o mínimamente invasivas no estaba clara, Brian LeSage¹⁵, propone una clasificación (2013) sobre los distintos parámetros que deben cumplir cada tipo de preparación de carillas, y de esta manera obtener una mejor comunicación entre profesionales y hacia los pacientes¹⁵:

- Clase I, no-prep / prácticamente prep-less / carillas de adición: en esta clasificación, el esmalte remanente es del 95-100%, no hay exposición de dentina y puede haber una pequeña línea de terminación, a veces indetectable sin algún tipo de microscopio o lupas de aumento, para ayudar a los técnicos de laboratorio a crear la restauración. La profundidad de la preparación no puede exceder los 0,5mm en la cara incisal y vestibular del diente (Fig. 1)¹⁵.

Fig. 1 Preparación de un incisivo lateral izquierdo para carilla clase I.

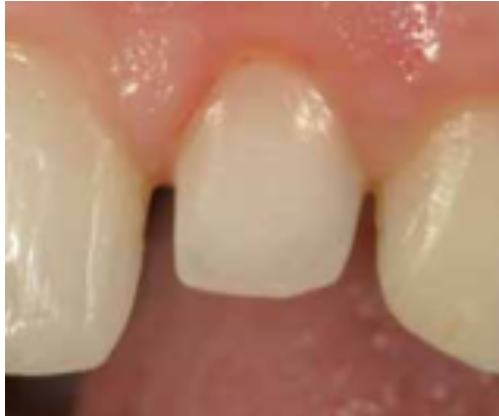

Fig. 1 Fuente: Brian LeSage¹⁵.

- Clase II, mínimamente invasiva / *prep-less modificada*: en este caso, la remoción de esmalte será aún mayor, más de 0,5mm de profundidad, quedando remanente 80-95% de esmalte y con exposición de dentina del 10-20% (Fig. 2 y 3)¹⁵.

Fig. 2 Preparación mínimamente invasiva, clase II. Fig. 3 Dentina expuesta de preparación clase II.

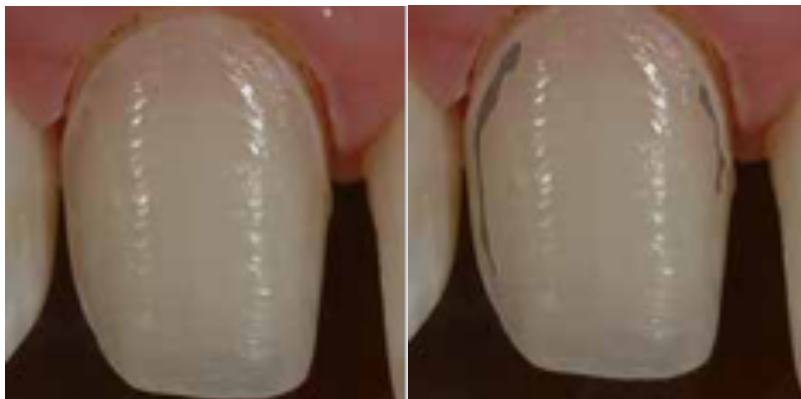

Fig. 2-3 Fuente: Brian LeSage¹⁵.

- Clase III, preparación conservadora: preparación de 0,5-1mm de profundidad, con un 60-80% de esmalte remanente, y con exposición del 20-40% de la dentina (Fig. 4 y 5)¹⁵.

Fig. 4 Preparación conservadora clase III. Fig. 5 Dentina expuesta de la preparación clase III.

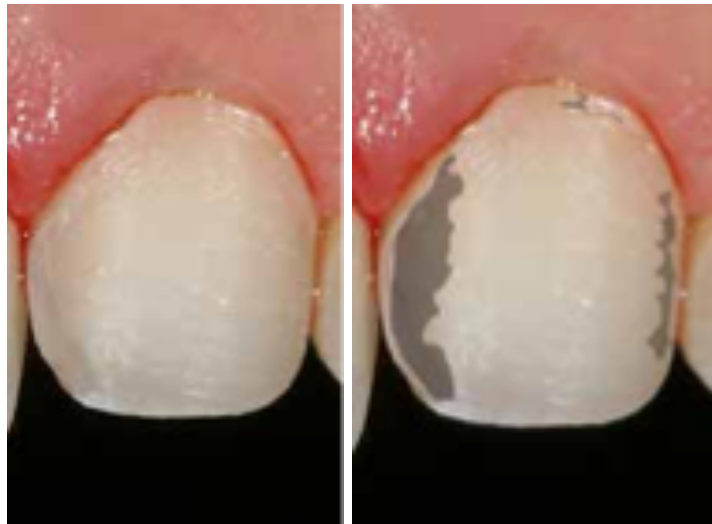

Fig. 4-5 Fuente: Brian LeSage¹⁵.

- Clase IV, carilla completa / preparación de carilla de porcelana convencional: conserva aproximadamente 50% del esmalte, una pérdida de 1mm o más de tejido y con 40% de dentina visible. Es la clase más aceptada debido a sus bajas limitaciones y a su buen pronóstico (Fig. 6)¹⁵.

Fig. 6 Preparación para carillas clase IV.

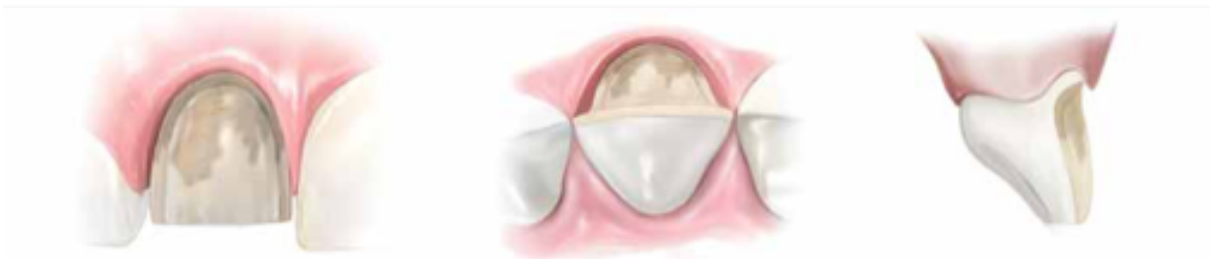

Fig. 6 Fuente: Brian LeSage¹⁵.

- En caso de que la preparación supere los parámetros de la clase IV (menos del 50% de esmalte remanente y más del 40% de dentina expuesta), la siguiente opción de restauración, sería recubrimiento total con una corona. Siempre que se pueda, optar por realizar carillas, ya que son más conservadoras y se elimina un cuarto, o la mitad de tejido que para una corona (Fig. 7 y 8)^{10,12,15}.

Fig. 7 Preparación con menos del 50% de esmalte remanente. Fig. 8 Exposición de dentina de más del 40%.

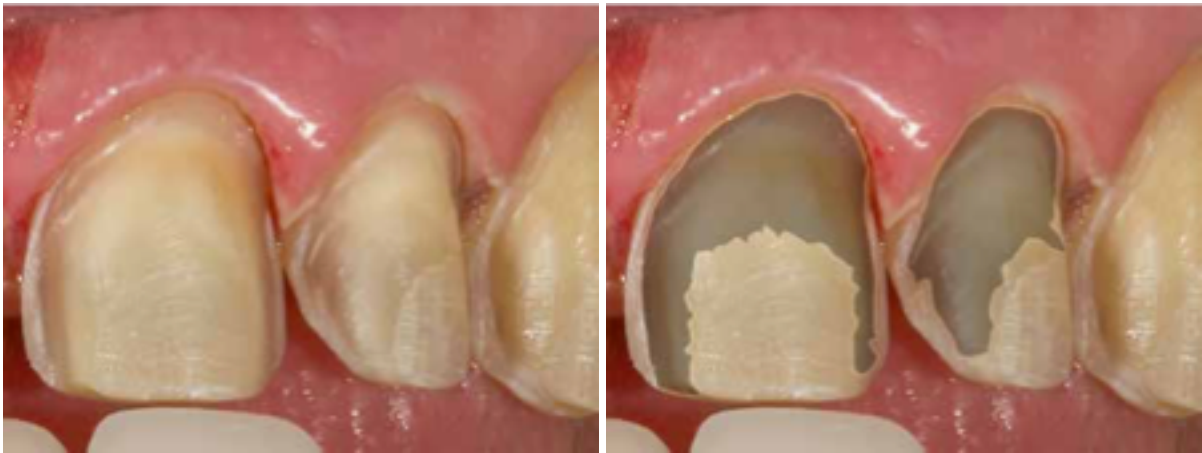

Fig. 7-8 Fuente: Brian LeSage¹⁵.

Hacer o no preparación es un factor importante para el pronóstico¹².

1.3. ORIGEN DE LAS CARILLAS

Esta técnica de restauración, a pesar de que no era completamente funcional al principio, comenzó hace aproximadamente un siglo:

En los años 20, el Dr. Charles Pincus, dentista de Beverly Hills, presentó el *Hollywood Veneer*, una carilla que se pegaba a los dientes para hacerlos lucir mejor para las películas y sesiones fotográficas de actores famosos, como Elizabeth Taylor, Barbara Stanwyck, Walt Disney, y muchos otros. Pero eran funcionalmente ineficaces ya que su unión era temporal, su único medio de adhesión era pegamento para prótesis, y no se podían usar para comer ^{9,10,16-19}.

Tres décadas después, en 1955 Buonocore, introdujo la técnica de grabación del esmalte con ácido ortofosfórico al 85%, el cual marcó un antes y un después en la técnica adhesiva ya que aumentaba la superficie de contacto del esmalte para así aumentar la retención ^{8,9,16,18}.

Posteriormente, en 1979 apareció el primer producto comercial. Se trataba de carillas acrílicas preformadas que se adherían mediante resina compuesta al diente de manera permanente. Pero se vio que pasado el tiempo tenían una unión ineficaz y no simulaban la apariencia (cambios de color), ni la funcionalidad del diente (fracturas y desgastes)^{4,16,20,21}. Por el contrario, la porcelana había tenido un historial en la odontología impecable debido a sus características (Radz)¹⁶:

- Estabilidad fisicoquímica²⁰.
- Excelente compatibilidad biológica (Coachman *et ál.*, 2014)^{1,12,16,18,20,22,23}.
- Suficiente resistencia a la compresión y abrasión^{18,20,23}.

- Gran estética, por su excelente reproducción de las propiedades ópticas de la estructura dental^{3,4,12,18,20,23}.
- Estabilidad del color^{3,4,13,16,18,20,23}.

Todo esto, llevó a hacer estudios acerca de un mecanismo de unión entre el diente y la cerámica, hasta que finalmente se concluyó que grabando la porcelana con ácido fluorhídrico (Simonsen y Calamia, en la década de los 80), seguido de una silanización, grabando el diente con ácido ortofosfórico (Buonocore), y añadiendo en medio una resina compuesta, podrían proporcionar una adhesión favorable a largo plazo^{8,10,18,20,24}.

Desde la introducción de las carillas en 1983, debido a la evolución de los cementos adhesivos, se han considerado una de las modalidades terapéuticas más factibles, ya que aparece un nuevo concepto de odontología mínimamente invasiva, dejando cada vez más de lado el tratamiento de cobertura total (coronas), y es a partir de aquí cuando comienza su verdadero avance. Sin embargo, al principio seguían sin ser muy utilizadas, debido al miedo que existía al poner restauraciones tan finas que iban a estar sometidos a fuerzas oclusales^{8,9,15,16,18,19,21,25}.

Respecto a las técnicas de preparación del diente, en un principio se utilizó la técnica *no-prep* (sin preparación) con porcelana feldespática, pero hacía lucir al diente muy voluminoso y producía irritación de los tejidos blandos, por lo que se decidió tallar de una manera mínima los dientes (0,5mm), dejando suficiente espacio para las carillas y así obtener un buen aspecto y biocompatibilidad¹⁶. Esta pérdida de tejido podía dejar expuesta la dentina, lo que preocupaba al paciente y al odontólogo. El problema fue doble: mucha pérdida de tejido sano y la ineficaz adhesión a dentina^{11,16}.

1.4. ADHESIÓN

El objetivo básico de cualquier restauración adhesiva es hacer que el material de restauración sea firme y duradero, para adaptarse al esmalte dental y a la dentina. El principal desafío de los adhesivos dentales es cómo ser eficaz en estos dos sustratos al mismo tiempo. Para lograr este objetivo, se deben superar algunos obstáculos. La unión a esmalte se puede lograr de manera estable a través de las microporosidades en el esmalte grabado con ácido y de la formación de *tags* de resina, mientras que la unión efectiva a la dentina es la tarea más conflictiva de los adhesivos²⁶.

Actualmente, los avances en la odontología promueven ser más conservadores y a la vez satisfacer los deseos estéticos del paciente y proporcionar gran longevidad, por ello, se intenta volver a sus orígenes: mínima / nula preparación de esmalte. La técnica *no-prep* tiene gran demanda por la población, pero todavía sigue en debate si es mejor que la mínimamente invasiva^{11,16,21}.

La evolución de la cementación adhesiva durante los últimos 50 años, ha aumentado las posibilidades terapéuticas con materiales libres de metal, entre ellas, se encuentra esta técnica *no-prep*^{6,11,13,16,20}. La adhesión consiste en: una carilla de porcelana grabada en la parte interna (ácido fluorhídrico 4-10%); el diente con el esmalte grabado (ácido ortofosfórico 37%); silanización que acondiciona la carilla y la unión de resina-porcelana; y el cemento de resina que servirá de unión entre el diente y la carilla^{3,9,23,24,27}.

1.4.1. CEMENTO

Material cuya función es unir la carilla al diente y llenar la interfase que se encuentra entre ellos. Los cementos de resina tienen resistencia a la fractura y buena retención, pero la tecnología de consolidación del cemento es muy sensible, y la incidencia de sensibilidad postoperatoria es alta²¹. Deben incluir las siguientes características:

- Capacidad para proporcionar una unión estable entre el material de restauración y el esmalte (la superficie del diente)²¹.
- Resistencia a la tracción y a la compresión²¹.
- Módulo de elasticidad similar al del diente-porcelana²¹.
- Viscosidad para asegurar que el grosor de la línea de cementación sea suficiente y la restauración esté completamente fijada²¹.
- Biocompatibilidad^{21,22}.

Los cementos de resina pueden clasificarse según su forma de polimerización: fotopolimerización o polimerización dual. Siempre que se pueda, se usará la fotopolimerización ya que proporciona más tiempo de trabajo y gran estabilidad del color, en la medida que la carilla sea suficientemente delgada y translúcida para dejar pasar la luz a través de ella. En caso contrario (mayor de 0,7 mm), habría que usar polimerización dual, pero estos presentan peor estabilidad de color, ya que contienen amina terciaria que produce cambios de coloración pasado el tiempo. Las propiedades de los cementos van a depender del grado de conversión, por lo que una polimerización inadecuada puede producir el fracaso de la restauración, y reduce las propiedades mecánicas, por ello es necesario seguir minuciosamente el protocolo de cementado^{12,18,21,28}.

El cemento no va a proporcionar una predicción del pronóstico, pero debe tener el mínimo grosor y ser lo más uniforme posible¹².

1.5. MATERIALES DE CARILLAS NO-PREP: CERÁMICA

La evolución de las cerámicas ha permitido el uso de la técnica sin tallado, debido a la minimización de su grosor⁶.

Múltiples cerámicas han aparecido en el mercado, pero según la literatura, las más destacables para la confección de carillas *no-prep* y las más utilizadas son: feldespática (muy estéticas, pero complicadas de confeccionar) y prensada (menos estéticas, pero resistentes y fáciles de confeccionar)^{1,11,16,20,21}.

Estas cerámicas pueden variar según su microestructura, desde muy translúcidas (estructura vítrea) hasta muy opacas (estructura cristalina)²¹, de esto dependerá que las carillas se distingan, o no, de un diente natural (a más translucidez, más naturalidad)¹⁴. También influyen los siguientes factores:

- El tamaño de partícula²¹.
- La densidad de partícula²¹.
- El índice de refracción²¹.
- La porosidad²¹.

1.5.1. CERÁMICA A BASE DE SÍLICE / CARILLAS FELDESPÁTICAS

Se crean mezclando polvos (dióxido silicio) y materiales líquidos, el valor estético que tengan estos, depende de la habilidad del ceramista^{1,21}.

El dióxido de silicio / sílice / cuarzo, contiene diferentes cantidades de alúmina. Cuando contienen potasio y sodio, se denomina feldespato. Los feldespatos se componen principalmente de óxido de silicio (60%-64%) y óxido de aluminio (20% -23%), normalmente, se modifican de diferentes formas para crear la porcelana utilizada en odontología^{1,21}.

La carilla de porcelana feldespática consta de cristales de fluorapatita que le proporciona propiedades estéticas (alta translucidez). El problema de este material está en las propiedades mecánicas bajas (60 a 70 MPa), por ello, al hablar de carillas, es necesario una estructura dental rígida (esmalte) y una correcta adhesión para reforzar la restauración^{1,3,21}.

Las fracturas, el desprendimiento y las microfiltraciones son las causas principales del fallo de este tipo de carillas (Lovadino, Sano, Terada, & Pascotto, 2012)^{1,10}.

Es posible tener un espesor inferior a 0,5mm con esta cerámica, pero en ocasiones, es aconsejable una reducción del tejido del esmalte de 0,5 para una correcta salud del tejido gingival. La condición ideal del diente a tratar según el autor Pini y colaboradores, es tener una proporción mínima del 50% del esmalte unido al sustrato, y del 70% o más de esmalte cuando está en el margen, por lo que estas restauraciones están indicadas en dientes anteriores con una gran cantidad de esmalte, ya que tiene menos riesgo de flexión que en la dentina²¹.

Hoy en día la porcelana más utilizada y estudiada a la hora de hablar de carillas, es la feldespática Cerinate (Lumineers), ya que aporta gran resistencia y menor espesor (0,2mm) sin la necesidad de remover tejido dental sano⁹.

1.5.2. CERÁMICA A BASE DE VIDRIO

Se compone de cuarzo, dióxido de litio, óxido de fosforo, alúmina, óxido de potasio, entre otros. Este tipo de cerámicas presentan buenas propiedades mecánicas y físicas, por lo que pueden actuar como núcleo o monolítica ^{1,21}.

La mejora de sus propiedades se consigue gracias a la interacción de los cristales con la matriz vítrea, y a el tamaño y número de los cristales. Los cristales más pequeños suelen generar materiales más resistentes y pueden ser translúcidos u opacos según la composición química y el porcentaje de cristalinidad. El aumento de resistencia se logra mediante adición de rellenos, en este caso, para carillas estéticas estarían indicadas la leucita y el disilicato de litio (tamaño micrométrico), por sus propiedades ópticas y porque son sensibles a los ácidos. Se fabrican mediante una combinación de técnicas de cera perdida y prensado con calor, y son menos porosas que las feldespáticas^{1,21}.

- Cerámica reforzada con leucita (mineral cristalino en un 50-55%): tiene la ventaja de que el índice de refracción es cercano al de las porcelanas feldespáticas (translucidez), y de que se graba mucho más rápido que las que tienen vidrio de base, lo que permite una buena unión micromecánica al cemento de resina y por consiguiente al diente^{21,23}.
- Cerámicas reforzadas con disilicato de litio: cerámicas a base de vidrio con un aumento del contenido cristalino al 70% con un tamaño reducido que mejora la resistencia a la

flexión. Es lo suficientemente translúcido como para usarlo en restauraciones monolíticas o como núcleo para posterior recubrimiento^{21,23}.

El espesor de este material debe ser superior a 0,8mm y puede ser más estrecho en zonas marginales (0,3mm). En casos donde haya suficiente espacio se usará esta opción, debido a su mayor resistencia y tenacidad. Estos materiales son eficientes para adherirse al sustrato, incluso si queda menos del 50% del esmalte restante; sin embargo, en el margen debe estar presente al menos el 30% del esmalte²¹. Indicadas cuando haya más riesgo de flexión²¹, como en los siguientes casos:

- Menos esmalte²¹.
- Porcelana sin soporte²¹.
- Sobremordidas profundas o superposiciones de dientes²¹.
- Cuando se adhiere a sustratos más flexibles, como dentina y composite²¹.
- Cuando hay bruxismo²¹.
- Cuando las restauraciones se colocan más distalmente²¹.

1.5.3. CERÁMICA DE ZIRCONIA / BASE DE ÓXIDO

La cerámica de zirconia o en base de óxido, utilizadas en carillas *no-prep*, contienen un núcleo opaco de alta resistencia, al que se le confiere estética aplicando una capa de porcelana de feldespato para una apariencia más natural¹. Ha ido evolucionando a lo largo de los años, pudiendo llegar a aportar translucidez sin llegar a perder mucha resistencia a la fractura, obteniendo un material estético y mecánicamente funcional. Sin embargo la imposibilidad de grabar este material complica la adhesión al diente²⁷.

1.6. VENTAJAS DE CARILLAS NO-PREP

Las carillas de porcelana laminadas han supuesto un gran avance en la odontología ya que nos permiten mejorar / recuperar la estética y función de los dientes anteriores de una manera prácticamente no invasiva^{13,16}:

- Mayor aceptación por parte del paciente^{5,9}.
- Preservación del tejido dental^{1,5,6,9}.
- Únicamente necesidad dos citas (a menos que se tenga CAD-CAM en la clínica)^{1,9,10,13}.
- Mayor facilidad en la toma de impresiones^{4,5}.
- No se requiere anestesia⁹.
- No se necesita provisional^{1,4-6,9}.
- Tratamiento reversible (aunque los autores refieren gran dificultad al retirar la porcelana y el cemento sin eliminación de esmalte)^{5,6}.
- Tratamiento predecible ya que se adhiere al esmalte^{1,9}.
- Dientes manchados o con mala coloración resistente a procedimientos vitales de blanqueamiento^{1,5,6,9,16,21,25,27}.
- Desensibilización de la pieza ya que refuerza el esmalte (sin sensibilidad pos-operatoria)^{1,4-6,9}.
- Reforzar dientes con fracturados con fracturas menores / astillamientos o agrietados^{1,5,6,9,13,21}.
- Restauración de la dimensión vertical, guías caninas y anteriores^{1,23,29}.
- Mejorar forma/contorno y tamaño/volumen (formas anormales)^{1,5,6,12,16,21,25,27}.
- Corregir leves desalineamientos^{1,6,12,25,27}.
- Mejorar el aspecto de los moteados¹.

- Cierre de diastemas^{1,5,6,12,21,23,25}.
- Fluorosis con moteado de esmalte²¹.
- Malformaciones localizadas del esmalte²¹.

1.7. DESVENTAJAS DE CARILLAS NO-PREP

Estas carillas tienen ciertos inconvenientes, limitaciones mecánicas e indicaciones específicas, ya que pueden ocasionar daños como irritación en la encía, en caso de que la carilla no esté bien diseñada (la cual se podría corregir modificando la carilla, o tallando un poco el diente a nivel cervical, pudiendo evitar cirugías como gingivectomías)^{11,14}. Se debe realizar un buen plan de tratamiento y tener un buen criterio clínico de acuerdo con las necesidades del paciente, la oclusión y la fuerza de mordida⁴. Las indicaciones dependen de factores relacionados con el propio diente y con su posición en la arcada y en algunos casos será necesario hacer pretratamientos para llegar al éxito⁵. Las desventajas pueden incluir:

- La selección de cada caso es complicada⁵.
- Necesidad de tratamientos multidisciplinarios⁵.
- Necesidad de un técnico experimentado debido a la dificultad de confección⁵.
- Dificultad en la cementación, y en la adaptación para una perfecta transición entre el diente y la carilla^{5,12}.
- Riesgo de fractura/fisura durante la confección y el cementado⁵.
- Complicaciones periodontales, sobrecontorneado (aunque una buena valoración y fabricación, no debería ocasionar problemas)⁵.
- Falta evidencia científica a largo plazo⁵.

- Capacidad limitada de alteración del tono¹⁵.
- Dificultad para desarrollar la inclinación axial correcta¹⁵.
- Errores proporcionales¹⁵.
- Problemas para formar la simetría gingival adecuada¹⁵.
- Tratamiento costoso³⁰.

1.8. INDICACIONES DE CARILLAS NO-PREP

Las indicaciones dependerán tanto del propio diente como de su posición en la arcada, la severidad y la extensión son factores a tener en cuenta y en algunos casos necesitarán tratamientos previos (enfoque multidisciplinario)^{5,12}. La clasificación de indicaciones de carillas según Magne y Belser (2002) es la siguiente¹⁶:

Tipo I: Dientes resistentes al blanqueamiento¹⁶.

- Tipo IA: decoloración por tetraciclina¹⁶.
- Tipo IB: dientes que no responden al blanqueamiento¹⁶.

Tipo II: modificaciones morfológicas importantes¹⁶.

- Tipo IIA: dientes conoides (*peg-laterals* o laterales de clavija: dientes pequeños, cortos)^{5,15,16}.
- Tipo IIB: Diastemas o triángulos interdentes para cerrar^{5,6,16}.
- Tipo IIC: aumento de la longitud incisal o prominencia facial (contorno) en dientes con linguoversión^{5,6,10,16}.

Tipo III: Restauraciones extensas¹⁶.

- Tipo IIIA: fractura coronal extensa¹⁶.

- Tipo IIIB: pérdida extensa de esmalte por erosión y desgaste¹⁶.
- Tipo IIIC: malformaciones congénitas generalizadas¹⁶.

(Radz, 2011, p.355).

Acorde a esta clasificación, las carillas de porcelana de preparación mínima y sin preparación pueden lograr el efecto estético deseado de manera poco invasiva para los Tipos I y II, sin embargo para los Tipo III que son de naturaleza más extensa, hay que ser menos conservadores¹⁶.

Según Barrigón⁵, las indicaciones están determinadas por: ausencia de exposición de dentina; color del sustrato correcto, con posibilidad de blanqueamiento previo; anatomía del diente expulsiva, perfil de emergencia suave y ausencia de ángulos agudos; torque correcto; y una alineación correcta⁵.

Una variante de las carillas *no-prep*, serían las carillas parciales, cuya indicación más habitual es el cierre de diastemas, siempre y cuando las láminas no tengan ningún contacto oclusal, ya que las fuerzas oblicuas podrían llevar a fallo de la restauración (fractura / desprendimiento)³. Sin embargo, se deben realizar más estudios clínicos y se deben verificar la evidencia clínica y el éxito a largo plazo⁴.

1.9. CONTRAINDICACIONES DE CARILLAS NO-PREP

Según la bibliografía revisada, se han descrito variedad de contraindicaciones:

- Dientes expuestos a fuertes fuerzas oclusales como bruxismo severo o actividad parafuncional^{1,16,21}.
- Dientes con decoloraciones muy notables y difíciles de enmascarar⁶.
- Dientes muy mal posicionados: superposición vertical profunda anteriormente, sin superposición horizontal, mordida cruzada, borde a borde, dientes vestibulizados, que necesitan excesiva reducción^{1,6,16,21}.
- Presencia de enfermedad de tejidos blandos^{16,21}.
- Grandes fracturas dentales⁶.
- Dientes en los que la modificación del color se puede lograr con éxito con varias técnicas de blanqueamiento¹⁶.
- Dientes con extensas restauraciones existentes^{6,16,21}.
- Distancia interoclusal reducida²¹.
- Severa desmineralización de la dentina y severa fluorosis^{1,16}.
- Daño pulpar no tratado¹.
- Pobre higiene oral e irritación periodontal¹.

Según un informe de caso de Zavanelli¹⁸, pacientes bruxistas, podrían recibir microcarillas de porcelana (disilicato de litio) estudiando previa y detenidamente el caso (DSD, radiografías, fotografías, colaboración con otros profesionales, modelos de escayola, *mock-up*) y finalizando el tratamiento con una férula de descarga¹⁸.

1.10. SUPERVIVENCIA DE CARILLAS NO-PREP

Los informes de casos y muchos resultados clínicos sugieren que con estas restauraciones (mínimamente invasivas o sobre las carillas sin preparación) se pueden lograr tasas de éxito tan elevadas como con las carillas vestibulares clásicas cuando se aplican correctamente¹⁰.

Respecto a tasas de supervivencia: es del 91,2% dos años después (Öztürk), 96-99% cinco años después (Della Bona y Kelly / Nejatidanesh), del 97,6% 7 años después (Arif) y del 97% 15 años después^{9,21,25}, en otras palabras, las tasas de éxito reportadas entre el 75% y 100%¹ son aproximadamente de 3 a 5 años (Etman & Woolford, 2010) (Fondriest & Roberts, 2010) y hasta de 10 años (Salazar-López & Quintana-del Solar, 2016), con una baja prevalencia de desprendimiento, microfiltraciones, fracturas y caries^{6,31}. El éxito clínico se debe a:

- Planificación del caso, con la indicación correcta²¹.
- Preparación poco invasiva de los dientes²¹.
- Correcta selección de la cerámica²¹.
- Selección adecuada de los materiales²¹.
- Seguimiento meticuloso del protocolo de cementación²¹.
- Planificación para el mantenimiento continuo de las restauraciones²¹.

Todavía la relación respecto a la falta o no de tallado con el tipo de fracaso de la restauración sigue siendo un tema en debate⁶, pero a nivel general, las carillas de porcelana sin preparación adheridos 100% a esmalte tiene resultado muy buenos, igualando o incluso a veces superando los resultado de las que si tienen preparación³². Se puede prever un buen pronóstico cuando se posicionan los márgenes de la restauración dentro del esmalte⁶.

Tiene una baja tasa de fracaso de 0-7% y en otros ensayos clínicos aumenta al 14-33% probablemente debidos a otros factores (oclusión y articulación desfavorables, pérdida excesiva de estructura dental, cemento inadecuado y adhesión a dentina). Las causas mecánicas y biológicas de estos fracasos se relacionaron con la estética (31%), como pigmentación de los márgenes; implicaciones mecánicas (31%); soporte periodontal (12,5%), como sangrado en la prueba; pérdida de retención (12,5%); caries (6%); fractura de dientes (6%); e hipersensibilidad^{6,21}.

1.11. ENFOQUE INTERDISCIPLINARIO

Para obtener el éxito en una rehabilitación total (función y estética) de un paciente, es necesario adoptar un enfoque integral y en ciertas situaciones se debe hacer un plan de tratamiento interdisciplinar. El desarrollo de trabajo multidisciplinario está permitiendo el uso de carillas *no-prep* y *prep-less*⁵, donde se realizaría un análisis exhaustivo del diagnóstico y de las condiciones previas del paciente, en precedente a la selección de un plan de tratamiento. Antes de empezar el tratamiento restaurador, la salud oral debe ser próximo a la perfección, por ello hay que combinar estas restauraciones protéticas con: ortodoncia, en caso de que los dientes necesiten una mejor posición axial para hacer que la preparación sea menos invasiva; periodoncia (profilaxis, gingivectomías, alargamientos coronarios) para que haya un buen equilibrio entre la restauración y los tejidos gingivales; y en ocasiones, blanqueamientos, cirugía de injerto de tejido blando, retratamiento endodóntico, reemplazo del poste de metal fundido por un poste de fibra de vidrio, etc. El enfoque multidisciplinario puede ser fundamental para un buen pronóstico de las carillas^{1,18,22,23,33}.

1.12. TÉCNICAS PARA MEJORAR EL DIAGNÓSTICO-PRONÓSTICO DE CARILLAS NO-PREP

- Se recomienda hacer un *mock-up* para saber la posición, color y forma correcta, y permitir una planificación precisa del tallado^{5,18}.
- Es importante la comunicación entre el clínico y el técnico de laboratorio para obtener un buen resultado¹³. Se aconseja que sea el mismo técnico de laboratorio el que realice el encerado tras un *mock-up* y el que realice las carillas *no-prep*⁵.
- El *Digital Smile Desing* (DSD) puede ser un buen aliado para que los pacientes vean la diferencia en el antes y el después de las restauraciones, y aprueben el tratamiento con una expectativa más tangible. Además, puede ser un buen recurso para la comunicación entre profesionales y así mejorar el plan de tratamiento^{5,18,34}.
- El *set-up* puede ser de utilidad al integrar un plan de tratamiento ortodóncico y restaurador, donde ambos profesionales participan activamente en la planificación para que el movimiento dentario se ajuste perfectamente a las necesidades del restaurado (distribución de diastemas, resalte, sobremordida...)⁵.

Sin embargo, estas técnicas conciernen a otras líneas de investigación que no se corresponde con el concepto de carillas *no-prep*.

2. OBJETIVOS

2.1. OBJETIVO GENERAL

- Describir las características que componen el concepto de carilla *no-prep*.

2.2. OBJETIVOS ESPECÍFICOS

- Identificar los materiales de fabricación de carillas *no-prep*.
- Analizar las ventajas y desventajas que aportan las carillas *no-prep*.
- Determinar las indicaciones y contraindicaciones de las carillas *no-prep*.

3. METODOLOGÍA

Se realizó una revisión sistemática de documentos de sociedades científicas dedicadas a las carillas *no-prep*.

Esta investigación es un estudio comparativo y analítico, en el cual para llegar a los objetivos establecidos se realizó una revisión de 36 artículos, todos ellos obtenidos en la base de datos de la biblioteca CRAI Dulce Chacón (*PubMed, Medline Complete, Scopus, Web of Science ...*) a través de palabras clave como “carillas mínimamente invasivas”, “carillas *no-prep*”, “carillas *prep-less*”, “*microveneer*”, “microcarillas”, “carillas sin preparación”, “laminados cerámicos”, “*contact lens*”, “lentes de contacto”... cerciorándose de la relevancia de cada uno y así medir su calidad. Además, se utilizaron libros referentes a estética, carillas de porcelana, prótesis y restauradora.

3.1. CRITERIOS DE INCLUSIÓN

- La búsqueda bibliográfica abarcó artículos de 1995-2021.
- Idioma inglés y en español.
- Podían ser ensayos clínicos, ensayos *in vitro*, informes de casos, revisiones sistemáticas o estudios prospectivos.
- Los artículos se limitaron a carillas *no-prep* de porcelana, los de carillas de composite no se descartaron si en algún apartado se comparaban con las de porcelana.
- Artículos referentes a la adhesión a esmalte y dentina.

3.2. CRITERIOS DE EXCLUSIÓN

- Artículos de resinas compuestas, sin ningún tipo de relación con carillas de porcelana.
- Artículos sobre carillas con preparación que no fueran mínimamente invasivas.
- Artículos que no tuvieran relación con el tema principal.

En el tema tratado los estudios con muestras son muy escasos debido al alto coste que conlleva el tratamiento y a las limitadas indicaciones. Sin embargo, se presentan suficientes informes de casos que en general concluyen lo mismo, llegando a aportar cierta validez científica.

En muchos de los artículos se concluye que se necesitan estudios longitudinales para ver la durabilidad y supervivencia de las carillas *no-prep*.

4. DISCUSIÓN Y RESULTADOS

4.1. ADHESIÓN DE CARILLAS NO-PREP

Es mejor la unión a esmalte que la unión a dentina, ya que la porcelana tiene un índice de flexión parecido al del esmalte, todo lo contrario a la dentina, cuyo índice de flexión es mayor, lo que podría producir con más facilidad fracturas de la carilla. Además, la unión amelodentinaria no se podría sustituir por el adhesivo ya que nunca llegaría a ser tan fuerte¹⁰.

Burke²⁵ establece que el mantenimiento de la carilla sobre el diente es por adhesión y no por retención, debido a esto, el sustrato debe ser siempre esmalte, por lo que en caso de haber preparación dental para una carilla, debería ser mínima (0,3-0,5mm) para no llegar a exponer la dentina²⁵. Contrastando esto, Cançado¹² y Stappert³¹ reportan que se produce una adhesión más fuerte cuando hay una preparación dental que cuando no la hay, y que por ello, se recomienda para una mayor longevidad^{12,31}.

Las carillas unidas a un sustrato diferente a esmalte, como dentina o sobre restauraciones de composite, tienen mayor riesgo de fracaso^{10,30}, mientras que se produce una adhesión exitosa cuando está 100% sobre esmalte³² llegando al 99% de supervivencia, y del 94% en caso de que hubiera esmalte únicamente en los márgenes⁶.

Molina³⁵, defiende que si se realiza una preparación mínimamente invasiva en esmalte y una correcta adhesión, se considera que el diente está completamente restaurado y que es mecánicamente tan estable como para proteger y garantizar su supervivencia³⁵.

4.2. CARILLAS DE PORCELANA VS CARILLAS DE COMPOSITE

Según Frankenberger¹⁰, las carillas de cerámica no siempre son la mejor opción y depende del profesional tomar la decisión de utilizarlas o no¹⁰.

Respecto al dilema de si usar composite o porcelana, Batalocco demuestra que funcionan igual en un estudio que realizó sobre incisivos fracturados, concluyendo que no hay cambios estadísticamente significativos a nivel clínico y que el único matiz a reseñar era el cambio de color que presentaban las carillas de composite a lo largo del tiempo, por lo que requerían mantenimiento^{13,22}. Otros reportes de caso, reafirmaron el testamento de Batalocco⁴. Pero a pesar de que la satisfacción de los pacientes sea elevada (Alhekier et al: 82.8%), también estudios han reportado que el cambio de color de las carillas de porcelana ha sido el principal motivo de queja²⁵.

La mayor ventaja que tiene el composite sobre la porcelana, es la facilidad de reparación en caso de fractura, informa Vadini¹³. Pero sigue teniendo muchos inconvenientes; como la baja resistencia al desgaste y durabilidad, decoloración, manchas superficiales y contracción por polimerización³.

González García²⁸ afirma que el composite iguala o supera la cerámica, mientras que Hajtó¹⁰ defiende que el éxito de las carillas de porcelana supera al composite según los estudios^{10,30}. Sin embargo, este último también considera que cuando el defecto es mínimo y pueda ser reparado con composite, no están indicadas las carillas¹⁰. Así lo explica Yanikian³⁰, quien sugiere que, si la única queja del paciente es la descoloración del diente, el composite está más indicado a pesar de que la porcelana sea mejor a largo plazo³⁰.

En los casos donde estén indicadas las carillas *no-prep*, la porcelana es el material de elección debido a su biocompatibilidad, longevidad, función, estética, salud periodontal, su estabilidad de color y por su resistencia a la fractura^{3,4,10,12,18,22,23}.

4.3. TIPO DE CERÁMICA - TALLADO - GROSOR DE LA CERÁMICA EN CARILLAS NO-PREP

Una vez se ha determinado el sustrato y el material, es necesario saber el grosor que va a tener la cerámica para proporcionar el espacio necesario. El material utilizado va a determinar cuanta preparación se necesitará (invasiva o no), pero en la práctica clínica, según Cosenza²², siempre se necesitará una remoción mínima de tejido²².

Cançado¹², expone un informe de caso seguido y evaluado durante 8 años. Comienza con un tratamiento de carillas *no-prep* feldespáticas que, tras 6 años, aparecen con tinciones en las interfaces, por lo que se decide realizar un tratamiento con preparación de 0,5 en el tercio incisal y de 0,3 en el tercio medio para carillas de disilicato de litio, por sus mejores propiedades

mecánicas y su estabilidad a largo plazo (tras dos años, no se apreció ningún cambio). A pesar del fallo de la carilla *no-prep*, este tratamiento conservador es recomendable cuando está indicado, velando por la cantidad de estructura de diente, pero en algunos casos necesita ser reemplazada¹².

Souza²⁷ defiende, a través de un informe de caso, que las carillas de zirconia, a pesar de que son un tema todavía muy reciente, tienen un gran resultado estético y mecánico pero admite que todavía se necesitan estudios prospectivos para consolidar la idea. Además, junto a una investigación de la literatura, recalca que tienen un gran resultado estético posterior (Rinke) y que el desgaste que producía la zirconia en el antagonista, era igual al del resto de cerámicas (Stober)²⁷. Masson¹ por el contrario opina que la zirconia al igual que el metal, no tiene tan buenas propiedades ópticas ya que no es capaz de transmitir la luz y su difusión¹.

Un estudio *in vitro* realizado por Starppert y colaboradores³¹, se efectuó con el fin de simular fuerzas masticatorias durante 5 años *in vivo* con cerámica de vidrio reforzada con leucita, para comprobar la longevidad y fallos que tenían las carillas con 3 tipos de restauraciones diferentes. Se realizó a través de 64 incisivos centrales libres de caries, los cuales se dividieron en 4 grupos: control; tallado vestibular (0,5mm); tallado vestibular (0,5mm) e incisal (0,2mm); tallado convencional para carillas, que incluía vestibular (0,5mm), incisal (0,3mm) y palatino (0,2mm). Finalmente se obtuvieron los siguientes resultados³¹:

Tabla 2 Probabilidad de supervivencia de IC en un simulador masticatorio

Group (n = 16)	Type of preparation	Number of failed specimens	Survival probability	95% CI upper	95% CI lower
NP	Unprepared (control)	3	0.81	0.93	0.57
WP	Window	1	0.94	1.00	0.72
IOP	Incisal overlapped	2	0.88	0.97	0.64
CVP	Complete veneer	1	0.94	1.00	0.72

CI, Confidence interval.

Tabla 2: fuente: Stappert³¹.

El estudio demuestra la efectividad de una mínima preparación vestibular, para reducir la probabilidad de fracturas debidas a fuerzas oclusales, y a la similitud de la resistencia de la cerámica y la del diente natural³¹.

La siguiente tabla recoge algunos reportes de casos y la visión de cada autor respecto a las carillas *no-prep / prep-less* (tallado, material, grosor):

AUTOR (AÑO)	MUESTRA (EDAD)	TIPO DE ESTUDIO	CLASIFICACIÓN	TALLADO (mm)	MATERIAL CERÁMICO	GROSOR MATERIAL (mm)	SEGUIMIENTO
Souza (2018) ²⁷	1 mujer (25)	Reporte de caso	<i>Prep-less</i>	0,3	Zirconia monolítica translúcida	0,3	1 año
Cançado (2018) ¹²	1 mujer (26)	Reporte de caso	<i>No-prep</i>	0	Feldespatos	-	6 años después tiene mala apariencia.
			<i>Prep-less</i>	0,3-0,5	Disilicato de litio	-	2 años
Lobo (2020) ³³	1 mujer (43)	Reporte de caso	<i>Prep-less</i>	-	Disilicato de litio	-	-
Zavanelli (2019) ¹⁸	1 mujer (21)	Reporte de caso	<i>Prep-less</i>	No refiere los cm	Disilicato de litio	-	-
Barrigón (2019) ⁵	1 mujer (21)	Reporte de caso	<i>No-prep</i>	0	Cerámica reforzada con leucita	-	-
Cedillo (2011) ⁹	1 mujer (-)	Reporte de caso	<i>No-prep</i>	Disminución de la convexidad dental a nivel papilar	Feldespáticas (Luminers)	0,2	-
Cunha (2015) ²⁹	1 hombre (-)	Reporte de caso	<i>Prep-less</i>	-	-	-	-

Molina (2016) ³⁵	1 mujer (-)	Reporte de caso	<i>Prep-less</i>	Chamfer cervical	-	-	2 años
Souza (2020) ²⁴	1 hombre (22)	Reporte de caso	<i>Prep-less</i>	Chamfer cervical y redondeado de ángulos	Disilicato de litio y recubrimiento con feldespatita	-	2 años
Cunha (2014) ²³	1 mujer (25)	Reporte de caso	<i>No-prep</i>	0	Disilicato de litio	-	-
Arcangelo (2017) ³⁶	1 hombre (-)	Reporte de caso	<i>No-prep</i>	0	Feldespatita	-	-
Coachman (2014) ³⁴	1 hombre (40-60)	Reporte de caso	<i>Prep-less</i>	0,3: 1/3 cervical 0,5: 1/3 medio 0,7: 1/3 incisal	Disilicato de litio	0,3	-

Tabla 3 Elaboración propia a partir de Souza, Caçado, Lobo, et al^{5,9,12,18,23,24,27,29,33-36}.

Cada autor tiene un concepto diferente, algunos consideran que las carillas *no-prep*, como su nombre indica, no tienen preparación alguna, mientras otros consideran que puede incluir una mínima preparación. Aun así, todos coinciden en que la preparación debería ser menor a 0,5 como se explica en la clasificación de LeSage¹⁵ expuesta anteriormente.

4.4. VENTAJAS Y DESVENTAJAS DE CARILLAS NO-PREP

Según Molina³⁵, en relación con las carillas *no-prep*, la zona que es más desafiante a la hora de manipularlas está localizada a nivel del margen gingival. Esto se debe a que es la zona de menor grosor, la cual puede ser propensa a fracturas. Además, es una zona de transición con el diente difícil de cementar; en la mayoría de los casos debido a la ausencia de una línea de terminación, lo que podría derivar en una incorrecta posición de la carilla tras el cementado. Añadido a esto, el hecho de que las carillas sean tan finas a nivel cervical puede ocasionar que no se consigan los cambios de color deseados³⁵. Molina³⁵, defiende que realizando una carilla con un grosor superior y una preparación parcial a nivel cervical de los dientes (*chamfer*), se podrían solucionar los problemas anteriormente expuestos, a la vez que se evitaría un sobrecontorneado que podría afectar a los tejidos blandos³⁵.

Arcangelo³⁶, por otro lado, defiende que el sobrecontorneado se puede evitar marcando la línea de máximo contorno del diente, y a su vez el límite de la carilla *no-prep*, de tal manera que al posicionar la restauración, no contacte con los tejidos blandos³⁶.

Tuncdemir y colaboradores²⁵ demuestran a través de un estudio *in vitro* que las carillas con preparación presentan mayor cambio de color que las que no tienen preparación²⁵.

4.5. INDICACIONES Y CONTRAINDICACIONES DE CARILLAS NO-PREP

Coachman³⁴, expone una técnica llamada *Do the Math* para calcular a través de una fórmula matemática, la preparación que habría que hacer en base al color del diente existente, y defiende que se puede variar uno o dos tonos el color con una carilla de 3mm. Para mayores cambios de color, sería necesario otro tipo de tratamientos más invasivos³⁴.

Da Cunha²⁹, expone la importancia de la dominancia de los incisivos centrales superiores en la sonrisa. Es imprescindible un adecuado color, forma, tamaño y proporción para una apariencia agradable, ya que son los dientes más visibles y, además, tienen funciones a nivel oclusal, como la de proporcionar una guía anterior. Las carillas *no-prep* de porcelana son una buena opción terapéutica para solucionar problemas como: color inadecuado; forma incorrecta; microdoncias de los incisivos centrales superiores; y la ausencia de guía anterior, siempre y cuando sean leves²⁹.

Todos los autores coinciden con las indicaciones de las carillas *no-prep*, pero todavía hay un tema en debate: el bruxismo. A pesar de que el bruxismo puede ser considerado contraindicación de carillas de porcelana por algunos autores, Zavanelli¹⁸ discierne, argumentándolo con un caso exitoso donde se rehabilita la función y la estética de una paciente con ayuda de un DSD. El autor, explica que el resultado es variable y que el fracaso de la

restauración suele ser por fracturas y despegamientos. Para mejorar el pronóstico, es necesaria la confección de una férula de descarga que el paciente usará obligatoriamente todas las noches¹⁸.

5. CONCLUSIONES

- El concepto de carillas *no-prep* todavía no es una técnica estandarizada, cada autor decide según su propio criterio la técnica, ya sea con o sin preparación, con material feldespático o ionómero de vidrio.
- El mejor material es la porcelana debido a su estética, biocompatibilidad y estabilidad de color. Hay dos tipos de cerámica que se usan en carillas *no-prep*, feldespática e ionómero de vidrio, el hecho de usar uno u otro va a depender del color del sustrato y de las fuerzas oclusales a las que va a estar sometido. En caso de que la situación sea favorable, se utilizarán las carillas feldespáticas.
- La mayor ventaja que aportan las carillas *no-prep* es la preservación del tejido dental sano. Los pacientes son cada vez más conscientes de la importancia que tienen los dientes, por lo que es una técnica muy aceptada. Por el contrario, dentro de las desventajas, se trata de un tratamiento muy limitado en cuanto a sus indicaciones, y a veces necesita de tratamiento interdisciplinar para poder llevarlo a cabo.
- Las indicaciones de carillas *no-prep* son muy concretas y limitadas, el diente debe presentar defectos ligeros, como pequeñas malposiciones y cambios leves de color. Debe tener suficiente esmalte para una correcta adhesión, y a parte, tener una buena salud oral para que exista el mínimo riesgo de fracaso.

5.1. LIMITACIONES DEL ESTUDIO

Por el momento, hay escasa literatura científica disponible sobre carillas mínimamente invasivas y sin preparación. Se describen muchos informes de casos, pero ninguno con un protocolo pautado, cada autor seguía su propio criterio.

5.2. FUTURAS LÍNEAS DE INVESTIGACIÓN

Los autores sugieren establecer protocolos teniendo en cuenta el tipo de material a usar en base a sus propiedades ópticas y mecánicas; fijar los criterios de selección de los pacientes correctos para la realización de carillas *no-prep*, debido a sus limitadas indicaciones; y la realización de estudios longitudinales sobre el tema, para averiguar los resultados a largo plazo y sus complicaciones.

6. RESPONSABILIDAD

Cada vez se hace más popular el concepto de odontología mínimamente invasiva, debido a la demanda de tratamientos conservadores por los pacientes, y a la preocupación de los profesionales por la pérdida de tejido dental sano, que repercute directa e indirectamente al paciente, puesto que puede provocar el fracaso del tratamiento por la falta de adhesión por ausencia de esmalte.

Las carillas *no-prep* consiste en un tratamiento muy poco invasivo, con cierta relevancia para fortalecer el esmalte, pero cuya función principal es la estética, algo que concierne cada vez más a la población. Se trata de un tratamiento que necesita detenida valoración por parte de distintos especialistas, y que cuando está indicado, es muy recomendable ya que en la odontología moderna se tiende a empezar por lo más conservador. Su mayor limitación es lo poco accesible que puede llegar a ser, ya que es muy costoso y en ocasiones requiere tratamientos previos.

7. BIBLIOGRAFÍA

1. Masson M AA. Rehabilitación del sector anterior con carillas de porcelana lentes de contacto, guiado por planificación digital. Informe de un caso. *Odontol Vital*. 2019;30:79–86.
2. Bello A, Jarvis R. A review of esthetic alternatives for the restoration of anterior teeth. *J Prosthet Dent*. 1997;78(5):437–40.
3. Mozayek R, Alkhalil MA, Allaf M, Dayoup S. Evaluation of the fracture strength of porcelain sectional veneers made from different sintered feldspathic porcelains: An in vitro study. *Dent Med Probl*. 2019;56(3):273–8.
4. Mozayek R, Allaf M, Dayoub S. Porcelain sectional veneers, an ultra-conservative technique for diastema closure (Three-dimensional finite element stress analysis). *Dent Med Probl*. 2019;56(2):179–83.
5. Barrigón G, Parralo M, Charlén I, Oteo C, Del Solar D. Consideraciones diagnósticas y clínicas en carillas no-prep. *Gac Dent*. 2019;313:40–67.
6. Zarone F, Leone R, Di Mauro MI, Ferrari M, Sorrentino R. No-preparation ceramic veneers: A systematic review. *J Osseointegration*. 2018;10(1):17–22.
7. Barbero JG. *Patología y terapéutica dental : operatoria dental y endodoncia*. 2ª edición. Barbero JG, editor. Barcelona: Elsevier Health Sciences; 2015. 701 páginas.
8. Nocchi Conceição E. *Odontología restauradora : salud y estética*. 2a ed. Panamericana E, editor. Buenos Aires; 2008. 541 páginas.
9. Cedillo J. Carillas de porcelana sin preparación. *Rev la Asoc Dent Mex*. 2011;68(6):314–

- 22.
10. Hajtó J. Restauraciones del sector anterior: ¿son las carillas cerámicas la mejor opción? *Quintessence Int (Berl)*. 2011;24(8):391–8.
 11. Agustín R, Ausina D, Fernández L, Román JL, Faus J, Solá MF. Dental-gingival remodeling with BOPT no-prep veneers. *J Clin Exp Dent*. 2017;9(12):e1496–500.
 12. Cançado T, Ferreira M, Celso J, Silami C, Nogueira A, Yamauti M. Esthetic rehabilitation of anterior teeth with different thicknesses of porcelain laminate veneers: An 8-year follow-up clinical evaluation. *Eur J Dent*. 2018;12(4):590–3.
 13. Vadini M, D’Amario M, De Angelis F, Falco A, D’Arcangelo C. No-Prep Rehabilitation of Fractured Maxillary Incisors with Partial Veneers. *J Esthet Restor Dent*. 2016;28(6):351–8.
 14. Materdomini D, Friedman M. The Contact Lens Effect: Enhancing Porcelain Veneer Esthetics. *J Esthet Restor Dent*. 1995;7(3):99–103.
 15. LeSage B. Establishing a classification system and criteria for veneer preparations. *Compendium*. 2013;34(2):104–15.
 16. Radz GM. Minimum thickness anterior porcelain restorations. *Dent Clin North Am* [Internet]. 2011;55(2):353–70. Available from: <http://dx.doi.org/10.1016/j.cden.2011.01.006>
 17. Oudkerk J, Eldafrawy M, Bekaert S, Grenade C, Vanheusden A, Mainjot A. The one-step no-prep approach for full-mouth rehabilitation of worn dentition using PICN CAD-CAM restorations: 2-yr results of a prospective clinical study. *J Dent* [Internet]. 2020;92(103245). Available from: <https://doi.org/10.1016/j.jdent.2019.103245>
 18. Zavanelli A, Otavio S, Ferreira M, Rodrigo A, Alexandre Z, Vitor M. Microveneers and

- digital smile designer: Planning for a patient with bruxism: A 1-year follow-up. *J Adv Clin Res Insights*. 2019;6(3):94–9.
19. Morita R, Hayashida M, Pupo Y, Berger G, Reggiani R, Betiol E. Minimally Invasive Laminate Veneers: Clinical Aspects in Treatment Planning and Cementation Procedures. *Case Rep Dent*. 2016;
 20. Farias A, Ferreira E, Sánchez A, Sánchez A, Vilanova L. Esthetic Rehabilitation of the Smile with No-Prep Porcelain Laminates and Partial Veneers. *Case Rep Dent*. 2015;
 21. Pini N, Baggio F, Leite D, Lovadino J, Suga R, Pascotto R. Advances in dental veneers: Materials, applications, and techniques. *Clin Cosmet Investig Dent*. 2012;4:9–16.
 22. Cosenza H, Pamato S, Vermudt A, Pereira JR. Interdisciplinary approach using composite resin and ceramic veneers to manage an esthetic challenge. *J Prosthet Dent* [Internet]. 2021;125(3):383–6. Available from: <https://doi.org/10.1016/j.prosdent.2020.01.013>
 23. Cunha L, Pedroche L, Gonzaga C, Furuse A. Esthetic, occlusal, and periodontal rehabilitation of anterior teeth with minimum thickness porcelain laminate veneers. *J Prosthet Dent* [Internet]. 2014;112(6):1315–8. Available from: <http://dx.doi.org/10.1016/j.prosdent.2014.05.028>
 24. Souza R, Silva N, Miranda L, Araújo G, Moura D, Medeiros H. Two-year follow-up of ceramic veneers and a full crown treated with self-etching ceramic primer: A case report. *Oper Dent*. 2020;45(4):352–8.
 25. Tuncdemir M, Gulbahce N, Aykent F. Comparison of color stability of two laminate veneers cemented to tooth surfaces with and without preparation. *J Esthet Restor Dent*. 2020;32(6):554–9.

26. Perdigão J. Current perspectives on dental adhesion: (1) Dentin adhesion – not there yet. *Jpn Dent Sci Rev.* 2020;56(1):190–207.
27. Souza R, Barbosa F, Araújo G, Miyashita E, Bottino MA, Melo R, et al. Ultrathin monolithic zirconia veneers: Reality or future? report of a clinical case and one-year follow-up. *Oper Dent.* 2018;43(1):3–11.
28. González V, González I, Cura M, Ceballos L. Resistencia adhesiva a la dentina de restauraciones indirectas de composite. *Gac Dent.* 2014;254:84–95.
29. Cunha L, Gonzaga C, Saab R, Mushashe A, Correr G. Rehabilitation of the dominance of maxillary central incisors with refractory porcelain veneers requiring minimal tooth preparation. *Quintessence Int (Berl).* 2015;46(10):837–41.
30. Yanikian C, Yanikian F, Sundfeld D, Lins R, Martins L. Direct composite resin veneers in nonvital teeth: A still viable alternative to mask dark substrates. *Oper Dent.* 2019;44(4):E159–66.
31. Stappert C, Ozden U, Gerds T, Strub J. Longevity and failure load of ceramic veneers with different preparation designs after exposure to masticatory simulation. *J Prosthet Dent.* 2005;94(2):132–9.
32. Wells D. Low-Risk Dentistry Using Additive-Only ("No-prep) Porcelain Veneers. *Kois Cent.* 2011;32(5):50–6.
33. Lobo M, Liberato W, Vianna M, Cavalcante L, Schneider L. Adhesion and optics: The challenges of esthetic oral rehabilitation on varied substrates—Reflections based on a clinical report. *J Prosthet Dent [Internet].* 2020;125(1):15–7. Available from: <https://doi.org/10.1016/j.prosdent.2019.12.004>
34. Coachman C, Gurel G, Calamita M, Morimoto S, Paolucci B, Sesma N. The Influence

- of Tooth Color on Preparation Design for Laminate Veneers from a Minimally Invasive Perspective: Case Report. *Int J Periodontics Restorative Dent*. 2014;34(4):453–9.
35. Molina I, Molina G, Stanley K, Lago C, Xavier C, Maziero C. Partial-prep bonded restorations in the anterior dentition: Long-term gingival health and predictability. A case report. *Quintessence Int (Berl)*. 2016;47(1):9–16.
36. D’Arcangelo C, Vadini M, D’Amario M, Chiavaroli Z, De Angelis F. Protocol for a new concept of no-prep ultrathin ceramic veneers. *J Esthet Restor Dent*. 2017;1–7.

8. ANEXOS

Masson, M. J., Armas, A. C. (2019). Rehabilitación del sector anterior con carillas de porcelana lentes de contacto, guiado por planificación digital. Informe de un caso. *Odontología Vital* 30:79-86.

Rehabilitación del sector anterior con carillas de porcelana lentes de contacto, guiado por planificación digital. Informe de un caso

Front sector rehabilitation with porcelain contact lens veneers guided by digital planning. Case report

*María José Masson Palacios, UTE, Ecuador, majomasson@hotmail.com
Ana del Carmen Armas Vega, UTE, Ecuador, ana_del_ec@yahoo.es*

RESUMEN

Los pacientes acuden cada vez más, al consultorio odontológico a fin de mejorar el aspecto de su sonrisa, ampliando la demanda de procedimientos estéticos, y es responsabilidad del odontólogo ofrecer distintas técnicas para que el paciente acoja un tratamiento óptimo, orientado a la conservación de los tejidos dentales en este aspecto; las carillas de cerámica sin preparación, o lentes de contacto, constituyen una opción conservadora de recubrimiento parcial, que mejora la estética del sector anterior, el siguiente caso describe una posibilidad restauradora estética mínimamente invasiva para la rehabilitación del sector anterior, con el uso de porcelana IPS e. max® Press, resaltando el proceso de planificación por medio del diseño digital en dos dimensiones.

PALABRAS CLAVE

Carillas, lente de contacto, digital smile design.

ABSTRACT

Patients increasingly come to the dental office to improve the appearance of their smile, expanding the demand for aesthetic procedures, and it is the dentist's responsibility to offer different techniques for the patient to receive an optimal treatment, aimed at preserving the dental tissues in this aspect, unprepared ceramic veneers, or contact lenses, are a conservative alternative, which improves the aesthetics of the front sector, the following case describes a minimally invasive aesthetic restorative alternative for the rehabilitation of the anterior sector, with the use of IPS e. max® Press porcelain, highlighting the planning process through digital design in two dimensions.

KEYWORDS

Veneers, contact lens, digital smile design.

Recibido: 13 marzo, 2018

Aceptado para publicar: 12 julio, 2018

A review of esthetic alternatives for the restoration of anterior teeth

Antonio Bello, DDS,^a and Ronald H. Jarvis, DDS, MSD^b

Universidad Nacional Autonoma de Mexico, Lomas de Chapultec, Mexico,
and State University of New York at Buffalo, Buffalo, N.Y.

Purpose. This article describes different options for the esthetic treatment of anterior teeth, starting with minimally invasive procedures, such as facial surface bleaching and bonding with composites.

Methods. The importance of metal ceramic restorations, porcelain shoulder techniques, and metal free ceramics are also emphasized. The options are carefully demonstrated to identify advantages and limitations of each technique. (J Prosthet Dent 1997;78:437-40.)

In the restoration of anterior teeth, there are many factors to be considered that depend on the patient's expectations and the expertise of the dental practitioner. The purpose of this article is to provide a checklist of esthetic systems for the restoration of anterior teeth and to cover important factors to consider before choosing a specific treatment.

MINIMALLY INVASIVE PROCEDURES

Bleaching

Patients frequently desire improvement in their smiles because fashion magazines emphasize innovative methods to improve esthetics. However, potential patients are unaware of treatment options, so it is the responsibility of the dentist to suggest the most conservative, desirable treatment. When patients complain of "ugly teeth," the dentist must determine whether the term *ugly* is the result of color or shape of the dentition. Therefore the following questions are appropriate: (1) Are you comfortable with the shape of your teeth and (2) do you approve of the color of your teeth?

If the answer to question one is affirmative and color is the main concern, bleaching the teeth is a reasonable choice.¹ However, the patients should understand that this procedure is only considered a temporary measure. Furthermore, whiter teeth are merely an interim measure if smoking or excessive drinking of liquids that stain are continued.

Resin bonding

When a patient wishes to improve their smile because of dark spaces between the teeth (Fig. 1), esthetic bonding may be the resolution. If the configuration of the teeth is modified, the patient can achieve satisfaction. If the patient does not smoke or drink dark-colored liquids that can alter the color of the teeth, esthetic bond-

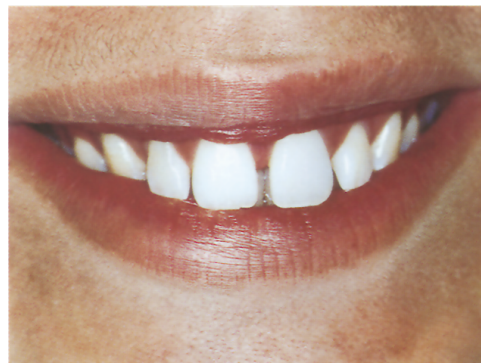

Fig. 1. Patient with diastemata between central and lateral incisors.

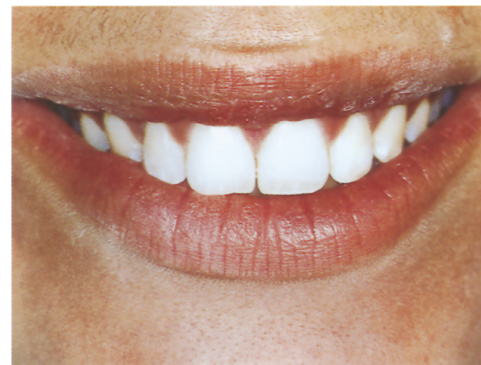

Fig. 2. Diastemata were closed with composites, following natural outline of teeth.

ing with composites is the most conservative approach for several reasons; namely, (1) sound tooth structure will not be removed, (2) anesthetics are infrequent, (3) one appointment is common, and (4) the professional fee is usually inexpensive.

Presented before the American Prosthodontic Society, Chicago, Illinois, February 1996.

^aAssociate Clinical Professor, Department of Prosthodontics, Universidad Nacional Autonoma de Mexico.

^bAssociate Clinical Professor, Department of Prosthodontics, School of Dental Medicine, State University of New York at Buffalo.

Evaluation of the fracture strength of porcelain sectional veneers made from different sintered feldspathic porcelains: An in vitro study

Ocena wytrzymałości na złamanie częściowych licówek porcelanowych otrzymanych z różnych spiekanych ceramik skaleniowych – badanie in vitro

Rami Shurbaji Mozayek^{1,A–F}, Manar Ali Alkhalil^{1,A–F}, Mirza Allaf^{1,A,E,F}, Suleiman Dayoub^{2,A,E,F}

¹ Department of Fixed Prosthodontics, Faculty of Dentistry, Damascus University, Syria

² Department of Periodontology, Faculty of Dentistry, Damascus University, Syria

A – research concept and design; B – collection and/or assembly of data; C – data analysis and interpretation;
D – writing the article; E – critical revision of the article; F – final approval of the article

Dental and Medical Problems, ISSN 1644-387X (print), ISSN 2300-9020 (online)

Dent Med Probl. 2019;56(3):273–278

Address for correspondence

Manar Ali Alkhalil
E-mail: manarkhl@hotmail.com

Funding sources

None declared

Conflict of interest

None declared

Received on December 26, 2018
Reviewed on February 28, 2019
Accepted on April 23, 2019

Published online on September 30, 2019

Cite as

Shurbaji Mozayek R, Ali Alkhalil M, Allaf M, Dayoub M.
Evaluation of the fracture strength of porcelain sectional veneers made from different sintered feldspathic porcelains: An in vitro study. *Dent Med Probl.* 2019;56(3):273–278.
doi:10.17219/dmp/108852

DOI

10.17219/dmp/108852

Copyright

© 2019 by Wrocław Medical University
This is an article distributed under the terms of the Creative Commons Attribution 3.0 Unported License (CC BY 3.0) (<https://creativecommons.org/licenses/by/3.0/>)

Abstract

Background. Porcelain sectional veneers with no preparation (no-prep) are an ultra-conservative choice for the esthetic treatment of the anterior teeth. They can be made from a sintered feldspathic porcelain, which gives a great appearance with small thickness, but there are still concerns about the fracture strength of this material.

Objectives. The aim of this study was to evaluate the fracture strength of porcelain sectional veneers made from 2 different sintered feldspathic porcelains.

Material and methods. Twenty recently extracted human incisors were randomly divided into 2 groups according to the porcelain material (n = 10). The 1st group was applied the IPS Style[®] Ceram feldspathic porcelain and the 2nd group – GC Initial[™] MC. The porcelain sectional veneers were fabricated following the manufacturers' instructions. After the veneers bonded with resin cement (Variolink[®] N), the fracture strength was measured using a universal testing machine (Instron[®]1195) at 1 mm/min until failure occurred. Failure modes were determined under a stereomicroscope.

Results. The mean fracture strength for group IPS Style Ceram was higher than that for group GC Initial MC (182.7 N and 155.7 N, respectively). The lowest value was observed in group IPS Style Ceram (78 N) and the highest value – also in the group IPS Style Ceram (294 N). Student's *t*-test demonstrated no statistically significant differences between the 2 groups ($p > 0.05$).

Conclusions. There was no difference in the fracture strength of the porcelain sectional veneers for the 2 types of sintered porcelain used in this study. Cohesive failure within the porcelain sectional veneer was the most common mode of failure.

Key words: fracture strength, porcelain sectional veneers, no-prep, feldspathic porcelain, ultra-thin veneers

Słowa kluczowe: wytrzymałość na złamanie, częściowe licówki porcelanowe, no-prep, ceramika skaleniowa, ultracienkie licówki

Porcelain sectional veneers, an ultra-conservative technique for diastema closure (three-dimensional finite element stress analysis)

Ultrazachowawcza technika zamykania diastem za pomocą częściowych licówek porcelanowych (analiza naprężenia trójwymiarową metodą elementów skończonych)

Rami Shurbaji Mozayek^{1,A-F}, Mirza Allaf^{1,A,C,E,F}, Suleiman Dayoub^{2,A,E,F}

¹ Department of Fixed Prosthodontics, Faculty of Dentistry, Damascus University, Syria

² Department of Periodontology, Faculty of Dentistry, Damascus University, Syria

A – research concept and design; B – collection and/or assembly of data; C – data analysis and interpretation; D – writing the article; E – critical revision of the article; F – final approval of the article

Dental and Medical Problems, ISSN 1644-387X (print), ISSN 2300-9020 (online)

Dent Med Probl. 2019;56(2):179–183

Address for correspondence

Rami Shurbaji Mozayek
E-mail: ramishm88@gmail.com

Funding sources

None declared

Conflict of interest

None declared

Received on January 26, 2019

Reviewed on January 27, 2019

Accepted on February 20, 2019

Published online on May 17, 2019

Cite as

Shurbaji Mozayek R, Allaf M, Dayoub S. Porcelain sectional veneers, an ultra-conservative technique for diastema closure (three-dimensional finite element stress analysis). *Dent Med Probl.* 2019;56(2):179–183. doi:10.17219/dmp/104602

DOI

10.17219/dmp/104602

Copyright

© 2019 by Wrocław Medical University
This is an article distributed under the terms of the Creative Commons Attribution 3.0 Unported License (CC BY 3.0) (<https://creativecommons.org/licenses/by/3.0/>)

Abstract

Background. Diastema can be closed using conservative and non-conservative techniques. Composite resin wings and ceramic veneers are the most common treatment options if there is no indication for orthodontic treatment. A novel ultra-conservative technique has been introduced to the practice, i.e., porcelain sectional veneers can be fabricated with no or minimum preparation. However, porcelain is known for its poor mechanical properties and the long-term survival of such restorations is questionable.

Objectives. This paper aimed to investigate the mechanical aspects of porcelain sectional veneers by means of the finite element method (FEM).

Material and methods. A three-dimensional (3D) model of porcelain sectional veneers on the upper central incisors with diastema was obtained by the reversed engineering method starting from a cone-beam computed tomography (CBCT) image. A 100 N occlusal force was applied parallel and 135° to the longitudinal axis, respectively. For each direction the force was applied once with direct contact and again with no contact with the porcelain sectional veneers. For each of the resulting 4 scenarios, a 3D finite element analysis was simulated and the maximum equivalent von Mises stress was compared to porcelain flexural strength.

Results. Higher stresses were detected when the force was applied on the porcelain sectional veneers and they were increased dramatically with the inclined force.

Conclusions. Direct occlusal contact has to be avoided when using porcelain sectional veneers and the margin positions must be chosen carefully. The occlusal scheme must be noted carefully before choosing this type of restoration.

Key words: finite element, diastema, porcelain sectional veneers, no-prep

Słowa kluczowe: element skończony, diastema, częściowe licówki porcelanowe, licówki no-prep



Dr. Gonzalo Barrigón Benítez

Licenciado en Odontología por la Universidad de Oviedo. Máster en Odontología Estética por la Universidad Complutense de Madrid (UCM). Profesor Colaborador del Máster de Odontología Estética (UCM). Práctica privada en Odontología Estética y Rehabilitación Oral en la Clínica Dental Barrigón (Valladolid).

Dra. Marina Parralo Preboste

Graduada en Odontología (UCM). Máster en Ortodoncia (UCM). Profesora Colaboradora del Máster de Ortodoncia (UCM). Práctica privada en Madrid.

Dr. Ignacio Charlén Díez

Licenciado en Odontología por la Universidad Europea de Madrid (UEM). Máster en Odontología Estética (UCM). Profesor Colaborador del Máster de Odontología Estética (UCM). Práctica Privada en Odontología Estética y Rehabilitación Oral en Clínica Díez y Charlén (Madrid).

Dr. Carlos Oteo Morilla

Licenciado en Odontología (UEM). Máster Oficial en Ciencias Odontológicas (UCM). Máster en Odontología Estética (UCM). Doctor Cum Laude en Odontología. Profesor Colaborador del Máster de Odontología Estética (UCM). Práctica privada en Odontología Estética y Rehabilitación Oral en Madrid.

Daniel Del Solar Acedo

Técnico especialista en Prótesis Dental. Instituto José Manzano (Don Benito, Badajoz). Higienista Dental por CEMD (Oviedo). Práctica privada en Badajoz.

CONSIDERACIONES DIAGNÓSTICAS Y CLÍNICAS EN CARILLAS NO-PREP

A propósito de un caso

RESUMEN

El objetivo de este artículo es la exposición de un caso clínico con una exigencia estética muy elevada, resuelto con carillas no-prep (o sin preparación) y tratamiento ortodóncico previo. Se presentará el protocolo multidisciplinar que se ha llevado a cabo, explicando por qué se realiza cada fase del tratamiento, qué nos aporta, y cómo se ejecutó.

Asimismo, se discutirán aspectos relacionados con las carillas no-prep: la selección meticulosa del caso, los factores que nos limitan a la hora de indicarlas, y si son subsanables con tratamientos previos no restauradores; las ventajas y desventajas específicas de este tipo de restauraciones; las dificultades que afrontamos en su manejo clínico y en el laboratorio; y una breve revisión de la literatura acerca de este tipo de carillas.

Palabras clave: carillas no-prep; tratamiento multidisciplinar; planificación estética; Diseño de Sonrisa Digital; setup ortodóncico; ortodoncia estética-

“ LAS CARILLAS NO-PREP SON UNA SOLUCIÓN TERAPÉUTICA PROMETEDORA QUE PRESENTAN ALGUNAS VENTAJAS FRENTE A LAS CARILLAS CON PREPARACIÓN

mente guiada; Odontología adhesiva mínimamente invasiva.

ABSTRACT

The purpose of this article is to examine a clinical case with a high esthetic demand, treated with no-

No-preparation ceramic veneers: a systematic review

> FERNANDO ZARONE¹, RENATO LEONE², MARIA IRENE DI MAURO³, MARCO FERRARI³, ROBERTO SORRENTINO⁵

¹ MD, DDS, Professor and Chair, Department of Neurosciences, Reproductive and Odontostomatological Sciences, University "Federico II" of Naples, Naples, Italy

² DDS, MSc, PhD, Department of Neurosciences, Reproductive and Odontostomatological Sciences, University "Federico II" of Naples, Naples, Italy

³ Undergraduate student, Department of Neurosciences, Reproductive and Odontostomatological Sciences, University "Federico II" of Naples, Naples, Italy

⁴ MD, DDS, PhD, Professor and Chair, Department of Medical Biotechnologies, Division of Fixed Prosthodontics, University of Siena, Siena, Italy

⁵ DDS, MSc, PhD, Research Professor, Department of Neurosciences, Reproductive and Odontostomatological Sciences, University "Federico II" of Naples, Naples, Italy

TO CITE THIS ARTICLE

Zarone F, Leone R, Di Mauro MI, Ferrari M, Sorrentino R. No-preparation ceramic veneers: a systematic review. *J Osseointegr* 2018;10(1):17-22.

DOI 10.23805 /JO.2018.10.01.01

ABSTRACT

Aim The main objective of the present systematic review was to investigate the validation of no-preparation ceramic veneers as restorations.

Materials and Methods Pubmed, Evidence-Based Dentistry, BMJ Clinical Evidence, Embase, Dynamed and Opengrey were analyzed in order to identify randomized controlled clinical trials evaluating the clinical outcomes of no-preparation ceramic veneers; manual researches were performed as well.

Results Database search produced 2551 records. After removal of duplicates and a careful examination of titles and abstracts, the reviewers excluded all of the studies. Manual and grey literature did not yield any other relevant article.

Conclusions Due to the lack of data, at the moment achieving a definitive clinical statement regarding the "no-prep" technique is not possible. Further clinical studies are needed to assess the effectiveness of no-preparation ceramic veneers. No-prep veneers can be considered as conservative treatments which should be carefully recommended and request a cautious selection of cases. Further controlled clinical researches are necessary to clearly identify predictable clinical protocols and evaluate the long-term outcomes of such restorations.

KEYWORDS Systematic review; No-preparation veneers; No-prep; Prepress; Ceramic veneers; Minimally invasive.

INTRODUCTION

In response to an increasing patients' demand for non-invasive, more and more esthetic and durable dental restorations, over the last decades the use of porcelain laminate veneers has become a widespread approach to restore worn, misaligned, fractured, discolored and malformed teeth. Moreover, the clinical indications of such restorations have been progressively increased due to the development of innovative ceramic materials that have been recently introduced in the market (1-4). The reduced thicknesses requested by the new biomimetic ceramic materials, together with an effective bonding to enamel and dentin, have allowed for a noticeable reduction of preparation invasiveness, leading to a significant preservation of tooth structure in agreement with the well consolidated principles of minimally invasive dentistry.

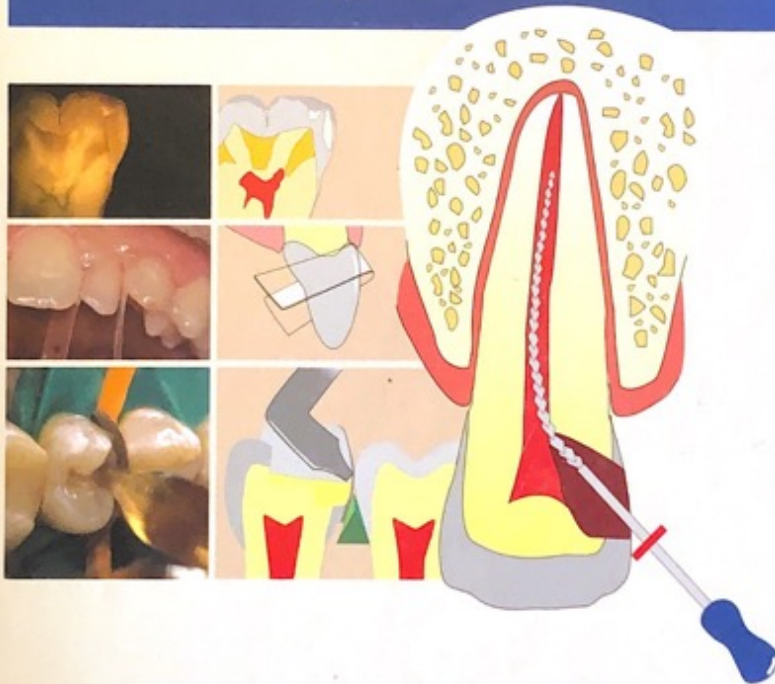
Compared to the aggressive preparations of the past, a conservative approach allows for a better management of different mechanical and clinical problems (5) in that it reduces flexing stress and strains inside the restorations (6-8), limiting at the same time the amount of exposed dentine and ensuring a higher amount of enamel substrate available for adhesion (9). It has been shown that the preservation of a large enamel surface and the positioning of the restoration margins within the enamel tissue are paramount factors for the achievement of good clinical outcomes with porcelain laminate veneers (10, 11).

Due to this clinical trend, in the last decade, additional partial veneers, "minimal preparation" and even "no-preparation (or prepress)" ceramic veneers have been

PATOLOGÍA Y TERAPÉUTICA DENTAL

Operatoria dental
y endodoncia
2.ª edición

JAVIER GARCÍA BARBERO

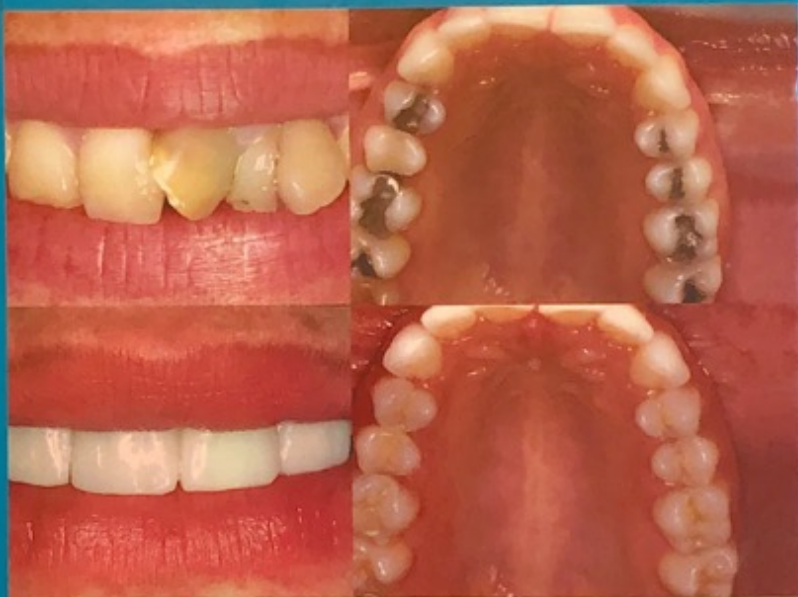

Nocchi Conceição

Odontología restauradora

Salud y estética

2ª EDICIÓN



EDITORIAL MEDICA
panamericana

Carillas de porcelana sin preparación.

Non preparation porcelain veneers.

Dr. José de Jesús Cedillo Valencia
Maestro del Postgrado de Prótesis Bucal Fija y Removible.
Universidad Autónoma de Ciudad Juárez

Recibido: Octubre de 2011.
Aceptado para publicación: Octubre de 2011.

Resumen

La Odontología Cosmética ha evolucionado rápidamente en los últimos 20 años. El tratamiento conservador usando carillas de porcelana sin preparar, o con mínima preparación, ha sido clínicamente probado. Los pacientes están demandando procedimientos conservadores, sin desgastar sus piezas dentales y procedimientos sin dolor, con excelentes resultados estéticos. Desde que Salió al mercado la Porcelana Cerinate®, la técnica no invasiva de Lumineers™, el procedimiento convencional de preparación, es cada vez más obsoleto. La Porcelana Cerinate es una porcelana feldespática que ha sido usada y estudiada por muchos años; ya que tiene una estructura microcristalina, esos cristales tienen una distribución uniforme, reforzada con cristales irregulares de leucita. Esta porcelana puede ser fabricada con 0.2 mm. de espesor (aproximadamente como el grosor de una lente de contacto). La gran ventaja de la Porcelana Cerinate, es el hecho de que se pueden elaborar carillas con gran dureza y menor espesor.

Entre las principales ventajas que tiene, comparada con la técnica convencional, es la menor sensibilidad posoperatoria, ya que la adhesión se lleva a cabo en el esmalte, además refuerza el esmalte debilitado o agrietado. También evita el tener que colocar provisionales, provee un blanqueamiento permanente, y lo más importante, es el que evita la reducción de estructura dental, siendo el principal motivo de los pacientes para elegir este sistema.

Palabras clave: *carilla, estética, porcelana, adhesión, cemento, resina, esmalte, desgaste.*

Abstract.

Cosmetic dentistry has evolved rapidly over the last 20 years. Minimally-invasive treatment using porcelain veneers that require no or minimal preparation has been clinically proven. Patients are now requesting discreet, esthetically pleasing, pain-free procedures that cause no wear to teeth and require no preparation. Since the launch on the market of Cerinate Porcelain®, the non-invasive Lumineers™ technique, the conventional veneer preparation procedure has become increasingly obsolete. Cerinate Porcelain® is a feldspathic porcelain that has been used and studied for many years due to its microcrystal-based structure; the crystals are uniformly distributed and reinforced by irregular leucite crystals. The porcelain can be manufactured to a thickness of 0.2 mm (around the thickness of contact lens). The main advantage of Cerinate Porcelain® is that it allows the manufacture of slender though extremely strong veneers.

One of the main advantages compared to the conventional technique is the reduction in postoperative sensitivity, since the adhesion between the tooth and the veneer takes place in the enamel. Furthermore, Lumineers™ also reinforce weakened or cracked enamel. Another advantage they offer is that they avoid the need for provisional restorations and provide permanent whitening; most significantly, they prevent the reduction of dental structure, which is the main incentive for patients when opting for this technique.

Key words: *veneer, esthetics, porcelain, adhesion, cement, composite, enamel, wear*
Introducción.

Restauraciones del sector anterior: ¿son las carillas cerámicas la mejor opción?

Jan Hajtó, Dr. med. dent.

En los casos con una indicación correcta las carillas cerámicas son sin duda la mejor opción en lo que a estética, durabilidad y biocompatibilidad se refiere. Se pueden utilizar carillas parciales, que no cubren la cara vestibular completamente, para aumentar o modificar la estructura dentaria siempre y cuando permitan conservar el color dentario global. Estos tratamientos son tan conservadores como una restauración con composite de similares características, que por lo general constituye la alternativa más rentable y en muchos casos ofrece resultados equivalentes. Cuanto menores sean las correcciones a realizar mejor habrá que analizar si una restauración de cerámica indirecta ofrece ventajas frente a una alternativa de composite directa. Los defectos pequeños, circunscritos y característicos de la lesión de caries y las obturaciones preexistentes no son una indicación adecuada para una restauración con carillas; lo son para una restauración con composite. La frontera a partir de la cual es más conveniente una restauración con carillas indirecta se moverá en función de las expectativas estéticas del paciente, de la capacidad del propio odontólogo y de la emvergadura del defecto o de los problemas estéticos, y en cada caso se situará en un punto distinto.

(Quintessenz. 2010;61(5):521-8)

Correspondencia: J. Hajtó.
Weinstrasse 4, 80333 Múnich, Alemania.
Correo electrónico: dr.jan.hajto@t-online.de

Introducción

«Restauraciones del sector anterior: ¿son las carillas cerámicas la mejor opción?». Esta pregunta tan clara fue el título propuesto al autor por el coordinador técnico del presente número monográfico, el Prof. Frankenberger, para abordar esta cuestión. Y una pregunta tan clara merece una respuesta que no deje lugar a dudas. A continuación se intentará abordar la cuestión de forma sistemática dando respuesta a las siguientes preguntas:

1. ¿Qué son las carillas cerámicas?
2. ¿Son las carillas cerámicas realmente la mejor opción? Si es así, ¿en qué sentido?
3. ¿En qué casos no son las carillas cerámicas la mejor opción? ¿Qué alternativas existen?

Definición de «carillas cerámicas»

La palabra inglesa «veneer» significa literalmente «frente», «enchapado» o «recubrimiento». Con el término «carillas» o «veneers» se hace referencia por lo general a diversos tipos de restauraciones indirectas en forma de láminas con cementación adhesiva. En el sector anterior son las siguientes:

- Carillas vestibulares en dientes anteriores
- Carillas parciales:
 - Reconstrucción de bordes incisales
 - Carillas palatinas en dientes anterosuperiores para reconstruir superficies guía
 - «Carillas adicionales» mínimamente invasivas
 - Carillas cervicales de cerámica
- Carillas sin preparación dentaria previa
- Carillas de 360° y coronas tres cuartos adhesivas

En el sector posterior se utilizan los siguientes tipos de carillas:

- Carillas vestibulares en premolares y molares
- Carillas oclusales (denominadas «table tops») en dientes posteriores

Quintessence (ed. esp.) Volumen 24, Número 8, 2011 391

Dental-gingival remodeling with BOPT no-prep veneers

Rubén Agustín-Panadero ¹, Daniel Ausina- Escribuela ², Lucía Fernández-Estevan ¹, Juan-Luis Román-Rodríguez ¹, Joan Faus-López ³, María-Fernanda Solá-Ruiz ⁴

¹ DMD, PhD, Associate Professor, Department of Dental Medicine, Faculty of Medicine and Dentistry, University of Valencia, Spain

² DMD, In private dental practice, Spain

³ DMD, PhD, Director of Valencia Dental Research Institute (IVIO), Valencia, Spain

⁴ DMD, PhD, MD, Adjunct Professor, Department of Dental Medicine, Faculty of Medicine and Dentistry, University of Valencia, Spain

Correspondence:
University of Valencia
C/ Gascó Ollag, 1
46021, Valencia
Spain
rubenagustinpanadero@gmail.com

Received: 24/10/2017
Accepted: 09/11/2017

Please cite this article in press as: Agustín-Panadero R, Ausina- Escribuela D, Fernández-Estevan L, Román-Rodríguez JL, Faus-López J, Solá-Ruiz MF. Dental-gingival remodeling with BOPT no-prep veneers. J Clin Exp Dent. (2017), doi:10.4317/jced.54463

Abstract

Recent years have seen increasing demand for treatments aimed at improving dental esthetics. In this context, both patients and dentists prefer to preserve dental structures as far as possible; thanks to technological advances, especially in adhesive dentistry, new materials and minimally invasive techniques such as “no-prep” (no preparation) veneers have made this possible. Nevertheless, no-prep veneers have specific indications and suffer certain disadvantages.

Objectives: This clinical case describes the rehabilitation of the upper anterior region by means of no-prep veneers, with BOPT (Biologically Oriented Preparation Technique) cervical margins. The patient had requested an aesthetic treatment to improve irregularities of the gingival margins associated with the presence of diastemata resulting from microdontia.

Key words: BOPT, micro-veneers, hybrid ceramic, ultra-fine veneers, diastemata, without prosthetic finish line, no-prep.

Introduction

The last 30 years (1) has seen the introduction of ceramic veneers aimed at improving the shape, alignment, and color of teeth as a response for patients increasing demands for improved dental esthetics. To begin with, these were designed for use without any kind of preparation, but later, in response to the deficiencies of mate-

rials and techniques, teeth underwent a milling procedure to reduce their thickness and so accommodate the ceramic veneers, ensuring esthetic outcomes and the treatment’s long-term durability (1). However, patients and clinicians’ concern to preserve a maximum quantity of healthy dental structures has led to further research into new materials and techniques aimed at maximizing

Esthetic rehabilitation of anterior teeth with different thicknesses of porcelain laminate veneers: An 8-year follow-up clinical evaluation

Tassiana Cançado Melo Sá¹, Monize Ferreira Figueiredo de Carvalho¹,
Julio Celso M. de Sá², Claudia Silami Magalhães¹, Allyson Nogueira Moreira¹,
Monica Yamauti¹

Correspondence: Dr. Monica Yamauti
Email: myamauti@gmail.com

¹Department of Restorative Dentistry, Faculty of Dentistry, Federal University of Minas Gerais, Belo Horizonte, Minas Gerais, Brazil,
²Department of Restorative Dentistry, Faculty of Dentistry, Newton Paiva University Center, Belo Horizonte, Minas Gerais, Brazil

ABSTRACT

This clinical report describes an 8-year follow-up evaluation using different thicknesses of porcelain laminate veneers of diastema and malformed anterior teeth. Minimally invasive treatment with no preparation or minimal reduction options could be considered and chosen based on the characteristics of each case. Laminate veneers with or without reduction can offer an excellent result regarding esthetics and function. Despite its failure without reduction, this treatment is indicated because it can be applied regardless of the structure of the teeth. At first, no tooth preparation with rotary instruments was performed, and porcelain laminates of minimum thickness were made for the four maxillary anterior teeth. After 6 years, the adhesive interfaces were stained, and the patient was unsatisfied with the esthetics of her smile. Therefore, at that time, the professional decided to prepare the anterior teeth for porcelain laminate veneers. Diastema closure and/or correction of malformed anterior teeth using porcelain laminate veneers is a viable option for the clinician because it restores esthetic harmony. The patient was very pleased with the new laminate veneers.

Key words: Dental esthetic, dental laminate, veneers

INTRODUCTION

Porcelain laminate veneers have gained popularity^[1] and are now applied in daily practice. Their esthetics, durability, and biocompatibility have made them a viable option for the treatment of anterior teeth.^[2] Advances in materials such as glass ceramic, adhesive systems, and resin cement have allowed restorative dentistry to refocus on minimally invasive procedures.^[3]

The presence of diastema or a malformed shape of the anterior teeth can be esthetically unsatisfactory, and the use of minimally invasive preparation-free porcelain veneers or a minimum reduction has become a viable treatment modality when conservative treatment is selected.^[4] The choice of minimal or no tooth preparation is a key factor in the prognosis.^[5]

This is an open access journal, and articles are distributed under the terms of the Creative Commons Attribution-NonCommercial-ShareAlike 4.0 License, which allows others to remix, tweak, and build upon the work non-commercially, as long as appropriate credit is given and the new creations are licensed under the identical terms.

Access this article online	
Quick Response Code: 	Website: www.eurjdent.com

For reprints contact: reprints@medknow.com

How to cite this article: Melo Sá TC, Figueiredo de Carvalho MF, M. de Sá JC, Magalhães CS, Moreira AN, Yamauti M. Esthetic rehabilitation of anterior teeth with different thicknesses of porcelain laminate veneers: An 8-year follow-up clinical evaluation. *Eur J Dent* 2018;12:590-3.
DOI: 10.4103/ejd.ejd_241_17

No-Prep Rehabilitation of Fractured Maxillary Incisors with Partial Veneers

MIRCO VADINI, DDS, PhD*, MAURIZIO D'AMARIO, DDS, PhD†, FRANCESCO DE ANGELIS, DDS, PhD*, ANTONELLO FALCO, DDS, PhD‡, CAMILLO D'ARCANGELO, DDS§

ABSTRACT

Objective: Therapeutic options for dental trauma depend on the injuries' features. For patients with uncomplicated tooth fractures, adhesive materials and composite partial veneers may be a therapeutic solution that completely preserves healthy tooth structure.

Clinical considerations: An ultra-conservative approach, using indirect composite partial veneers to restore fractured anterior teeth is described in these case reports.

Conclusion: Despite the position of the finish line in the middle of the clinical crown, this solution offers functional and esthetic outcomes using an indirect composite technique, and appears to be a suitable alternative to direct composite restorations or less conservative indirect veneers.

CLINICAL SIGNIFICANCE

Indirect composite partial veneers present considerable advantages, such as ultra-minimally invasive properties and excellent esthetic appearances. The success seems to depend on a combination of sound adhesive principles, adequate design of the restoration, laboratory experience, and cementation techniques. (*J Esthet Restor Dent* 28:351–358, 2016)

INTRODUCTION

Dental trauma to frontal teeth is relatively usual among children and teenagers.¹ When anterior region is involved, it is crucial to satisfy esthetic requirements, since a pleasant smile seems to play a primary psychosocial role in children and teenagers' life and relationships.² The treatment of choice for traumatic fractures depends on several factors such as the extent of the injury, the age of the patient, and the presence of tooth fragments. If complete dental fragment is available, and if it is well-preserved, immediate reattachment may be possible.^{3,4} When the fragment is

not obtainable, a restorative procedure is required to recreate dental functional and esthetic integrity. Special care is necessary to preserve the residual dental structure and choose less invasive treatment. New adhesive materials such as all-ceramic systems and composite resins have increased treatment possibilities and esthetic results may be achieved with metal-free prosthetic materials too.^{5,6} The preparation's design required for adhesive restorations is different from traditional preparations. In particular, non-adhesive restorations required preparation designs facilitating so a mechanical retention of the reconstruction. Bonded restorations do not require extensive preparation, so

*Research Associate, Unit of Restorative Dentistry, Department of Oral Science, Nano and Biotechnology, "G. D'Annunzio" University of Chieti, Italy

†Research Associate, Division of Restorative Dentistry—Oral Pathology, Department of Life, Health and Environmental Sciences—University of L'Aquila, L'Aquila, Italy

‡Private Practitioner, Pescara, Italy

§Associate Professor and Head, Unit of Restorative Dentistry, Department of Oral Science, Nano and Biotechnology, "G. D'Annunzio" University of Chieti, Italy

The Contact Lens Effect: Enhancing Porcelain Veneer Esthetics

DANIEL MATERDOMINI, CDT*
MARK J. FRIEDMAN, DDS[†]

Porcelain veneer restorations have enjoyed an ever-expanding role in restorative dentistry. They are often used for elective dental esthetics because of the conservative nature of the procedure. Veneers satisfy many of the same restorative objectives as conventional crown techniques, but with fewer clinical risks and complications. The interface between the periodontal tissues and the margin of the restoration is where veneers have one of the greatest advantages over crowns.

When conventional anterior crowns are designed, esthetics dictate that, in most instances, the crown margins terminate at an intrasulcular location. Although this may enhance frictional retention, most often the motivation is esthetic.¹ Many metal ceramic and all-ceramic crowns are replaced for no other reason than to reposition the margins to an intrasulcular location. Over time, tissue migration can again reveal these margins, no matter how carefully the crowns were originally designed.^{2,3} Some tissue migration around crown margins in a thin periodontium is considered to be a normal aging process, while other instances can be clearly associated

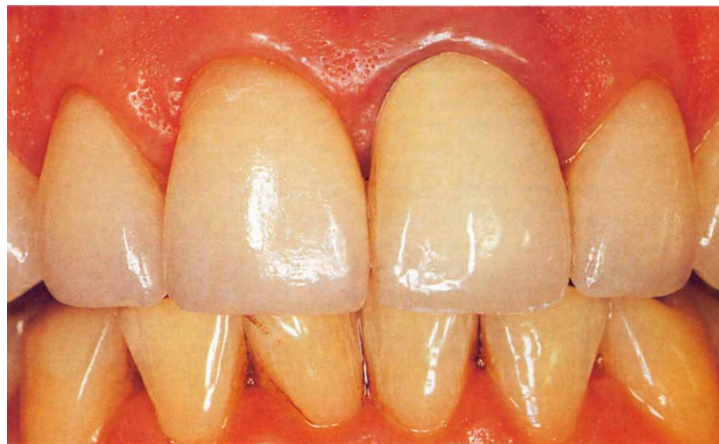

Figure 1. 35-year-old male with five porcelain veneers on the maxillary anterior teeth. A porcelain and gold crown on the maxillary right central incisor has an intrasulcular margin while the porcelain veneers have supragingival margin placement. The iatrogenic periodontal reaction associated with the porcelain and gold crown is self-evident.

with an iatrogenic etiology. Therefore, the repositioning of a crown margin may have limited esthetic longevity, depending on the tissue type: thin and scalloped or thick and flat. The inevitability of soft tissue migration cannot be accurately predicted or eliminated and the risk to the biological homeostasis cannot be avoided. Factors such as biomaterial compatibility, emergence profile, periodontal tissue type, marginal seal, maintenance of biologic width, and host resistance

all contribute to the success or failure of maintaining an intrasulcular restorative margin (Figure 1).⁴ Therefore, crown replacement for esthetically unacceptable facial gingival margins may only be a temporary solution to a complex and often elusive problem. However, unlike a crown which measures 1 to 1.5 mm in thickness, a porcelain veneer imparts a completely different set of optical characteristics when bonded to the tooth.

*Owner of dental studio, Woodland Hills, California

[†]Associate Professor, University of Southern California School of Dentistry, Los Angeles; Private Practice, Encino, California

Establishing a Classification System and Criteria for Veneer Preparations

Brian LeSage, DDS

Abstract: The concept of no- or minimal-preparation veneers is more than 25 years old, yet there is no classification system categorizing the extent of preparation for different veneer treatments. The lack of veneer preparation classifications creates misunderstanding and miscommunication with patients and within the dental profession. Such a system could be indicated in various clinical scenarios and would benefit dentists and patients, providing a guide for conservatively preparing and placing veneers. A classification system is proposed to divide preparation and veneering into reduction—referred to as space requirement, working thickness, or material room—volume of enamel remaining, and percentage of dentin exposed. Using this type of metric provides an accurate measurement system to quantify tooth structure removal, with preferably no reduction, on a case-by-case basis, dissolve uncertainty, and aid with multiple aspects of treatment planning and communication.

LEARNING OBJECTIVES

- discuss the advantages of no-preparation and minimal-preparation veneers
- understand why there is a need for a classification system to categorize the extent of preparation for different types of veneer treatment
- describe factors affecting tooth preparation for esthetic restorations

Nonmaleficence is often discussed and debated in healthcare.¹ No longer is it acceptable to over-prepare teeth for convenience or lack of understanding of alternative treatments. Minimally invasive dentistry is not merely a simple obligation, but a professional duty.¹ The media-inspired preoccupation with looking and feeling younger obligates healthcare providers to balance ethics with literature-based information and clinical experiences to meet patient demands.² Clinical evidence is needed to provide the standard of care required to comply with and support nonmaleficence.^{1,2}

The concept of no-preparation or minimal-preparation veneers is more than 25 years old, yet there is no classification system categorizing the extent of preparation for different veneer treatments.² Such a system could be indicated in various clinical scenarios and benefit dentists and patients, guiding conservative veneer preparation and placement.²

Interest in conservative treatments has increased significantly since veneering was introduced as an additive technique in the 1980s as an alternative to full-coverage crowns.^{3,4} Placed with little to no preparation, veneers were bonded directly to

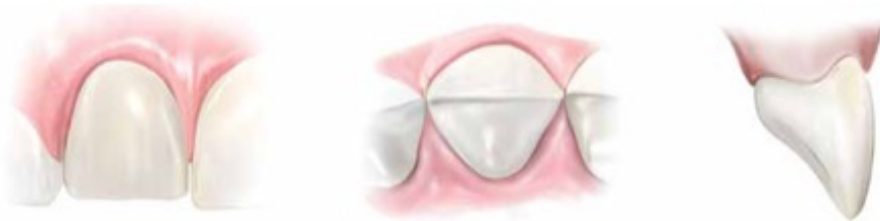

Fig 1.

Fig 1. Illustrations demonstrating Class I veneer preparations requiring little to no tooth structure removal. Facial reduction allowing for 95% to 100% of the enamel remaining, and no dentin should be exposed.

Minimum Thickness Anterior Porcelain Restorations

Gary M. Radz, DDS^{a,b,*}

KEYWORDS

- Porcelain laminate veneers • Dental ceramics
- Minimum thickness anterior restorations
- Porcelain restorations

The treatment of healthy but unesthetic teeth has always presented a challenge for the dental practitioner. The introduction of the acid-etch technique by Buonocore¹ and the development of composite resin by Bowen² expanded the options for treatment of healthy teeth that were of improper shape, deficient in size, or unesthetic in color. These initial discoveries followed by the work of many others brought to light the possibility of enhancing teeth with porcelain laminate veneers (PLVs).

Since the early 1980s, the development and application of porcelain bonded to tooth restoration using a PLV has enjoyed widespread enthusiasm and success and has now become a widely accepted and popular procedure.

PLVs provide the dentist and the patient with an opportunity to enhance the patient's smile in a minimally to virtually noninvasive manner. Today's PLV demonstrates excellent clinical performance and as materials and techniques have evolved, the PLV has become one of the most predictable, most esthetic, and least invasive modalities of treatment. This article explores the latest porcelain materials and their use in minimum thickness restoration.

HISTORY

The evolution and development of adhesive technology over the past 50 years has provided the foundation for today's veneering techniques. The combination of Buonocore's acid etch research¹ and Bowen's composite resin findings² had made possible the technology that allows for the bonding of composite resin to tooth structure in a predictable manner.

In 1928, C.L. Pincus³ introduced the "Hollywood Veneer." This veneer was not dissimilar from today's porcelain veneers, except that they were not etched, but rather held to place with denture adhesive. Obviously, retention was a significant issue and

^a Private Practice, 999 18th Street, #1300 Denver, CO 80202, USA

^b University of Colorado School of Dental Medicine, 10365 East 17th Avenue, Aurora, CO, USA

* Private Practice, 999 18th Street, #1300 Denver, CO 80202.

E-mail address: radzdds@aol.com

**The One-step No-prep Approach for Full-mouth Rehabilitation of Worn Dentition
using PICN CAD-CAM Restorations: 2-yr Results of a Prospective Clinical Study**

Short title: The One-step No-prep Approach for Full-mouth Rehabilitation of Worn Dentition.

J Oudkerk ^{a,b}, M Eldafrawy ^a, S Bekaert ^{a,b}, C Grenade ^{a,b}, A Vanheusden ^{a,b}, A Mainjot ^{a,b*}
a.mainjot@chuliege.be

^a Dental Biomaterials Research Unit (d-BRU), University of Liège (ULiège), 45 Quai G. Kurth, Liège, 4020, Belgium.

^b Department of Fixed Prosthodontics, Institute of Dentistry, University of Liège Hospital (CHU), 45 Quai G. Kurth, Liège, 4020, Belgium.

***Corresponding author:** Amélie Mainjot, d-BRU, 45 Quai G. Kurth, Liege, 4020, Belgium ,
phone number: + 32 496 95 30 30

Abstract

Objectives: To prospectively evaluate the One-step No-prep treatment of full mouth-worn dentition, a minimally invasive and multidisciplinary approach using PICN CAD-CAM composite restorations without provisional phase.

Methods: Seven patients (n=192 restorations) with severe tooth wear were included. Patient data were recorded, and an occlusal analysis and a tissue-guided wax-up were realized. After replacement of old fillings, no-prep Vita Enamic restorations (posterior restorations and palatal veneers) were bonded within 24 hours. Direct composites were performed to mask the buccal joint on anterior teeth. Maxillo-facial physiotherapy was performed. Restorations were evaluated following World Dental Federation criteria. Treatment influence on Oral-Health-Impact-Profile-49 (OHIP-49) score was assessed.

CASE REPORT



Microveneers and digital smile designer: Planning for a patient with bruxism: A 1-year follow-up

Adriana Cristina Zavanelli¹, dos Santos Neto Otavio Marino², Moraes Dálete Samylle Ferreira¹, de Alexande Rodrigo Sversut³, Zavanelli Ricardo Alexandre⁴, Mazaro José Vitor Quinelli¹

¹Department of Dental Materials and Prosthodontics, Aracatuba Dental School, Sao Paulo State University, Aracatuba, Brazil, South America, ²Department of Dental Materials and Prosthodontics, Ribeirão Preto Dental School, University of São Paulo, Aracatuba, Brazil, South America, ³Department of Restorative Dentistry, Aracatuba Dental School, Sao Paulo State University, Aracatuba, Brazil, South America, ⁴Department of Oral Rehabilitation, Dental School, Federal University of Goiás, Goiânia, Goiás, Brazil, South America

Keywords:

Dental veneers, digital planning, esthetics, operative dentistry, temporomandibular joint dysfunction syndrome

Correspondence:

Adriana Cristina Zavanelli, Department of Dental Materials and Prosthodontics, Aracatuba Dental School, Sao Paulo State University, 1193, José Bonifácio, Aracatuba, São Paulo, 16015-050, Brazil.
Tel: +55-18-3636-3200.
E-mail: zavanelliac@foa.unesp.br

Received: 02 March 2019;

Accepted: 29 April 2019

doi: 10.15713/ins.jcri.269

Abstract

The present case report describes the use of digital smile design for a clinical trial execution, involving periodontal and restorative procedures and preservation with microveneers. This approach allows for more enamel preservation and, as a consequence, more predictable bonding, biomechanics, and esthetics. Such results improve harmonic esthetic appearance based on predictable procedures. At the end of the treatment, a stabilizing plate was installed for the protection of the microveneers and the elements. The patient was very satisfied with the new smile, as the treatment considered personal wishes regarding the shape, size, alignment, and contour, also considering the control of bruxism with the use of a stabilizing plate.

Introduction

The digital smile design or digital smile designer (DSD) is a tool to plan a virtual smile. The planning uses digital photographs and patient diagnostic data, coupled with scientific, biological, esthetic, and occlusal principles, to create an esthetically pleasing smile.^[1]

The design of the new smile is virtually built, based on the intra- and extra-oral photographic protocol at various angles, clinical and radiographic examination, and a complete facial evaluation. The patient's necessities should be considered so that the treatment represents your personal requires, improving the professional patient relationship, the planning and presentation of the case to the patient, giving the results more predictable.^[2]

The clinical evaluation should observe the arrangement, alignment, contour, shape, size, color, and texture of the dental elements. The radiographic examination and the assessment of the temporomandibular joint (TMJ) are important complementary exams for the diagnosis and planning in oral rehabilitation.^[3,4]

The esthetic checklist involves the facial evaluation. The macroesthetic elements^[5-8] (face, smile, periodontium, shape, and alignment of dental arches) and microesthetic elements^[9] (shape, alignment, color, and texture of each individual tooth) are considered. The professional should be attentive of extracting sufficient information from the patient, as the psychological profile can influence the expected final result.^[2,10]

The use of DSD allows a comparison of the previous photos with the final result, showing the great difference in esthetics, and giving even more satisfaction for the patient to see was proposed to him and how it has been achieved. The case can be saved, and if patient authorization is given, the treatment can be presented as an example in consultations with other clients seeking esthetic restoration.^[2,10]

The test drive of the virtual project materializes in the esthetic test. The mock-up reproduces the waxing with bisacrylic resin and simulates the esthetic. The functional result could act as a surgical guide to correct the esthetics rose by periodontal

Case Report

Minimally Invasive Laminate Veneers: Clinical Aspects in Treatment Planning and Cementation Procedures

R. K. Morita,¹ M. F. Hayashida,² Y. M. Pupo,³ G. Berger,³
R. D. Reggiani,⁴ and E. A. G. Betiol³

¹Graduate Pontifical Catholic University of Parana, Curitiba, PR, Brazil

²Department of Dentistry, School of Dentistry, University Tuiuti of Parana, Curitiba, PR, Brazil

³Department of Restorative Dentistry, Federal University of Parana, Curitiba, PR, Brazil

⁴Graduate Federal University of Parana, Curitiba, PR, Brazil

Correspondence should be addressed to Y. M. Pupo; yasminemendes@hotmail.com

Received 23 August 2016; Accepted 17 November 2016

Academic Editor: Mine Dündar

Copyright © 2016 R. K. Morita et al. This is an open access article distributed under the Creative Commons Attribution License, which permits unrestricted use, distribution, and reproduction in any medium, provided the original work is properly cited.

When a definitive aesthetic treatment is determined, it is crucial to grant the patient's wish with the necessary dental treatment. Thus, conservative treatments that are the solution to aesthetic problems involving morphologic modifications and provide the result that the patient expects should always be the first therapeutic option. In this context, ceramic laminate veneers, also known as "contact lens," are capable of providing an extremely faithful reproduction of the natural teeth with great color stability and periodontal biocompatibility. Minimal or no preparation veneers are heavily advertised as the answer to our patients' cosmetic needs, which they can be if they are used correctly in the appropriate case. This report is about ultraconservative restorations to achieve functional and aesthetic rehabilitation through treatment planning. Thus, clinicians should be aware that the preparation for laminate veneers remains within enamel, to ensure the bond strength and avoid or minimize the occurrence of postoperative sensitivity.

1. Introduction

One of patients' greatest desires when seeking dental treatment is the aesthetic transformation of their smiles to include healthy and harmonious dentition. Because of this, conservative treatments that are able to modify the shape, size, and color of the teeth and that provide the result that the patient expects should always be the first therapeutic option [1–3].

Contrary to what many clinicians think, the concept of ceramic laminates without tooth surface wear is not new. Historically, during the 1930s, a California dentist Charles Leland Pincus [4] worked in the US film industry; he had the difficult and privileged task of aesthetically improving the smiles of stars such as Shirley Temple, Bob Hope, Montgomery Clift, Elizabeth Taylor, Barbara Stanwyck, Fred Astaire, James Dean, Walt Disney, Judy Garland, and many others. Pincus used thin ceramic veneers with an adhesive aid for the temporary fixation of full dentures. However, due to a lack of appropriate cement, the procedure lasted only a few hours.

During the 1980s, after the development of techniques for adhesive cementation, ultrathin laminates were relaunched. However, at the time, the practice did not spread as quickly as expected, due mainly to professionals' fears regarding the strength of the very thin porcelain veneers in resisting masticatory forces [5]. Due to increasing aesthetic demand and the possibility of joining laminated ceramic to the tooth structure (particularly enamel), a new concept was introduced: minimally invasive restorative dentistry, which causes little damage to dental structures [2].

In this context, laminate veneer, also known as contact lenses, emerged. This extremely aesthetic solution uses nothing more than thin ceramic fragments but presents excellent optical properties. It is considered one of the most conservative treatments for oral rehabilitation, as it requires minimal or no tooth preparation [6, 7]. With thicknesses ranging from 0.2 to 0.5 mm, ceramic laminate is capable of providing an extremely faithful reproduction of the natural teeth with great color stability [5]. Laminate veneer also offers

Case Report

Esthetic Rehabilitation of the Smile with No-Prep Porcelain Laminates and Partial Veneers

Arcelino Farias-Neto,¹ Edna Maria da Cunha Ferreira Gomes,¹ Alfonso Sánchez-Ayala,² Alejandro Sánchez-Ayala,³ and Larissa Soares Reis Vilanova⁴

¹Department of Dentistry, Health School, Potiguar University, Laureate International Universities, Avenida Senador Salgado Filho, No. 1610, 59056-000 Natal, RN, Brazil

²Department of Dentistry, State University of Ponta Grossa, Avenida General Carlos Cavalcanti, No. 4748, 84030-900 Ponta Grossa, PR, Brazil

³Department of Dentistry, University of San Martín de Porres, Jr. Las Calandrias 151-291, Lima 43, Peru

⁴Department of Oral Health, Federal University of Goiás, Primeira Avenida, s/n, 74605-020 Goiânia, GO, Brazil

Correspondence should be addressed to Arcelino Farias-Neto; a.fariasneto@yahoo.com.br

Received 5 August 2015; Revised 29 September 2015; Accepted 29 September 2015

Academic Editor: Mine Dündar

Copyright © 2015 Arcelino Farias-Neto et al. This is an open access article distributed under the Creative Commons Attribution License, which permits unrestricted use, distribution, and reproduction in any medium, provided the original work is properly cited.

Rehabilitation of patients with anterior conoid teeth may present a challenge for the clinician, especially when trying to mimic the nature with composite resins. This clinical report exemplifies how a patient with conoid upper lateral incisors was rehabilitated with minimally invasive adhesive restorations. Following diagnostic wax-up and cosmetic mock-up, no-prep veneers and ceramic fragments (partial veneers) were constructed with feldspathic porcelain. This restorative material presents excellent reproduction of the optical properties of the dental structure, especially at minimal thicknesses. In this paper, the details about the treatment are described. A very pleasing outcome was achieved, confirming that minimally invasive adhesive restorations are an excellent option for situations in which the dental elements are healthy, and can be modified exclusively by adding material and the patient does not want to suffer any wear on the teeth.

1. Introduction

Nowadays, cosmetic needs are of fundamental importance to much of society. Among the available esthetic restorative materials, professionals have options ranging from composite resins to ceramics. For a long time, the material of choice for cosmetic and conservative procedures was composite resin. However, the low durability of this material leads to esthetic damage due to color instability. In addition, its organic matrix degrades and it absorbs water; therefore, the material needs constant maintenance and polishing to prolong the duration of its useful life. Porcelain greatly mimics the natural structure of dental elements and is an excellent option to avoid the various deficiencies of composite resin [1]. When properly made in accordance with a precise clinical protocol, porcelain restorations have a long clinical life. The material has several important characteristics, including physicochemical stability, excellent biological compatibility, sufficient resistance

to compression and abrasion, excellent reproduction of the optical properties of the dental structure, adherence to the cement agent and dental substrates, and color stability [2].

The idea behind minimally invasive cosmetic dentistry is that the clinician should choose the most conservative method possible, thereby avoiding unnecessary wear and tear on the dental structure, while restoring function and appearance to the patient. The development of minimally invasive dentistry was only possible thanks to technological advances in ceramic systems and the development of the adhesive cementation technique. Initially, dentists cemented 0.5 mm thick laminate veneers to an unprepared dental surface. The material used was feldspathic ceramic, which has good clinical and laboratory sensitivity, especially at minimal thicknesses. However, gum inflammation was observed over time after cementation because of the overcontour created by these restorations. Therefore, dentists opted to limit tooth preparations to the space required for these restorations, so

Advances in dental veneers: materials, applications, and techniques

Núbia Pavesi Pini¹
Flávio Henrique Baggio Aguiar¹
Débora Alves Nunes Leite Lima¹
José Roberto Lovadino¹
Raquel Sano Suga Terada²
Renata Corrêa Pascotto²

¹Area of Restorative Dentistry, Piracicaba Dental School, State University of Campinas – FOP/Unicamp – Piracicaba, São Paulo,
²Area of Restorative Dentistry, State University of Maringá – UEM – Maringá, Paraná, Brazil

Correspondence: Renata Corrêa Pascotto
State University of Maringá – UEM,
Department of Dentistry, Mandacaru
Avenue – 1550 – 508, Paraná, Brazil
Tel +55 44 3011 9051
Fax +55 44 3011 9052
Email renatapascotto@gmail.com

Abstract: Laminate veneers are a conservative treatment of unaesthetic anterior teeth. The continued development of dental ceramics offers clinicians many options for creating highly aesthetic and functional porcelain veneers. This evolution of materials, ceramics, and adhesive systems permits improvement of the aesthetic of the smile and the self-esteem of the patient. Clinicians should understand the latest ceramic materials in order to be able to recommend them and their applications and techniques, and to ensure the success of the clinical case. The current literature was reviewed to search for the most important parameters determining the long-term success, correct application, and clinical limitations of porcelain veneers.

Keywords: dental ceramic, porcelain veneers, aesthetic treatment

Introduction

Restorative aesthetic dentistry should be practiced as conservatively as possible. Currently, the use of adhesive technologies makes it possible to preserve as much tooth structure as is feasible while satisfying the patient's restorative needs and aesthetic desires. With indirect restorations, clinicians should choose a material and technique that allows the most conservative treatment; satisfies the patient's aesthetic, structural, and biologic requirements; and has the mechanical requirements to provide clinical durability.¹

Based on their strength, longevity, conservative nature, biocompatibility, and aesthetics, veneers have been considered one of the most viable treatment modalities since their introduction in 1983.² Aesthetic veneers in ceramic materials demonstrate excellent clinical performance and, as materials and techniques have evolved, veneers have become one of the most predictable, most aesthetic, and least invasive modalities of treatment.³ For this reason, both materials and techniques provide the dentist and patient an opportunity to enhance the patient's smile in a minimally invasive to virtually noninvasive way.

Initially used to treat various kinds of tooth discoloration, porcelain laminate veneers have been increasingly replaced by more conservative therapeutic modalities, such as bleaching and enamel microabrasion.⁴ However, this evolution has not led to a decrease in indications for veneers, as materials and techniques continue to be developed. Ceramic veneers are considered the ultimate option for a conservative aesthetic approach because they leave nearly all of the enamel intact before the veneer is placed.⁵

CLINICAL REPORT

Interdisciplinary approach using composite resin and ceramic veneers to manage an esthetic challenge

Heitor Cosenza, DDS, Msc,^a Saulo Pamato, DDS, MSc, PhD,^b Alef Vermudt, DDS,^c and Jefferson R. Pereira, PhD^d

Different techniques have been described for the correction of diastemas.¹⁻⁴ When planned in an appropriate manner, orthodontic therapy may be successful. However, with excessive space, orthodontic treatment should be combined with restorative procedures to achieve the optimal width-to-length tooth proportions.⁵⁻⁸

Composite resins provide an outstanding option for conservative treatments.⁹⁻¹¹ However, ceramic materials may be required, as when patients ingest drinks and food with high staining potential.¹² Ceramic veneers can be a conservative and long-lasting option.⁶⁻¹³⁻¹⁷ Regardless of the restorative material, optimal esthetics in balance with adjacent teeth and gingiva are essential.¹⁸⁻²⁰

This clinical report demonstrates an interdisciplinary approach to manage the gingival tissues and a diastema. Additionally, multiple restorative materials were used for conservative treatment with enhanced esthetics and longevity.

CLINICAL REPORT

A 34-year-old woman presented to a private dental office complaining about the appearance of her smile and gingival inflammation (Fig. 1). Her general health was good with no systemic or local disease. She had diastemas among the maxillary central incisors and among the maxillary central and lateral incisors that had been restored with direct composite resin. Her periodontal

ABSTRACT

This clinical report describes the management of an esthetic challenge in an interdisciplinary manner addressing both the soft tissue and the anterior dentition. Different restorative materials were used in an esthetic and conservative manner to provide a pleasing smile. A minimally invasive approach was adopted to manage the anterior esthetics problems, including a maxillary diastema and inadequate width-to-length tooth proportions. (J Prosthet Dent 2020;■■■■)

tissues were inflamed, but no deep probing depths were detected. After explaining possible treatments, including orthodontic treatment, restoration with ceramic veneers, restoration with composite resin veneers, surgical gingival recontouring, and a combination of these treatments, the patient chose ceramic veneers and surgical gingival recontouring of the maxillary lateral incisors. This treatment was complemented by increasing the length of the lateral incisors with composite resin restorations.²¹

A diagnostic waxing was performed for diastema closure after impression making (Express XT; 3M ESPE), and a silicone index was made for trial restorations. After the trial restorations, some esthetic adjustments were necessary, and after that, the new smile profile was defined. New silicone indices were made, and the new esthetic parameters were determined intraorally as seen in Figure 2.

Following gingivoplasty, passive tooth eruption was achieved, and part of the enamel to be exposed was exposed. The biological width was redefined after correcting the gingival contour around the maxillary lateral incisors after probing. The width-to-length tooth proportions were optimized. The surgery was undertaken with a surgical chisel (Cinzel Ochsenbein no. 1; Quinelat) with a flapless technique (Fig. 3), avoiding root

^aPrivate practice, São José do Rio Preto, Brazil.

^bProfessor, Department of Prosthodontics, Avantis University Center (UniAvan), Balneário Camboriú, Brazil.

^cUndergraduate student, Department of Restorative Dentistry, University of Southern Santa Catarina (UNISUL), Tubarão, Brazil.

^dProfessor, Department of Prosthodontics, Avantis University Center (UniAvan), Balneário Camboriú, Brazil.



ESTHETIC, OCCLUSAL, AND PERIODONTAL REHABILITATION OF ANTERIOR TEETH WITH MINIMUM THICKNESS PORCELAIN LAMINATE VENEERS

Leonardo Fernandes da Cunha, DDS, MSc, PhD,^a

Lorena Oliveira Pedroche, DDS, MSc,^b

Carla Castiglia Gonzaga, DDS, PhD,^c and

Adilson Yoshio Furuse, DDS, MSc, PhD^d

Positivo University, Curitiba, Brazil; Bauru School of Dentistry, University of São Paulo, Brazil

Ceramic veneers of minimum thickness provide satisfactory esthetic outcomes while preserving the dental structure. Dental ceramics can both improve the esthetic appearance and reestablish the strength and function of teeth. In worn anterior teeth, functional surfaces, for example, anterior and lateral guidance, can be restored effectively. The characteristics of dental ceramics, such as color stability and mechanical and optical properties, make this material a good choice for indirect restorations, especially when optimum function and esthetics are required. This clinical report presents an occlusal, periodontal, and restorative solution with minimum thickness glass ceramic veneers for worn anterior teeth with multiple diastemas. (J Prosthet Dent 2014;112:1315-1318)

With the improvement of dental ceramics and adhesive systems, minimum thickness laminate veneers are a useful treatment option. They may be indicated when there is adequate remaining sound dental structure, such as with patients with worn anterior teeth and/or diastemas. In these situations, although little or no tooth preparation is required, the longevity of the adhesion to enamel^{1,2} and the mechanical properties, biocompatibility, and esthetics of the ceramics are well documented.³ The rehabilitation should include anterior and lateral guidance. Before the placement of bonded definitive restorations, incisal lengthening should be considered. The trial restoration technique is recommended to diagnose, communicate, and evaluate the required space for minimally invasive veneers and to evaluate the restoration of the anterior guidance.^{4,5} In such an analysis, the dentist should evaluate both static and dynamic occlusal relationships and consider

how well the patient adapts to the current occlusal pattern and whether there is any discrepancy from the ideal occlusion that should be treated.

Each time esthetic procedures are considered, gingival health should also be evaluated. Initially, dental prophylaxis and periodontal treatment, including scaling and root planing, should be performed. Indirect restorations such as ceramic veneers maintain a proper emergence profile and adequate gingival margins, and lower the incidence of plaque retention, thus contributing to the maintenance of periodontal health.⁶ Currently, for esthetic veneers, leucite-reinforced and lithium disilicate ceramics are commonly recommended because of their optical properties and their ability to be acid etched.⁷ Both are fabricated with the heat-pressed technique and can be used with characterization or as core materials with subsequent veneering with feldspathic ceramics.⁸⁻¹⁰ These aspects can help dentists and

laboratory technicians achieve higher clinical success rates in the restoration of form, color, and opalescence. This article describes minimum thickness glass ceramic laminate veneers as part of a functional and/or esthetic treatment to improve the occlusal, periodontal, and esthetic situation of a patient with a worn anterior dentition.

CLINICAL REPORT

A 25-year-old woman was referred for dental esthetic treatment because she was dissatisfied with the composite resin restorations on her maxillary anterior incisors. Diastemas and composite resin restorations associated with marginal inflammation, excessive gingival contours, and placement of subgingival margins were observed (Fig. 1). The composite resin restorations also were not maintaining adequate lateral guidance, with group function occlusion occurring at the canine and lateral incisor (Fig. 2). After

^aPrivate practice, Hospital Odontológico Jório da Escóssia, Fortaleza, Ceará, Brazil.

^bGraduate student, Master of Science Program in Clinical Dentistry, Positivo University.

^cProfessor, Graduate Program of Dentistry, Positivo University.

^dProfessor, Department of Operative Dentistry, Endodontics, and Dental Materials, Bauru School of Dentistry, University of São Paulo.



Two-year Follow-up of Ceramic Veneers and a Full Crown Treated With Self-etching Ceramic Primer: A Case Report

ROA Souza • NR da Silva • LM de Miranda • GM de Araújo • DMD Moura • HAM Barbosa

Clinical Relevance

The Monobond Etch & Prime seems to be an efficient option for adhesive cementation of ultrathin veneers and full crown ceramic with good properties after two years of clinical follow-up.

SUMMARY

The use of the self-etching ceramic primer combines the stages of acid conditioning and silanization in cementation procedures of ceramic restorations. The protocol is a simpler and safer alternative to the conventional protocol for surface treatment of silica-based ceramics. This case report describes the steps of an esthetic rehabilitation with ultrathin veneers and full crown based on lithium disilicate treated with a ceramic primer (Monobond Etch & Prime, Ivoclar Vivadent, Schaan,

Liechtenstein). After two years of clinical follow-up, the restorations presented satisfactory esthetic and functional performance, color stability, surface and marginal integrity, and absence of cracks and debonding. More research is needed to investigate the clinical performance and longevity of the ceramic restorations treated with self-etching ceramic primers.

INTRODUCTION

Adhesion is a key factor for the long-term success of ceramic restorations.¹ For certain restoration types, such as ultrathin veneers, retention to the tooth surface depends solely on the micromechanical and

*Rodrigo Othávio Assunção Souza, DDS, MSc, PhD, adjunct professor, Department of Dentistry, Division of Prosthodontics Federal University of Rio Grande do Norte, Natal/RN, Brazil

Nathalia Ramos da Silva, DDS, MSc, PhD student, Department of Dentistry, Division of Prosthodontics Federal University of Rio Grande do Norte, Natal/RN, Brazil

Larissa Mendonça de Miranda, DDS, MSc student, Department of Dentistry, Division of Prosthodontics Federal University of Rio Grande do Norte, Natal/RN, Brazil

Gabriela Monteiro de Araújo, DDS, MSc, PhD student, Department of Dentistry, Division of Prosthodontics Federal University of Rio Grande do Norte, Natal/RN, Brazil

Dayanne Monielle Duarte Moura, DDS, MSc, PhD student, Department of Dentistry, Division of Prosthodontics Federal University of Rio Grande do Norte, Natal/RN, Brazil

Helga Adachi Medeiros Barbosa, DDS, MSc, private clinical, Natal/RN, Brazil

*Corresponding author: Av Salgado Filho, 1787, Lagoa Nova, Natal/RN 59056-000, Brazil; e-mail: rodrigoothavio@gmail.com

<https://doi.org/10.2341/19-090-R>



Comparison of color stability of two laminate veneers cemented to tooth surfaces with and without preparation

Makbule T. Tuncdemir DDS, PhD¹ | Nilgun Gulbahce MD² | Filiz Aykent DDS, PhD³

¹Department of Restorative Dentistry, Faculty of Dentistry, Necmettin Erbakan University, Konya, Turkey

²Department of Prosthodontics, Faculty of Dentistry, Necmettin Erbakan University, Konya, Turkey

³Department of Prosthodontics, Faculty of Dentistry, Yildirim Beyazit University, Ankara, Turkey

Correspondence

Nilgun Gulbahce, MD, Department of Prosthodontics, Faculty of Dentistry, Necmettin Erbakan University, Konya, Turkey. Email: nilgungulbahce345@hotmail.com

Funding information

Necmettin Erbakan University, Scientific Research Section, Grant/Award Number: 181224002

Abstract

Objective: The aim of this study was to determine the effects of preparation vs non-preparation of tooth surfaces and the types of porcelain laminate veneers (PLVs) on color changes after 300 hours of artificially accelerated aging (AAA).

Materials and methods: Forty extracted maxillary central incisors were used. The teeth were divided into four groups ($n = 10$) to evaluate preparation methods and porcelain types: Group A: tooth preparation with IPS e.max computer-assisted design (CAD), group B: tooth preparation with IPS e.max press, group C: nonpreparation with IPS e.max CAD, and group D: nonpreparation with IPS e.max press. Veneers were fabricated and cemented using a dual-polymerized cement. Initial color measurement was performed and repeated after AAA. Color changes were calculated with the CIEDE 2000 (ΔE_{00}) formula. Color differences were analyzed with two-way ANOVA ($P < .05$).

Results: The two-way ANOVA test showed no significant difference among the groups ($P > .05$). The highest color change value was observed in group C, followed by groups B, A, and D.

Conclusion: Preparation of veneers caused more color changes in PLVs than nonpreparation. However, IPS e.max CAD systems for fabrication of nonprepared PLVs increased the color change of the PLVs measured after AAA.

Clinical Significance: The results provide information on the effect of the amount of preparation and the type of porcelain on color change in porcelain laminate veneers. In terms of esthetic dentistry, IPS e.max press and non-prep treatment should be used in the anterior region, where esthetics are important.

KEYWORDS

color stability, IPS e.max CAD, IPS e.max press, nonpreparation, porcelain laminate veneers

1 | INTRODUCTION

Porcelain laminate veneers (PLVs) were first described in the early 1980s.¹ PLVs have been used in functional and esthetic dental rehabilitation with good results.² The clinical technique for PLVs includes bonding very thin restorations to tooth adhesively in order to correct an unesthetic appearance of the anterior teeth, such as treatment of

discolored or malformed teeth and restoration of minimal orthodontics defects.^{3,4}

A review by Burke, focusing on the amount of preparation, concluded that preparations in the dentin adversely affected the survival rate of PLVs and that the ideal porcelain veneer preparation must terminate in the enamel.⁵ No longer is it necessary to remove 1.0 to 1.5 mm of tooth structure to obtain a porcelain restoration with



Contents lists available at ScienceDirect

Japanese Dental Science Review

journal homepage: www.elsevier.com/locate/jdsr

Review Article

Current perspectives on dental adhesion: (1) Dentin adhesion – not there yet

Jorge Perdigão

Professor, University of Minnesota, Department of Restorative Sciences, 515 SE Delaware St, 8–450 Moos Tower, Minneapolis, MN 55455, USA



ARTICLE INFO

Article history:
Received 5 June 2020
Accepted 24 August 2020

ABSTRACT

The essential goal of any adhesive restoration is to achieve a tight and long-lasting adaptation of the restorative material to enamel and dentin. The key challenge for new dental adhesives is to be simultaneously effective on two dental substrates of conflicting nature. Some barriers must be overcome to accomplish this objective. While bonding to enamel by micromechanical interlocking of resin tags within the array of microporosities in acid-etched enamel can be reliably achieved and can effectively seal the restoration margins against leakage, bonding effectively and durably to organic and humid dentin is the most puzzling task in adhesive dentistry.

Much of the research and development of dental adhesives has focused on making the clinical procedure more user-friendly by reducing the number of bottles and/or steps. Although clinicians certainly prefer less complicated and more versatile adhesive materials, there is a trade-off between simplification of dental adhesives and clinical outcomes. Likewise, new materials are launched with claims of being novel and having special properties without much supporting evidence.

This review article discusses dental adhesion acknowledging pioneer work in the field, highlights the substrate as a major challenge to obtain durable adhesive restorations, as well as analyzes the three adhesion strategies and their shortcomings. It also reviews the potential of chemical/ionic dental adhesion, discusses the issue of extensively published laboratory research that does not translate to clinical relevance, and leaves a few thoughts in regard to recent research that may have implications for future adhesive materials.

© 2020 The Author. Published by Elsevier Ltd on behalf of The Japanese Association for Dental Science. This is an open access article under the CC BY-NC-ND license (<http://creativecommons.org/licenses/by-nc-nd/4.0/>).

1. Introduction

Dental adhesion was responsible for a paradigm shift in dentistry (Table 1). Dental adhesives have become one of the most intriguing biomaterials in Health Sciences. Research efforts in the last 20 years have shifted from clinically-proven multi-step dental adhesives to simplified versions that do not perform adequately in laboratory and clinical studies [1,2]. The ideal goals for clinical effectiveness and durability of the restorations have been frequently neglected in favor of fewer number of bottles and quicker application of newer dental adhesives.

Several obstacles must be overcome to accomplish the objective of developing a dental adhesive that bonds effectively to enamel and dentin, and achieves durable restorations that seal the margins and provide some form of resistance to recurrent caries lesions.

The continuous development and frequent introduction of dental adhesives render existing materials outdated within a few years.

E-mail address: perdi001@umn.edu

<https://doi.org/10.1016/j.jdsr.2020.08.004>

1882-7616/© 2020 The Author. Published by Elsevier Ltd on behalf of The Japanese Association for Dental Science. This is an open access article under the CC BY-NC-ND license (<http://creativecommons.org/licenses/by-nc-nd/4.0/>).

When clinical studies are completed, often a new version of the same material has already been made available on the market. In fact, dental adhesives can be launched without proof of clinical efficacy, as the FDA usually reviews “the Section 510(k) premarket notification of intent to market the device and determines the device to be substantially equivalent to legally marketed predicate devices” used for the same indications [3–5].

It is extremely difficult for practicing dentists to keep updated as so many dental adhesives are constantly launched on the market and updated or relaunched within short periods of time. In addition, dentists do not have access to the latest evidence-based information. As a result, dentists rely on the information provided by the industry representatives or information disseminated in continuing education courses and dental meetings, often without solid evidence to support the claims [6].

The objective of this review article is to summarize the current evidence on dental adhesion, from the challenging substrate to the latest trends, many of which do not extrapolate to sound evidence pertinent to clinical practice.

Ultrathin Monolithic Zirconia Veneers: Reality or Future? Report of a Clinical Case and One-year Follow-up

R Souza • F Barbosa • G Araújo • E Miyashita • MA Bottino • R Melo • Y Zhang

Clinical Relevance

Translucent zirconia has become esthetic, make it a viable alternative for the manufacturing of ultrathin veneers.

SUMMARY

Yttria-stabilized polycrystalline zirconia ceramics have greatly advanced over the past few years. High-translucent zirconia is a newly introduced ceramic that affords high strength and esthetics and that has significantly increased the clinical indications of monolithic zirconia restorations. Thus, the purpose of this case report was to evaluate the performance of ultrathin monolithic zirconia veneers adhesively luted to enamel

surfaces after minimally invasive preparations; in addition, we aimed at presenting a clinical protocol for zirconia surface treatment in order to promote bonding effectiveness to resin cement. This type of restoration presented very acceptable esthetic results and decreased the risk of fracturing the veneer during try-in and clinical use. The results were still satisfactory after one-year follow-up. However, randomized, prospective, controlled clinical trials are required to determine the long-term clinical durability of this treatment.

*Rodrigo Othávio Assunção Souza, adjunct professor, Federal University of Rio Grande do Norte (UFRN), Department of Dentistry, Division of Prosthodontics, Natal, Brazil

Fernanda Pinheiro Barbosa, DDS, private clinical, Natal, Brazil

Gabriela Monteiro de Araújo, DDS, MSc, PhD student, Federal University of Rio Grande do Norte (UFRN), Department of Dentistry, Division of Prosthodontics, Natal, Brazil

Eduardo Miyashita, professor, Paulista University (UNIP), Department of Dentistry, São Paulo, Brazil

Marco Antonio Bottino, titular professor, Department of Dental Materials and Prosthodontics, Institute of Science and Technology, Univ Estadual Paulista–UNESP, Sao Jose dos Campos, Brazil

Renata Marques de Melo, researcher, Department of Dental Materials and Prosthodontics, Institute of Science and Technology, Univ Estadual Paulista–UNESP, Jose dos Campos, Brazil

Yu Zhang, New York University College of Dentistry, Department of Biomaterials and Biomimetics, New York, NY, USA

*Corresponding author: Av Salgado Filho, 1787, Lagoa Nova, Natal/RN, 59056-000, Brazil; e-mail: rodrigothavio@gmail.com

DOI: 10.2341/16-350-T



Vanessa González-García

Estudiante 5º Odontología. Universidad Rey Juan Carlos.

Inmaculada González-González

Estudiante 5º Odontología.
Universidad Rey Juan Carlos.

María Cura

Becaria de Docencia e Investigación.
Universidad Rey Juan Carlos.

Dra. Laura Ceballos

Profesora titular Universidad Rey Juan Carlos.

Resistencia adhesiva a la dentina de restauraciones indirectas de composite

Cementadas con cementos resinosos duales y composite precalentado

Artículo ganador del VI Premio Estudiantes de GACETA DENTAL

Resumen

Objetivo

Determinar la resistencia adhesiva de restauraciones de composite cementadas con dos cementos de resina de polimerización dual y composite precalentado a 39°C y 55°C.

Material y métodos

Se obtuvieron superficies planas de dentina media procedentes de 12 terceros molares. Se prepararon doce overlays de resina compuesta Adoro A3 dentina (Ivoclar-Vivadent) de 4mm de alto. Los molares se grabaron con ácido ortofosfórico al 35% y se aplicó el adhesivo Adper Scotchbond 1XT (3M ESPE). Posteriormente se cementaron utilizando los siguientes materiales:

- Grupo 1: cemento de resina dual Calibra (Dentsply).
- Grupo 2: cemento de resina dual Rely X Ultimate (3M ESPE).
- Grupo 3: composite precalentado a 39°C IPS Empress Direct (Ivoclar-Vivadent).
- Grupo 4: con el mismo composite precalentado a 55°C.

Se ejerció una carga de 1 kg. y se fotopolimerizaron 40 segundos desde oclusal con la unidad Bluephase (Ivoclar-Vivadent). Los especímenes se sometieron a un ensayo de microtracción (Instron 3345). El tipo de fallo se evaluó en el estereomicroscopio (Olympus) con una magnificación de 30x y las muestras seleccionadas fueron observadas en el microscopio electrónico de barrido. Los datos fueron analizados estadísticamente mediante el test ANOVA y Student-Newman-Keuls ($p < 0.05$).

Resultados

El cemento de resina dual RelyX Ultimate obtuvo los valores más altos de resistencia adhesiva sin diferencias estadísticamente significativas con los de Calibra. Los especímenes cementados con la resina compuesta IPS Empress Direct precalentada obtuvieron valores significativamente inferiores a los obtenidos con los cementos de resina, siendo los del composite precalentado a 55°C estadísticamente los más bajos.

Conclusiones

La resistencia adhesiva a la dentina de los composites precalentados a 39°C y 55°C es significativamente menor a la obtenida por los cementos resinosos de curado dual.

Introducción

Las restauraciones indirectas de resina compuesta surgen en un intento por superar las deficiencias de una restauración directa de composite, tales como la contracción de polimerización y el grado de conversión (1-3). Las indicaciones clínicas de este tipo de restauraciones se basan en la evaluación clínica de la estructura remanente del diente, las condiciones intraorales y el costo (4,5).

La adhesión entre las restauraciones indirectas de composite y la estructura dentaria supone un gran reto, ya que existen dos interfases diferentes que deben considerarse: por un lado, la establecida entre dentina/esmalte y el cemento de resina y, por otro lado, la existente entre el cemento de resina y la resina compuesta prepolimerizada. La resistencia de



Leonardo Fernandes da Cunha

Rehabilitation of the dominance of maxillary central incisors with refractory porcelain veneers requiring minimal tooth preparation

Leonardo Fernandes da Cunha, DDS, MSc, PhD¹/Carla Castiglia Gonzaga, DDS, PhD¹/Rafaela Saab, DDS²/Amanda Mahammad Mushashe²/ Gisele Maria Correr, DDS, MSc, PhD¹

Central dominance is an important element of an esthetic smile. Color, form, and size have been suggested as tools for assessing the dominance of maxillary teeth. A spectrophotometer can be used to determine the value, hue, and chroma. Correct sizing of restorations according to the central incisor dominance principle improves not only esthetics but also aspects of occlusion, such as anterior guidance. Refractory

porcelain systems can effectively restore the color, shape, emergence profile, and incisal translucency. This report illustrates the esthetic and occlusal rehabilitation of the dominance of maxillary central incisors using fabricated minimal thickness refractory porcelain veneers. (*Quintessence Int* 2015;46:837-841; doi: 10.3290/j.qla.34703)

Key words: color, dental ceramics, dental esthetics, dental occlusion, veneer

The dominance of maxillary central incisors is an important element of an esthetic smile. Color, form, and size, which may be used to assess dominance in the frontal or lateral view of the maxillary central incisors, must be accurately reestablished to result in a pleasant smile.¹

According to this principle, the maxillary central incisors should be the lightest and brightest teeth.² Shades of restorations are matched with those of natural teeth in value, hue, and chroma; these three parameters must be correctly selected and communicated to the laboratory technician. Results obtained with a

shade guide (VITA Toothguide 3D-Master, VITA Zahnfabrik) have been found to match natural teeth more closely than those obtained with conventional guides.^{3,4} The natural tooth color can be recorded using a spectrophotometer from the same manufacturer (VITA Easyshade Compact).

Central incisors with an incorrect size, shape, and proportion result in a less attractive smile.⁵ Correctly sizing restorations according to the central incisors dominance principle improves not only esthetics but also certain aspects of occlusion, such as anterior guidance. Before bonded definitive restorations are placed, incisal lengthening must be designed and tested. The wax-up and mock-up techniques used to fabricate esthetic and functional restorations⁶ can also be used to reestablish the dominance of maxillary central incisors.

Refractory porcelain systems can effectively restore the color and shape of central incisors and provide con-

¹Professor, Graduate Program of Dentistry, Positivo University, Curitiba, Brazil.

²Graduate Student, Graduate Program of Dentistry, Positivo University, Curitiba, Brazil.

Correspondence: Dr Leonardo Fernandes da Cunha, Universidade Positivo, Rua Professor Pedro Viriato Parigot de Souza, 5300, Curitiba - PR, 81280-330, Brazil. Email: cunha_leo@me.com

Direct Composite Resin Veneers in Nonvital Teeth: A Still Viable Alternative to Mask Dark Substrates

CRF Yanikian • F Yanikian • D Sundfeld • RBE Lins • LRM Martins

Clinical Relevance

Direct composite veneers are a viable approach to improve the color and esthetics of darkened anterior teeth. Additionally, composite resin veneers are not negatively affected by dark substrates over time.

SUMMARY

Direct composite resin veneers are a practical esthetic restorative treatment for reestablishing the shape and color of affected anterior teeth. The present clinical case reports aim to describe restorative treatment techniques for nonvital anterior teeth presenting color alter-

ation. The direct composite resin layering technique has proven to be an efficient method for recovering the esthetics of darkened teeth. The direct vs indirect restorative treatments are debated as well. Clinical follow-ups of the presented case reports demonstrate that direct composite resin restorations are not affected by the darkened tooth substrate over time.

*Cristiane Rumi Fujiwara Yanikian, DDS, MDS, PhD student, Department of Restorative Dentistry, Piracicaba School of Dentistry, University of Campinas–UNICAMP, Piracicaba, SP, Brazil

Felipe Yanikian, DDS, private dental practice, Capão Bonito, SP, Brazil

Daniel Sundfeld, DDS, MDS, PhD, professor, Department of Restorative Dentistry and Prosthodontics, Ingá University Center–UNINGÁ, Maringá, PR, Brazil

Rodrigo Barros Esteves Lins, DDS, MDS, PhD student, Department of Restorative Dentistry, Piracicaba School of Dentistry, University of Campinas–UNICAMP, Piracicaba, SP, Brazil

Luis Roberto Marcondes Martins, DDS, MDS, PhD, professor, Department of Restorative Dentistry, Piracicaba School of Dentistry, University of Campinas–UNICAMP, Piracicaba, SP, Brazil

*Corresponding author: 901 Limeira Avenue, 13414-903 Piracicaba, SP, Brazil; e-mail: cristiane@fyodontologia.com.br

DOI: <http://doi.org/10.2341/18-220-T>

INTRODUCTION

After the introduction of dentin bonding agents and further development of resin composites, direct resin composite has become a more conservative treatment for esthetic problems in the anterior dentition. Until the mid to late 1980s, there were few composite based resins available on the market that presented good esthetic characteristics. Only after the introduction of composite systems that provided dentin and enamel shades did the color selection process become easier and direct restorations began to look better and more lifelike.¹

Currently, nanofiller composites are not only time- and cost-effective, but they are also ultimately a high-quality and long-lasting treatment of choice.^{2,3} They present superior strength, excellent physical and optical/color properties, and improved polishing characteristics compared with early macrofills, which allow composite resins to be successfully used

Longevity and failure load of ceramic veneers with different preparation designs after exposure to masticatory simulation

Christian F.J. Stappert, DDS, Dr Med Dent,^a Ummuhan Ozden, DDS, Dr Med Dent,^b Thomas Gerds, PhD,^c and Jorg R. Strub, DDS, Dr Med Dent, PhD^d
New York University College of Dentistry, New York, NY; Albert-Ludwigs University, Freiburg, Germany

Statement of problem. Laminate veneers are widely used in the management of unesthetic anterior teeth. However, limited information is available regarding the influence of preparation design on longevity of ceramic veneers.

Purpose. This study evaluated the influence of preparation design on longevity and failure load of ceramic veneers bonded to human maxillary central incisors after cyclic loading and thermal cycling in a dual-axis masticatory simulator.

Material and methods. Sixty-four caries-free maxillary central incisors were divided into 4 groups (n = 16). The control group remained unprepared (NP). For Group WP, a window preparation was made. Specimens in Group IOP were prepared with an incisal overlap of 2 mm without palatal chamfer. For Group CVP, specimens were prepared with a complete-veneer design of 3-mm incisal reduction and 2-mm palatal extension. Forty-eight IPS Empress 1 ceramic veneers were bonded adhesively with dual-polymerizing composite (Variolink II). All specimens were subjected to cyclic mechanical loading (1.2 million cycles, cycle frequency 1.3 Hz, invariable palatal load 49 N) and thermal cycling (5°C-55°C, dwell time 60 seconds, 5500 cycles) in a masticatory simulator. Failure was defined by bulk fracture of a specimen. Subcritical crack patterns were observed. Surviving specimens were loaded in a universal testing machine until fracture. The failure-load values (N) (1.5 mm/min crosshead speed) were automatically recorded by controlling software. Statistical analysis of data was performed by Kruskal-Wallis analysis of variance ($\alpha=.05$) and pairwise Wilcoxon rank sum tests ($\alpha=.05$).

Results. Three specimens from group NP, 1 specimen each from the WP and CVP groups, and 2 specimens from group IOP fractured during fatigue. After 1.2 million cycles, the highest crack rates were observed for complete veneers and originated in the palatal concavity extending to the facial surface. The median (interquartile range = $x_{.25}$ - $x_{.75}$) failure loads (N) were as follows: NP 713.3 (404.4-777.1), WP 549.5 (477.5-597.7), IOP 695.3 (400.0-804.6), and CVP 519.2 (406.1-732.9). No significant differences in longevity and failure load were demonstrated between natural teeth and teeth restored with ceramic veneers ($P=.555$).

Conclusion. Maxillary teeth restored with the 3 types of IPS Empress 1 veneers showed fracture resistance similar to that of unprepared incisors ($P=.555$). (J Prosthet Dent 2005;94:132-9.)

CLINICAL IMPLICATIONS

Within the limits of this in vitro investigation, the use of adhesively luted IPS Empress 1 veneers prepared according to the 3 different preparation designs demonstrated adequate stabilization of residual tooth structure. Crack pattern analysis showed a higher risk of subcritical crack development when the indenter impact was located on the palatal ceramic surface. Therefore, the palatal contact point position of the antagonist should remain on the natural tooth structure after preparation. In particular, this is important for complete veneer preparations.

The demand for more durable and esthetic anterior dentition has resulted in an increase in the use of porce-

lain veneers during the past decade.^{1,2} With an observation period ranging from 1 month to 15 years, longitudinal evaluations of porcelain veneers have shown excellent results, including a low prevalence of debonding, microleakage, fracture, and caries.¹⁻⁶ In the early use of porcelain laminate veneers, clinicians suggested minimal or no preparation.^{7,8} Currently, tooth preparation is recommended to achieve long-term success,⁹⁻¹¹ maximize esthetics, improve fracture resistance, and maintain soft tissue health.¹² In addition,

^aVisiting Associate Research Professor, Department of Biomaterials and Biomimetics, New York University College of Dentistry; Senior Lecturer, Department of Prosthodontics, Albert-Ludwigs University.

^bResearch Associate, Private practice, Dusseldorf, Germany.

^cStatistician, Department of Prosthodontics and Institute of Medical Biometrics and Medical Informatics, Albert-Ludwigs University.

^dProfessor, Chairman, Department of Prosthodontics, Albert-Ludwigs University.

Low-Risk Dentistry Using Additive-Only ("No-Prep") Porcelain Veneers

Dennis Wells, DDS

ABSTRACT

"No-prep" porcelain veneers have been effectively in use for more than two decades, and the bonding of porcelain to 100% enamel has enjoyed extraordinary success. Today's refined techniques, new and improved materials, and better training in emulating nature have enabled additive-only veneers to rival, or in some cases even exceed, the results of traditionally prepared veneers. In this case presentation, the author uses conservative, additive-only dentistry to enhance a young woman's smile by creating improved anterior esthetics.

A

26-year-old woman reported to the author's office with a desire to improve her smile. Her chief concerns included multiple diastemas present in the anterior, discolored composite bonding on tooth No. 7, and a generalized yellow hue (Figure 1 through Figure 4). She desired her teeth to have more "presence," both in architecture and color.

She stated that her orthodontist struggled to close all of the spaces while she was a teenager, and that she had fixed lingual retainers ever since.

CLINICAL REPORT

Adhesion and optics: The challenges of esthetic oral rehabilitation on varied substrates—Reflections based on a clinical report

Maristela Lobo, DDS, PhD,^a Walleska Feijó Liberato, DDS, MSc,^b Marcos Gabriel Vianna-de-Pinho, DDS, MSc,^c Larissa Maria Cavalcante, DDS, PhD,^d and Luis Felipe J. Schneider, DDS, PhD^e

When one or more teeth are badly discolored, their restoration is problematic because poor appearance affects not only the crown but also the periodontal tissues.^{1,2} For example, a minimum soft-tissue width of 2.0 mm is necessary to mask titanium and replicate the light reflection of the natural dentition.²

Particularly challenging is the selection of the most appropriate material for the restorative procedures and the substrates for the adhesion of the prosthetic components. The clinician requires an understanding of the optical and adhesive properties of the materials to plan and create predictable esthetic and functional restorations.³

The purpose of this clinical report was to present a solution for a complex esthetic challenge based on detailed planning, the management of soft tissues, and restorative choices that considered the optical and adhesive properties of the materials.

CLINICAL REPORT

A 43-year-old woman dissatisfied with the esthetics of her smile presented to the Dental Clinic of APCD

ABSTRACT

Patients with challenging prosthodontic conditions require rehabilitation with a biological, functional, and esthetic approach. When one or more teeth are badly discolored, their restoration is problematic because poor appearance affects not only the crown but also the periodontal tissues. This clinical report describes a complex esthetic rehabilitation with conservative tissue management and ceramic restorations. Subepithelial connective tissue graft surgery and the replacement of a cast metal post with a glass fiber post addressed the problem of a discolored maxillary central incisor. The discolored right maxillary incisor was restored with a combination of a medium-opaque, lithium-disilicate ceramic coping to mask the dark root and to approximate the color of the other incisors. Subsequently, 6 ceramic veneers were placed. A knowledge of the materials' optical properties and adhesion possibilities helped solve this complex problem. (*J Prosthet Dent* 2020;■■■■■)

Regional Americana, Brazil. The gingival tissue associated with her maxillary right central incisor was darkened from an existing metal-ceramic crown (Fig. 1). After a clinical examination, a multidisciplinary treatment plan was approved.

Periodontal surgery was performed to increase the thickness of the labial gingiva around the right maxillary central incisor.⁴⁻⁶ After anesthesia, a thin connective tissue graft was harvested from the anterior region of the palate and was inserted into the labial gingiva of the right maxillary central incisor. Concurrently, the gingival margins of the adjacent teeth were recontoured with a gingivoplasty (Fig. 2).

Ninety days after the surgery, the existing metal-ceramic crown was replaced by an interim acrylic resin crown (Try In; VIPI) (Fig. 3). The root canal was retreated,

L.F.J. Schneider is grateful to FUNADESP for a research scholarship and FAPERJ for grant JCNE. L.M. Cavalcante is grateful to FUNADESP for a research scholarship.

^aLecturer, Department of Dental Implant and Aesthetic Dentistry of National Commercial Training Service (SENAC), São Paulo, Brazil.

^bDoctoral student, Fluminense Federal University (UFF), Niterói, Rio de Janeiro, Brazil.

^cLecturer, Department of Restorative Dentistry, Salgado de Oliveira University (UNIVERSO), Niterói, Brazil.

^dAssociate Professor, Department of Restorative Dentistry, Fluminense Federal University (UFF), Niterói, Rio de Janeiro, Brazil; and Lecturer, Salgado de Oliveira University (UNIVERSO), Niterói, Rio de Janeiro, Brazil; and Lecturer, Veiga de Almeida University (UVA), Rio de Janeiro, Brazil.

^eAssociate Professor, Department of Restorative Dentistry, Fluminense Federal University (UFF), Niterói, Rio de Janeiro, Brazil; and Lecturer, Veiga de Almeida University (UVA), Rio de Janeiro, Brazil.

The Influence of Tooth Color on Preparation Design for Laminate Veneers from a Minimally Invasive Perspective: Case Report



Christian Coachman, DDS, CDT¹

Galip Gurel, DDS, MSD²

Marcelo Calamita, DDS, MSD, PhD¹

Susana Morimoto, DDS, MSD, PhD³

Braulio Paolucci, DDS⁴/Newton Sesma, DDS, MSD, PhD⁵

Various types of dental preparations for laminate veneers have been proposed, depending on factors such as the properties of the ceramic material, remaining dental structure color, need for altering the dental contour, laboratory fabrication technique, and occlusal relationships. Clinical observations of successes and failures associated with the development of techniques and materials have allowed some safe parameters to be delineated for effectively performing dental preparations for ceramic veneers or even placing veneers without any preparation. This article describes the use of an additive diagnostic wax-up that is transferred to the mouth by means of an intraoral mock-up (aesthetic pre-evaluative temporary) with associated mathematic parameters to guide dental preparations. This technique, called Do the Math and presented here in the form of a clinical case report, aims to avoid excessive or incorrect tooth preparation by indicating the exact amount and location of the tooth reduction necessary to attain the desired color and shape. (Int J Periodontics Restorative Dent 2014;34:453-459. doi: 10.11607/prd.1900)

Ceramic veneers are highly esthetic restorations with predictable outcomes when placed based on appropriate indications.¹⁻⁵ Various dental preparation designs for veneers have been proposed and have depended on factors such as the properties of the ceramic material, color of the remaining dental structure, need for altering the dental contour, laboratory fabrication technique, and occlusal relationships. In addition, the concepts and skills of the restorative dentist together with technician expertise had significant influence on the definitive result. Over the course of time, clinical observations of successes and failures,⁶⁻⁹ associated with the development of techniques and materials, have allowed some safe parameters to be delineated for effectively performing,^{10,11} or not performing,¹²⁻¹⁴ dental preparations for the placement of ceramic veneers.

Preparations for laminate veneers may be divided didactically into three generations. In the first generation (depth guide generation),¹⁵⁻¹⁷ diamond burs of preestablished depths are used to perform

¹Private Practice, São Paulo, Brazil.

²Private Practice, Istanbul, Turkey; Visiting Professor, New York University College of Dentistry, New York, New York, USA; Visiting Professor, University of Marseille, Marseille, France.

³Professor, Graduate Program, School of Dentistry, Ibirapuera University, São Paulo, Brazil.

⁴Private Practice, Barbacena, Brazil.

⁵Assistant Professor, Department of Prosthodontics, University of São Paulo, São Paulo, Brazil.

Correspondence to: Dr Christian Coachman, Rua Bento de Andrade, 116, Sao Paulo-SP, Brazil, 04503-000; email: digitalsmiledesign@hotmail.com.

©2014 by Quintessence Publishing Co Inc.



Ivan Contreras
Molina

Partial-prep bonded restorations in the anterior dentition: Long-term gingival health and predictability. A case report

Ivan Contreras Molina, DDS, MSc, PhD¹/Gil Contreras Molina, DDS²/Kyle Stanley, DDS³/Carlo Lago, DDS, MSc, PhD⁴/Clessius Ferreira Xavier, DDS, MSc, PhD⁵/Claudia Angela Maziero Volpato, DDS, MSc, PhD⁶

Bonded porcelain restorations are a predictable and durable treatment option that can restore not only the strength and function of the teeth but also the esthetic appearance. One important issue in adhesive dentistry is the preservation of sound enamel. Following biomimetic principles, employing minimally invasive applications and adhesive technologies is of paramount importance for successful restorations. While it is widely accepted that minimally invasive restorative techniques

should be favored, there is still some controversy over the non-invasive approaches. The purpose of this article is to question the complete "no-prep veneer" concept due to the possible negative effects on periodontal health caused by excessive contour and overhangs of the ceramic restoration, and to propose a new method to assess the quality and longevity of veneers with a partial-prep concept. (doi: 10.3290/j.qi.a34809)

Key words: adhesive luting, biomimetic principles, bonded porcelain restorations, esthetic, minimally invasive treatment modalities, scanning electron microscopy

In the last decade, a serious trend for simplification of anterior bonded porcelain restorations has reemerged, the so-called "no prep" approaches.¹⁻⁶ Already popular in the 1980s, those noninvasive approaches had been hindered during the 1990s to 2000s by aggressive

ceramic preparations⁷ as the result of simplified but greedy laboratory methods. The current resurgence of oversimplified methods appears as a logical response to the 1990's to 2000's preparation euphoria and was also facilitated by technological improvements to produce much thinner, pressable ceramic veneers.

As described by Dr Goldstein in a very fair and well-presented viewpoint article,¹ it seems that veneer tooth preparation principles are in a reciprocating pendulum, balancing from a right-wing approach to a left-wing extreme. The clinician may find himself navigating in the midst of those concepts, even experiencing a certain amount of guilt for not being able to adapt to those changing concepts. But the dentist, using scientific evidence along with his common sense and experience, should always remain the decision maker. The treatment must be based on knowledge, wisdom, and

¹ PhD Student, Department of Implantology, University Federal Of Santa Catarina, Florianopolis, SC, Brazil.

² Associate Professor, Department of Dentistry, Universidad Michoacana de San Nicolas de Hidalgo, Morelia, Mexico.

³ Adjunct Faculty, Department of Restorative Sciences, Herman Ostrow School of Dentistry of USC, Los Angeles, California, USA.

⁴ PhD Student, Department of Operative Dentistry, University Federal Of Santa Catarina, Florianopolis, SC, Brazil.

⁵ PhD Student, Department of Implantology, University Federal Of Santa Catarina, Florianopolis, SC, Brazil.

⁶ Associate Professor of Prosthodontics, Department of Dentistry, University Federal Of Santa Catarina, Florianopolis, SC, Brazil.

Correspondence: Dr Ivan Contreras Molina, Priv. Plan de Ayutla #39 Col. Chapultepec Sur, Cp. 58260, Morelia, Mexico. Email: dr.ivancontreras@gmail.com

Protocol for a new concept of no-prep ultrathin ceramic veneers

Camillo D'Arcangelo¹ | Mirco Vadini¹ | Maurizio D'Amario²  |
Zaccheo Chiavaroli³ | Francesco De Angelis¹

¹Unit of Restorative Dentistry, Department of Oral Science, Nano and Biotechnology, "G. D'Annunzio" University of Chieti, Chieti, Italy

²Unit of Restorative Dentistry, Endodontics and Oral Pathology, Department of Life, Health and Environmental Sciences, Dental Clinic, University of L'Aquila, L'Aquila, Italy

³Private Practice, Pescara, Italy

Correspondence

Prof. Camillo D'Arcangelo, Unit of Restorative Dentistry, Department of Oral Science, Nano and Biotechnology, "G. D'Annunzio" University of Chieti, Via dei Vestini 31, 66100 Chieti, Italy.
Email: cdarcang@unich.it

Abstract

Objectives: No-prep veneers, although ideally considered the best option because of tooth structure maximum preservation, have been frequently criticized for some potential limitations including esthetic outcomes and periodontal complications.

Clinical considerations: A new protocol to optimize no-prep veneers restorations is presented. A key point of the proposed technique is to identify optimal margins' positions: margin is positioned in the point of maximum convexity of teeth, avoiding the over contouring of traditional no-prep veneers.

Conclusion: The procedure can be appreciated for the marginal accuracy and the resulting aesthetic stability. The case reports show that properly managed no-prep veneers can have biologically healthy and aesthetically pleasant tooth-restoration transitions and emergence profiles.

Clinical Significance

High-quality no-prep veneers can be more challenging to realize than conventional veneers and the success seems to depend on a combination of good case selection, margins' position, sound adhesive principles, clinical, and laboratory experience.

KEYWORDS

ceramic, dental adhesion, no-prep veneer

1 | INTRODUCTION

Ceramic veneers are frequently presented as the major class of clinical conservative modalities in aesthetic dentistry.^{1,2} The so-called "no-prep" approaches have been described for more than 10 years in literature³⁻⁸ and ideologically reiterate the methodologies of 1980s, when veneers were introduced as conservative, additive restorative procedures for which slight or no preparations were required.^{9,10} Nevertheless, lack of clear-cut guidelines for technical procedures and for case selection has often led to confusion and misunderstandings.¹¹ Frequently, no-prep veneers, although ideally considered the best option because of tooth structure maximum preservation, were essentially criticized for some potential limitations including esthetic outcomes and periodontal complications as a consequence of overcontoured teeth that could alter the emergence profiles.^{11,12}

Indeed, no-prep veneers could have biologically healthy and optically beautiful margins and emergence profiles if properly selected and

managed. Some interesting papers focused on no-prep veneers case selection process are available¹³⁻¹⁶; conversely clinical studies often do not provide enough technical information on clinical and laboratory perspectives.

In this article, a new protocol to optimize no-prep veneers restorations (called CH NO-PREP VENEERS) is presented. A key point of the proposed technique is to identify optimal margins' positions: margin is positioned in the point of maximum convexity of teeth, avoiding the over contouring of traditional no-prep veneers (Figure 1). Dental maximum convexity works as a natural finishing line for veneer. In this way, veneer cannot change dental profile after cementation.

2 | CASE SELECTION

For patients who visually may be aspirants for no-prep veneers rehabilitations, an additive-only wax-up should be prepared; a silicone matrix