

***TRABAJO DE FIN DE GRADO***

***Grado en Odontología***

**Estudio retrospectivo de  
los tipos de reconstrucción  
del diente endodonciado  
realizadas en la clínica de  
grado en el año 2019**

**Madrid, curso 2020/2021**

Número identificativo 

114
-----

# Índice

<b>1. Introducción</b> .....	5
<b>1.1 DIAGNÓSTICO ENDODÓNTICO Y CAUSAS DE LAS ENDODONCIAS</b> .....	5
<b>1.2 OBJETIVOS DE LA ENDODONCIA</b> .....	6
<b>1.3 VALORACIÓN DEL DIENTE PREVIA A LA ENDODONCIA</b> .....	7
1.3.1 Valoración periodontal .....	7
1.3.2 Valoración del tejido remanente .....	8
1.3.3 Valoración biomecánica.....	9
1.3.4 Valoraciones estéticas.....	10
<b>1.4 CARACTERÍSTICAS DEL DIENTE ENDODONCIADO</b> .....	10
<b>1.5 RECONSTRUCCIÓN DEL DIENTE ENDODONCIADO</b> .....	11
1.5.1 TIEMPO ENTRE ENDODONCIA Y SU RECONSTRUCCIÓN.....	11
1.5.2 OBJETIVOS DE LA RESTAURACIÓN DEFINITIVA.....	12
1.5.3.1 Reconstrucción directa.....	12
<b>1.5.4 Materiales</b> .....	17
1.5.4.1 Postes.....	17
1.5.4.2 Incrustaciones .....	17
1.5.4.3 Coronas .....	18
1.5.4.4 Carillas .....	18
<b>2. OBJETIVOS</b> .....	19
<b>2.1 OBJETIVO PRINCIPAL</b> .....	19
<b>2.2 OBJETIVOS SECUNDARIOS</b> .....	19
<b>3. MATERIAL Y MÉTODO</b> .....	21
<b>4. RESULTADOS</b> .....	28
<b>5. DISCUSIÓN</b> .....	36
5.1 Propuesta de protocolo de actuación para la reconstrucción de un diente endodonciado en la policlínica de la Universidad Europea de Madrid .....	39
<b>6. CONCLUSIÓN</b> .....	43
<b>7. PROPUESTAS DE MEJORA</b> .....	45
<b>Bibliografía</b> .....	46
<b>Anexos</b> .....	51

## Resumen

*Objetivos:* El objetivo de este estudio es determinar el tipo de reconstrucciones realizadas en dientes endodonciados en la Policlínica y comparar los resultados con otros estudios. Determinar la causa de destrucción dentaria más frecuente que afecta a los dientes endodonciados. Cuantificar el tiempo que transcurre entre la finalización del tratamiento de conductos y de la reconstrucción. Determinar el grado de destrucción dentaria según la cantidad de tejido afectado.

*Metodología:* Se ha realizado una revisión bibliográfica a través de Pubmed. Se trata de un estudio retrospectivo, observacional, descriptivo y transversal a 1 año, donde se ha tomado una muestra total de 355 casos sacados de la policlínica de la Universidad Europea de Madrid en el año 2019 para la elaboración de este estudio.

*Resultados:* De los 355 casos, 331 han sido reconstruidos de manera completa; 288 fueron reconstruidos con técnica directa y 43 con técnica directa e indirecta.

*Conclusiones:* La mayoría de las reconstrucciones completas tras la endodoncia han sido restauraciones directas (87,01%), un total de 288 casos, de los cuales 26 casos fueron obturados de manera simple, 149 con obturaciones complejas, 75 con poste y reconstrucción y 81 con una gran reconstrucción. Sólo en 45 casos se realizaron restauraciones indirectas. 24 casos han quedado sin restaurar. La causa de destrucción dentaria más frecuente que afecta a los dientes endodonciados es la caries (79,72%) seguido de obturaciones filtradas (13,24%). El período de tiempo tras la endodoncia para la reconstrucción ha de ser lo antes posible ya que mejora el pronóstico de la endodoncia. En nuestro estudio la mayoría de los casos presentaban grado II (48,17%) y grado III (33,24%)

## **Abstract**

*Objectives:* The aim of this study is to determine the type of reconstructions performed on endodontic teeth at the Polyclinic and to compare the results with other studies. Determine the most frequent cause of tooth destruction that affects endodontic teeth. Quantify the time that elapses between the completion of root canal treatment and reconstruction. Determine the degree of tooth destruction according to the amount of tissue affected.

*Methodology:* a bibliographic review has been carried out through Pubmed. It is a retrospective, observational, descriptive and cross-sectional study at 1 year, where a total sample of 355 cases was taken from the polyclinic of the Universidad Europea de Madrid in 2019 for the preparation of this study. *Results:* Of the 355 cases, 331 have been completely reconstructed; 288 were reconstructed with direct technique and 43 with direct and indirect technique.

*Conclusions:* Most of the complete reconstructions after endodontics have been direct restorations (87.01%), a total of 288 cases, of which 26 cases were filled in a simple way, 149 with complex obturations, 75 with posts and reconstruction and 81 with a big rebuild. Only in 45 cases were indirect restorations performed. 24 cases have remained unrestored. The most frequent cause of tooth destruction that affects endodontic teeth is caries (79.72%) followed by filtered obturation (13.24%). The period of time after endodontics for reconstruction should be as soon as possible as it improves the prognosis of endodontics. In our study, most of the cases presented grade II (48.17%) and grade III (33.24%)

## 1. Introducción

El éxito endodóntico está determinado tanto por la calidad del tratamiento de conductos y de la restauración dentaria en ausencia de signos y síntomas<sup>1</sup>.

### 1.1 DIAGNÓSTICO ENDODÓNTICO Y CAUSAS DE LAS ENDODONCIAS

Para realizar una endodoncia antes debemos tener claro el diagnóstico pulpar y periodontal del diente, así como la causa. Para realizar un buen diagnóstico clínico del diente debemos realizar un examen intraoral, aletas de mordida para detectar las caries interproximales que no alcanzamos a ver en el examen intraoral, radiografías periapicales y ayudarnos de las pruebas de diagnóstico de la vitalidad pulpar, percusión, y palpación.

Para establecer el diagnóstico pulpar y periodontal del diente nos basamos en la clasificación de diagnóstico pulpar (Tabla 1) y periodontal (Tabla 2) propuesta por la AAE de diciembre 2009.

DIAGNÓSTICO		
PULPAR	CARACTERÍSTICAS CLÍNICAS	CARACTERÍSTICAS RADIOGRÁFICAS
PULPA NORMAL	No síntomas	Sin alteración periapical
	Prueba de sensibilidad positiva	
PULPITIS REVERSIBLE	No dolor espontáneo	No presenta cambios
	Dolor transitorio leve o moderado ante estímulos	
	Prueba de sensibilidad positiva	
PULPITIS IRREVERSIBLE SINTOMÁTICA	Dolor referido o espontáneo moderado a severo	Posible engrosamiento del espacio del ligamento periodontal
	Dolor que disminuye con frío y aumenta con calor	Imagen radiopaca compatible con restauraciones profundas
	Dolor permanece después de la retirada del estímulo	
	Prueba de sensibilidad positiva	Zona radiolúcida en la corona compatible con caries
	Dolor a la percusión	
Presencia de caries, obturación profunda o trauma		
PULPITIS IRREVERSIBLE ASINTOMÁTICA	No hay síntomas clínicos	Sin alteración periapical
	Exposición pulpar	Posible engrosamiento del espacio del ligamento periodontal
	Prueba de sensibilidad positiva con respuesta anormal prolongada	Zona radiolúcida en la corona compatible con caries, restauraciones profundas o trauma
NECROSIS PULPAR	Prueba de sensibilidad negativa. Puede dar falsos positivos	Ligero ensanchamiento del espacio del ligamento periodontal
	Cambio de coloración de la corona Puede presentar dolor a la percusión y movilidad.	Zona radiolúcida en la corona compatible con caries y restauraciones profundas
PREVIAMENTE TRATADO	Diagnóstico clínico indicando que el diente ha sido endodónticamente tratado	Cambios periapicales variables Conducto radicular obturado en calidad y longitud en diferentes materiales
PREVIAMENTE INICIADO	Diagnóstico clínico que indica el diente ha sido previamente indicado como una pulpectomía o pulpotomía	Cambios periapicales variables

**Tabla 1.** Diagnóstico pulpar según la AAE. Tomado de los protocolos clínicos de la policlínica universitaria UEM curso 2020-2021.

PERIAPICAL	CARACTERÍSTICAS CLÍNICAS	CARACTERÍSTICAS RADIOGRÁFICAS
<b>TEJIDOS APICALES SANOS</b>	Periodonto perirradicular sano. Palpación y percusión negativas	Espacio del ligamento periodontal uniforme. Lámina dura intacta
<b>PERIODONTITIS APICAL SINTOMÁTICA</b>	Dolor espontáneo o severo	Se puede o no observar cambios en los tejidos de soporte circundante
	Dolor localizado persistente y continuo	Puede observarse ensanchamiento del espacio del ligamento periodontal
	Dolor tan severo que puede interrumpir actividades cotidianas	Puede o no estar asociado a radiolucidez apical
	Dolor a la percusión y palpación	
<b>PERIODONTITIS APICAL ASINTOMÁTICA</b>	Sensación de presión en la zona apical del diente	
	Generalmente asintomática o asociada a molestia leve	Zona radiolúcida apical de origen pulpar
	Tejidos circundantes dentro de parámetros normales	
	Respuesta positiva a la palpación	
<b>ABSCESO APICAL AGUDO</b>	Sensibilidad a la palpación, si hay compromiso de tabla ósea vestibular	
	Prueba de sensibilidad negativa	
	Proceso infeccioso por una necrosis pulpar	Puede o no revelar cambios en el tejido circundante periapical
	De comienzo rápido	
	Dolor espontáneo, a la presión, palpación y percusión	Puede observarse ensanchamiento del espacio del ligamento periodontal o una zona de reabsorción ósea apical, asociada a una periodontitis apical asintomática
	Formación o acúmulo de pus	
	Inflamación intra o extraoral	
	Dolor localizado y persistente	
	Dolor constante y/o pulsátil	
	Dolor a la presión (sensación de diente extruido)	
<b>ABSCESO APICAL CRÓNICO</b>	Dolor localizado o difuso de tejidos blandos intraorales	
	Movilidad aumentada	
	Malestar general	
	Proceso infeccioso por una necrosis pulpar de comienzo gradual	Zona radiolúcida apical
Ligera sensibilidad	Se debe realizar una fistulografía con cono de gutapercha	
Presencia de fistula		
Asintomático		
Prueba de sensibilidad negativa		

**Tabla 2.** Diagnóstico periodontal según la AAE. Tomado de los protocolos clínicos de la policlínica universitaria UEM curso 2020-2021.

Las causas que llevan a un diente a este diagnóstico pueden deberse a múltiples factores; una caries extensa, una obturación filtrada, un traumatismo, una reabsorción interna o externa, etc.

## 1.2 OBJETIVOS DE LA ENDODONCIA

El objetivo de una endodoncia es eliminar el tejido pulpar del diente, sellar los ápices y los conductos del diente y conseguir un sellado histológico a largo plazo. Para conseguir realizar una endodoncia con éxito es importante conocer la anatomía del diente y sus características, la situación de las raíces, las fuerzas que va a estar sometido, las distintas patologías que tiene el paciente, y la funcionalidad o estética que se le quiera dar. Todo esto va a condicionar no solo a la endodoncia que se va a realizar, sino también que tipo de reconstrucción realizar y con qué material<sup>2</sup>.

El conocimiento y un buen manejo de una buena técnica de endodoncia nos permitirá mantener dientes en boca, lo cual siempre será más beneficioso para el paciente, ya que ninguna prótesis o implante tiene mejores propiedades que los propios dientes<sup>3</sup>

La influencia de la técnica por parte del odontólogo es una de las claves para el éxito de la endodoncia. Por ejemplo, una buena condensación en la endodoncia previene de apariciones de lesiones periapicales<sup>4</sup> y un buen sellado periférico nos permite que dicha endodoncia no se vea comprometida y contaminada<sup>5</sup>. En cambio, una mala elección de la técnica, aunque sea un tratamiento bien realizado puede ser un fracaso si no es el idóneo para ese caso concreto. Por esto es tan importante la técnica como la sintomatología que presenta el paciente<sup>1</sup>.

### **1.3 VALORACIÓN DEL DIENTE PREVIA A LA ENDODONCIA**

A la hora de la realización de la endodoncia hay una serie de consideraciones que debemos tener en cuenta antes de poder comenzar, entre ellas valoraremos el estado periodontal, el tejido remanente, la biomecánica del propio diente, y la valoración estética.

#### **1.3.1 Valoración periodontal**

La situación del diente en el alveolo, el estado del ligamento periodontal y la pérdida ósea que posea el paciente repercutirá directamente en el éxito de la endodoncia<sup>6</sup>.

En función del estado periodontal nos podemos encontrar los siguientes casos:

- A) Que el periodonto esté sano y no haya pérdida ósea. En este caso desde el punto de vista periodontal, el paciente tiene buen pronóstico y predecible<sup>6</sup>.
- B) Que exista pérdida ósea, en este caso si la pérdida ósea es leve tendrá un pronóstico aceptable, en cambio sí es mayor y el pronóstico es malo, se puede considerar la regeneración ósea como medida para evitar la extracción<sup>6</sup>.
- C) Que haya una fractura radicular vertical, convierte el pronóstico en malo-imposible<sup>6</sup>.

Se ha demostrado que el porcentaje de éxito de las endodoncias en dientes sin sintomatología apical preoperatoria se encuentra por encima del 90% mientras que con presencia de periodontitis apical preoperatoria este porcentaje disminuye hasta entre el 75 y el 80%<sup>1</sup>.

### 1.3.2 Valoración del tejido remanente

Un diente intacto posee una mayor resistencia a la fractura que cualquier otro diente que se haya obturado<sup>7</sup>. El índice de fractura aumenta significativamente en función de las paredes remanentes que el diente posea (cuántas menos paredes tenga el diente, mayor será el índice de fractura<sup>7</sup>) (tabla 3). A partir de que falten dos paredes el riesgo de fractura crece exponencialmente<sup>8</sup>. Cabe destacar la importancia de las paredes mesial y distal del diente, si ambas se ven afectadas, el diente aumentará su riesgo de fractura significativamente<sup>7</sup>.

El número de paredes afectadas influirá directamente en la elección de la técnica a la hora de la reconstrucción (tabla 3), una buena elección de la técnica



y del material usado en el diente endodonciado ayuda a la supervivencia del diente endodonciado<sup>9</sup>.

Porcentaje de fracaso, éxito y supervivencia en función del tejido remanente del diente			
Estructura coronal remanente	Tasa de fracaso del tratamiento	Tasa de éxito del tratamiento	Tasa de supervivencia del diente
4 Paredes remanentes o Grado I	0%	100%	100%
3 Paredes remanentes o Grado II	21,1%	78,2%	100%
2 Paredes remanentes o Grado III	30,2%	69,8%	91,2%
1 Pared remanente o Grado IV	47%	52,9%	94,1%
0 paredes remanentes y presencia de ferrule	66%	34%	92,6%
0 paredes remanentes y ausencia de ferrule	77,2%	22,8%	80,7%

**Tabla 3.** Porcentajes de éxito y fracaso y de supervivencia del diente según la estructura remanente. Resultados del estudio de Ferrari y cols.<sup>10</sup>

### 1.3.3 Valoración biomecánica

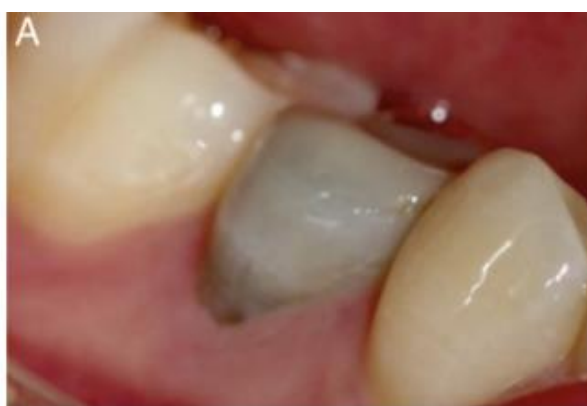En este apartado encontramos el efecto ferrule, que confiere una protección de vital importancia para la corona, previniendo de fracturas verticales y aumentando la resistencia a la hora de la masticación<sup>11</sup> y disminuyendo el impacto del poste en el diente<sup>12</sup>. Para conseguir un buen efecto ferrule debemos tener una altura de 1,5-2 mm y una anchura de 1 mm<sup>11</sup>.

En caso de que no podamos conseguir un ferrule completo, siempre será más beneficioso un ferrule parcial a uno ausente<sup>11</sup> (tabla 3). Por este motivo se

puede llegar a considerar un alargamiento coronario o incluso la extrusión ortodóntica del diente para conseguir el ferrule necesario<sup>12</sup>.

#### 1.3.4 Valoraciones estéticas

Un diente endodonciado puede experimentar cambios estéticos al cabo de un tiempo. Los conos de gutapercha también pueden producir un cambio de coloración del diente, por eso es importante eliminar la gutapercha de la parte coronal para minimizar esta coloración<sup>13</sup>. (fig. 1)



**Fig. 1.** Foto de cambio de color de un diente endodonciado. Foto tomada del artículo: Bleaching of a Discolored Tooth with Retrieval of Remnants after Successful Regenerative Endodontics.<sup>14</sup>

### 1.4 CARACTERÍSTICAS DEL DIENTE ENDODONCIADO

Los dientes una vez que son endodonciados, no solo pierden la vitalidad pulpar, sino que también pierden gran cantidad de tejido remanente, ya sean por caries, fractura, o restauraciones previas del diente, dejando al diente debilitado, haciendo que sean más propensos a la fractura<sup>2</sup>.

Para la realización de una endodoncia, la parte coronal se verá afectada por la realización de la apertura cameral, provocando que las cargas funcionales recibidas por el diente, no se distribuyan de igual forma que un diente sin

endodonciar<sup>15</sup>. Debemos rellenar el interior del diente una vez lo endodoncamos, lo que impide al diente actuar como si estuviese hueco, laminado y pretensado<sup>15</sup>. A pesar de que no existe una manifestación clara, los dientes endodonciados además sufren una degradación de las fibras colágenas, volviendo al diente más rígido y menos flexible<sup>15</sup>.

Un diente endodonciado también verá comprometida su sensibilidad a la tensión. La eliminación de los mecanorreceptores de la pulpa provoca que el diente tenga que soportar hasta dos veces más las cargas que soportaría si estuviese vital<sup>15</sup>.

Un diente endodonciado puede experimentar cambios estéticos al cabo de un tiempo. La dentina, al sufrir cambios bioquímicos, produce unos cambios cromáticos que al cabo de un tiempo se pueden observar a través del esmalte<sup>13</sup>.

## **1.5 RECONSTRUCCIÓN DEL DIENTE ENDODONCIADO**

La reconstrucción del diente endodonciado conlleva varias opciones clínicas de diversa complejidad además de las valoraciones anteriores, y parece que no hay una forma ideal de restaurar un diente endodonciado<sup>16</sup>.

Debemos tener en cuenta qué tipo de diente vamos a endodonciar; un diente del sector anterior, dónde se requiere una buena estética, y las fuerzas de oclusión no son las mismas a las que va a estar sometido un diente del sector posterior<sup>2</sup>.

### **1.5.1 TIEMPO ENTRE ENDODONCIA Y SU RECONSTRUCCIÓN**

No se debe demorar en exceso la reconstrucción coronaria una vez hecha la endodoncia, lo ideal sería realizarla en la misma semana que se realiza la endodoncia, o incluso el mismo día. Sin embargo, un estudio realizado por

Kwang y cols.<sup>17</sup> afirma que el tiempo máximo de espera entre el tratamiento endodóntico y la restauración coronaria, puede llegar a ser de 9 meses con una buena técnica por parte del odontólogo, excederse podría implicar un fracaso de la endodoncia<sup>17</sup>.

### 1.5.2 OBJETIVOS DE LA RESTAURACIÓN DEFINITIVA

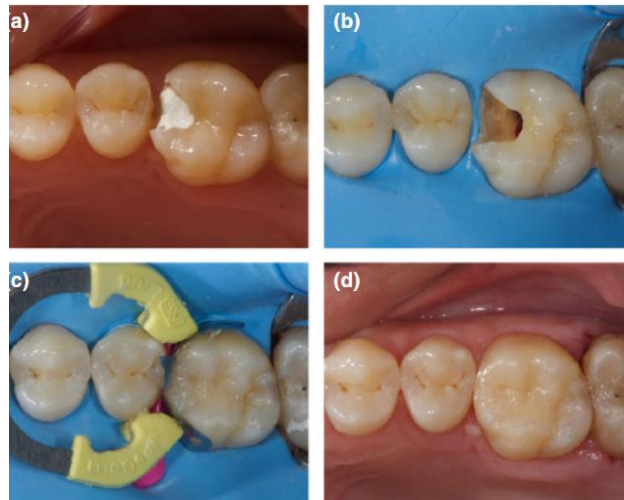
El principal objetivo de la restauración definitiva es conseguir un buen sellado periférico, evitando que filtraciones y que la endodoncia no se vea comprometida<sup>5</sup>. Además, confiere al diente de la estructura dentaria perdida a la hora de la realización de la endodoncia, reforzando la estructura dentaria remanente.

### 1.5.3 TIPOS DE RECONSTRUCCIÓN: DIRECTAS E INDIRECTAS

#### 1.5.3.1 Reconstrucción directa

##### A) Técnica directa con composite

Se ha demostrado que se trata de la técnica de elección cuando se trata de restauraciones mínimamente invasivas y hay 3 o 4 paredes intactas, ya que, con tanto tejido dentario remanente, este tipo de reconstrucción tiene muy buen pronóstico<sup>2</sup>. (Tabla 4) (Fig 2)



**Fig. 2.** Caso clínico de reconstrucción de un diente endodonciado con una pared afectada. Caso tomado del artículo: A New Classification System for the Restoration of Root Filled Teeth.<sup>18</sup>

Tipos de reconstrucción directa	
Obturación simple	Obturación de una pared
Obturación compleja	Obturación de dos paredes
Gran reconstrucción	Obturación de tres paredes o más.

**Tabla 4.** Tipos de reconstrucción directa

En caso de que se trate de un diente del sector anterior debemos tener cuidado de que la estética no se vea comprometida, en caso de que así sea, debemos ser más cuidadosos a la hora de selección del composite y realizar un buen pulido para conseguir una mejor estética.

#### B) Poste

A la hora de realizar una reconstrucción con poste, implica eliminar 2/3 de la gutapercha de la raíz endodonciada previamente y sustituirla por un poste, que nos ayudará a reconstruir el diente usando el poste como soporte<sup>19</sup>. Debemos evitar la contaminación bacteriana de los conductos durante el

tratamiento. Se pueden usar desde 3 paredes residuales a ninguna (Tabla 5). Sin embargo está contraindicado en casos en los que el diente tenga unas raíces con curvatura pronunciada.

Se debe conservar la estructura dental radicular y coronal usando postes con la resistencia y la longitud adecuada. Estos postes pueden ser de fibra de vidrio o metálicos, no hay una clara ventaja el uno sobre el otro, pero cuando la cavidad se encuentra poco accesible, es preferible la opción de fibra de vidrio dado que obtiene mejores resultados debido a que a la hora de polimerizar el poste de fibra de vidrio permite más el paso de luz que el metálico. Lo ideal es usar postes que sean reparables<sup>19</sup>. La mejor forma de reconstrucción tras la colocación del poste es el uso de composite<sup>19</sup>.

No se ha demostrado que el uso de postes (ya sea de fibra o metálico) afecte negativamente al hueso interproximal<sup>20</sup>.

Proporcionar recubrimiento cuspeideo para los dientes posteriores o una corona mejora significativamente las probabilidades de éxito de la endodoncia<sup>21</sup>.

Tipos de reconstrucción según grado de afectación dentaria						
	Técnica directa	Incrustación in-lay	Incrustación On-Lay	Postes	Endocrown	Corona
0 paredes afectadas	Tratamiento de elección	Buen pronóstico	No se usa	No se usa	No está indicado	No está indicado
1 pared afectada	Buen pronóstico	No está indicado	Buen pronóstico	No se usa	No está indicado	No está indicado
2 paredes afectadas	Pronóstico dudable	No está indicado	No se usa	Tratamiento de elección	No está indicado	Buen pronóstico
3 paredes afectadas	Mal pronóstico	No está indicado	No está indicado	Tratamiento de elección	No recomendado	Buen pronóstico

4 paredes afectadas	No recomendado	No está indicado	No está indicado	Buena elección	Buena elección	Buena elección
Toda la corona afectada	No está indicado	No está indicado	No está indicado	Pronóstico dudable	Buena elección	Pronóstico dudoso

**Tabla 5.** Tipos de reconstrucción según grado de afectación dentaria

### C) Restauraciones indirectas

Se trata de la técnica de elección en dientes muy dañados, ya que en un período de tiempo medio-corto tiene mejores resultados<sup>21</sup>. Este tipo de restauraciones pueden realizarse de dos materiales, de composite o de porcelana:

#### C.1) Restauraciones inlay

Debemos realizar una impresión de la cavidad del diente, obteniendo un modelo para adaptar una resina que encaje en la cavidad realizada. Las restauraciones inlay se usan en cavidades mínimamente invasivas y con 4 paredes intactas. Entre la técnica directa y esta no hay evidencia científica que determine cuál de estas dos opciones es mejor<sup>22</sup>. (Tabla 5)

#### C.2) Restauraciones onlay

Cuando el diente tiene tres paredes intactas y una destruida (Tabla 5), podemos hacer una restauración de composite directa, como explicamos antes, o una restauración indirecta onlay, que se diferencia de la inlay en que la onlay abarca una pared y no solo la cara oclusal además de alguna cúspide<sup>22</sup>. En casos en los que alguna cúspide se vea afectada debemos realizar recubrimiento

cuspídeo, así como en las cúspides activas del diente donde vayamos a realizar la incrustación<sup>22</sup>.

### C.3) Endocrown

Se trata de una técnica indirecta (hecha en el laboratorio) que sigue el mismo estilo que las reconstrucciones anteriores (inlay y overlay) pero que abarca toda la corona del diente y que se sujeta mecánica y adhesivamente al diente de manera que encaja en la cavidad reteniéndolo. Los endocrowns suelen colocarse en dientes sin efecto ferrule ya que soportan mejor las cargas oclusales. En premolares no funcionan tan bien<sup>23</sup>. (Tabla 5)

### C.4) Coronas

Cuando el diente tiene dos o más paredes intactas y dos destruidas podemos colocar una corona metal-porcelana (Tabla 5). Se trata de restauraciones que cubren todo el diente, mejorando el sellado periférico, pero la preparación de la corona implica la remoción de tejido dentario sano. Por ello debemos ser lo más conservadores posibles en la realización del tallado, respetando siempre el tejido remanente y el ferrule<sup>9</sup>. En caso de que haya tejido dentario débil o muy afectado debemos eliminarla, ya que es más propensa a fracturas.

También cabe la posibilidad de realizar una reconstrucción con poste, composite y añadirle una corona para aumentar el sellado del diente.



## C.5) Carillas

Aunque no se trata realmente de una técnica de restauración definitiva, nos ayuda a mejorar la estética en casos donde no se la podamos otorgar con una técnica directa<sup>24</sup>.

### **1.5.4 Materiales**

A la hora de elegir los materiales, debemos tener en cuenta las fuerzas oclusales que van a soportar estos dientes restaurados, y, elegir el más conveniente para cada caso.

#### 1.5.4.1 Postes

En el caso de los postes puede ser metálico o de fibra. Los metálicos se usan cuando hay suficiente espacio para reconstruir el diente y permite una correcta polimerización; en cambio los de fibra se usan para espacios reducidos, estos postes facilitan la fotopolimerización de la reconstrucción, además últimamente está dando muy buenos resultados<sup>9</sup>.

#### 1.5.4.2 Incrustaciones

En el caso de las restauraciones inlay y onlay (como dijimos anteriormente), se pueden realizar de composite, cerámica o disilicato de litio; en caso de que el diente a reconstruir no tiene diente antagonista o no soporta muchas fuerzas oclusales se optará por la restauración de composite. En cambio, si se va a ver sometido a fuerzas oclusales grandes, las cerámicas tienen mejores resultados que las de composite<sup>25</sup>.

#### 1.5.4.3 Coronas

Las coronas pueden usarse de porcelana o de metal-porcelana. Las coronas de porcelana soportan peor las cargas oclusales, pero son más estéticas, por ellas son las de elección en los casos de dientes anteriores ya que no se exponen tanto a las cargas oclusales. En cambio las coronas metal-porcelana, aunque no otorgan tanta estética, sí soportan bien las cargas oclusales, por ello son las usadas en los dientes posteriores<sup>9</sup>.

#### 1.5.4.4 Carillas

La carilla de composite se puede usar tanto en reconstrucciones pequeñas como grandes, mejorando la estética, se colocan en la cara vestibular.

Las carillas de porcelana se pueden usar cuando se trata de un diente con tinción que no vamos a lograr obtener un cambio de color con un blanqueamiento, para ello podemos usar este tipo de carillas, ya que proporcionarán más estética<sup>24</sup>.

## **2. OBJETIVOS**

### **2.1 OBJETIVO PRINCIPAL**

Determinar el tipo de reconstrucciones realizadas en dientes endodonciados por los alumnos de grado de Odontología en la Policlínica Universitaria de la Universidad Europea de Madrid durante 2019.

Comparar los resultados con otros estudios e implementar un protocolo de actuación del tratamiento restaurador de los dientes endodonciados en Policlínica.

### **2.2 OBJETIVOS SECUNDARIOS**

- 1) Analizar la causa de destrucción dentaria más frecuente que afecta a los dientes endodonciados de los pacientes tratados por los alumnos de grado en 2019.
- 2) Determinar el grado de destrucción dentaria según la cantidad de tejido afectado.
- 3) Identificar el diente que presenta mayor destrucción dentaria.
- 4) Cuantificar el tiempo que transcurre entre la finalización del tratamiento de conductos y de la reconstrucción.
- 5) Cuantificar el porcentaje de dientes endodonciados por los alumnos que no han recibido tratamiento restaurador definitivo por ellos (restauración directa-indirecta-sin restaurar).
- 6) Conocer los diferentes tipos de reconstrucción que se realizan en los dientes endodonciados por los alumnos de grado en 2019 e identificar el tipo de restauración más frecuente en estos casos.

- 7) Conocer los diferentes materiales empleados en las reconstrucciones de los dientes endodonciados realizadas por los alumnos de grado en 2019 e identificar el material empleado más frecuente en estos casos.

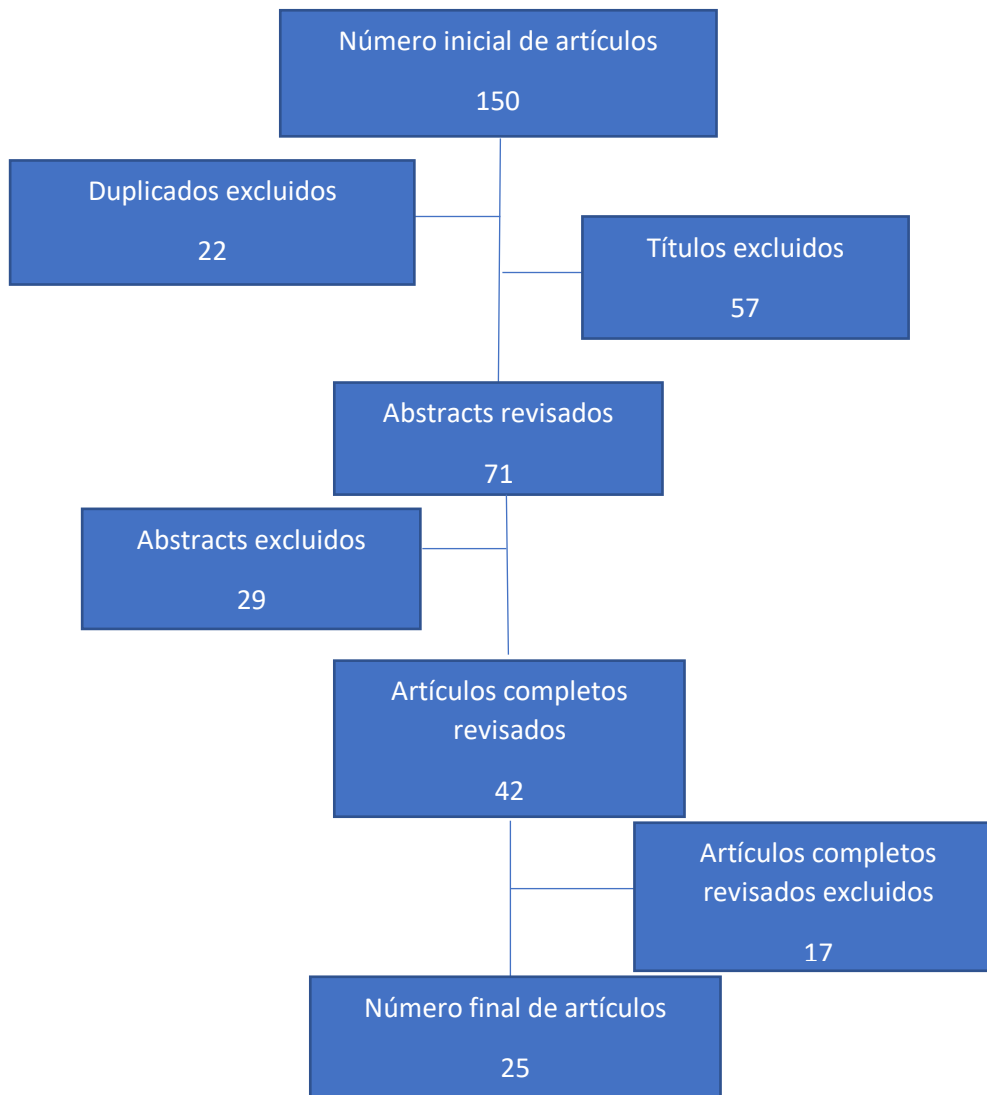
### 3. MATERIAL Y MÉTODO

#### Revisión bibliográfica

Se realizó una búsqueda a través de la base de datos de PubMed a través de la Biblioteca Dulce Chacón de la Universidad Europea de Madrid empleando las siguientes palabras clave: *“restoration and root canal treatment”*, *“endodontic teeth”*, *“Indirect restoration”*, *“Post in endodontic teeth”*, *“Ferrule on dental teeth”*, *“Direct restoration in endodontic teeth”*, *“Characteristics of endodontic teeth”* y *“Endocrown”*.

Una vez realizada la revisión bibliográfica se elaboró una tabla de Excel para comparar los distintos resultados de los artículos.

Utilizando los siguientes filtros: artículos publicados en revistas de impacto publicados entre 2000-2020. Se han buscado un total de 150 artículos, de los que 22 se han excluido por estar duplicados, y 57 se han excluido por el título. Se ha revisado los resúmenes de 71 artículos, 29 han sido excluidos tras haber sido revisado los resúmenes. Se han revisado un total de 47 artículos completos y hecho un resumen y conclusión de cada uno de ellos, de los cuales 25 han sido seleccionados para la elaboración de este estudio. (Fig. 3)



**Fig. 3.** Esquema de la selección bibliográfica para la realización de este estudio.

### **En cuanto a la investigación clínica:**

Se trata de un estudio retrospectivo, observacional, descriptivo y transversal a 1 año, sobre historias clínicas de pacientes adultos sometidos a tratamiento endodóntico en 2019 por los alumnos de grado en la Policlínica Universitaria de la Universidad Europea de Madrid.

Se ha recogido los datos de todas las endodoncias realizadas en la policlínica de la Universidad Europea de Madrid durante todo el año 2019. Se han clasificado según los dientes tratados y según su arcada, el grado de

destrucción que presentan, las causas de la endodoncia, de la destrucción coronaria, y según cómo han sido reconstruidos.

### **Consideraciones éticas**

El protocolo para la realización de este estudio con título "**Estudio retrospectivo de los tipos de reconstrucción del diente endodonciado realizadas en la clínica de grado en 2019**" fue aprobado por el Comité de ética de Investigación de la Universidad Europea de Madrid el 14 de octubre de 2020, asignándole el código interno CIPI/20/168.

Los investigadores niegan cualquier conflicto de interés con este estudio.

### **Pacientes seleccionados**

Los **criterios de inclusión** han sido los que se detallan a continuación:

- Los casos de endodoncia realizados en la Clínica Odontológica de la Universidad Europea de Madrid por los alumnos de grado en 2019 (enero a diciembre de 2019) en pacientes mayores de edad puesto que los casos complejos tanto de endodoncias en dientes con anatomía compleja y segundos molares como de retratamientos y tratamientos quirúrgicos son derivados al máster de endodoncia de la propia universidad al no ser requisito docente de los alumnos de grado.

### **Criterios de exclusión:**

- Los casos de endodoncia que se realizaron en menores de edad (en total 11).
- Los casos de endodoncia que tuvieron que ser derivados por su dificultad durante el tratamiento (en total 8).

- Los casos de endodoncia que antes de terminar el tratamiento se decidió su extracción (en total 1).
- Los casos de endodoncia que se empezaron pero no se terminaron (en total 5).

### Descripción y recogida de las variables

Las variables fueron recogidas en una tabla excel: número de diente, grupo dentario (incisivos, caninos, premolares y molares), tipo de arcada (maxilar/mandibular), causa (caries, obturación profunda, obturación filtrada, desgaste, fractura y motivos protésicos) y grado de destrucción dentaria ( grado I-IV y completa según el número de paredes afectadas), tiempo (días) transcurridos entre la finalización de la endodoncia y la reconstrucción definitiva, tipo de reconstrucción (sin restaurar, restauración directa o combinación directa e indirecta) y tipo de materiales empleados. (Tabla 6) Cuando alguna de las variables no estaba reflejada en la historia clínica del paciente, se dejaba la celda de la hoja excel vacía.

**TABLA 6. TABLA DE VARIABLES**

VARIABLE	DEFINICIÓN	TIPO DE VARIABLE	CATEGORÍA/UNIDADES DE MEDIDA
<b>DIENTE</b>	Número de diente según numeración FDI	Cuantitativa discreta	Numeración dentaria:
			1.1,1.2,1.3,1.4,1.5,1.6,1.7
			2.1,2.2,2.3,2.4,2.5,2.6,2.7
			3.1,3.2,3.3,3.4,3.5,3.6,3.7
	4.1,4.2,4.3,4.4,4.5,4.6,4.7		
<b>CAUSA DESTRUCCIÓN</b>	Causa que ha originado la destrucción del diente	Cualitativa Opciones múltiples	Caries Obturación Obturación + caries



			Fractura
			Desgaste
			Tallado
			1 pared
			2 paredes
<b>GRADO DE DESTRUCCIÓN</b>	Cantidad de destrucción del diente	Cuantitativa	3 paredes
			4 paredes
			Completa
	<p>Tiempo total transcurrido entre finalización de la endodoncia y la reconstrucción completa (Suma de los dos tiempos de abajo)</p>		
<b>TIEMPO ENTRE ENDODONCIA Y RECONSTRUCCIÓN</b>	Tiempo transcurrido entre finalización de la endodoncia y la restauración directa	Cuantitativa discreta	Días
	<p>Tiempo transcurrido entre la restauración directa y la restauración indirecta</p>		
<b>TIPO DE RECONSTRUCCIÓN COMPLETA</b>	Tipo de reconstrucción realizada	Cualitativa	Restauración directa Restauración directa+indirecta Sin restaurar

<b>TIPO DE RECONSTRUCCIÓN</b>	Restauración directa	Cualitativa	Obturación simple (clase I y V)
	Restauración indirecta		Obturación compleja (II, III, IV) Gran reconstrucción Poste+reconstrucción Incrustación (inlay, endocrown, onlay y overlay) no específica Corona
<b>MATERIAL RESTAURACIÓN</b>	Material empleado en la restauración directa	Cualitativa	Composite Poste de fibra+composite
	Material empleado en la restauración indirecta		Composite en incrustaciones Metal-porcelana en coronas

Tres observadores participaron en la recogida de los datos.

Esos datos fueron recogidos de la historia clínica específica de cada paciente, de la evolución escrita del tratamiento y de la observación de las radiografías de periapicales del caso.

En todo momento se veló por el cumplimiento con la Ley de Protección de datos y de Confidencialidad del Investigador. Todos los pacientes que acuden a la Clínica Odontológica firman un documento en que se le indica que sus datos podrán ser empleados con fines científicos y de investigación y que los alumnos acceden a la historia clínica (Anexo 1. Consentimiento para acceso a la historia clínica por los alumnos). Se elaboraron dos bases de datos disociadas para el

estudio, una desprovista de datos personales, en la que los pacientes se identificaron por un número de caso (no número de historia clínica, ni iniciales, ni similar) y otra que vincule los datos identificativos personales con el código del paciente para el estudio.

### **Análisis estadístico**

Se han descrito las características de la muestra estudiada. Para ello, se han calculado frecuencias absolutas (n) y relativas (%) de las variables cualitativas, y la media $\pm$  desviación estándar (SD) o la mediana y rango intercuartílico (RIC) de las variables cuantitativas en función de su comportamiento paramétrico (prueba de normalidad de Shapiro Wilk).

#### 4. RESULTADOS

En el estudio realizado por la Policlínica de la Universidad Europea de Madrid se han evaluado un total de 355 dientes reconstruidos tras una endodoncia. 97 (27,32%) eran incisivos, 46 (12,96%) caninos, 34 (9,58%) era molares y 178 (50,14%) premolares. (fig. 4)

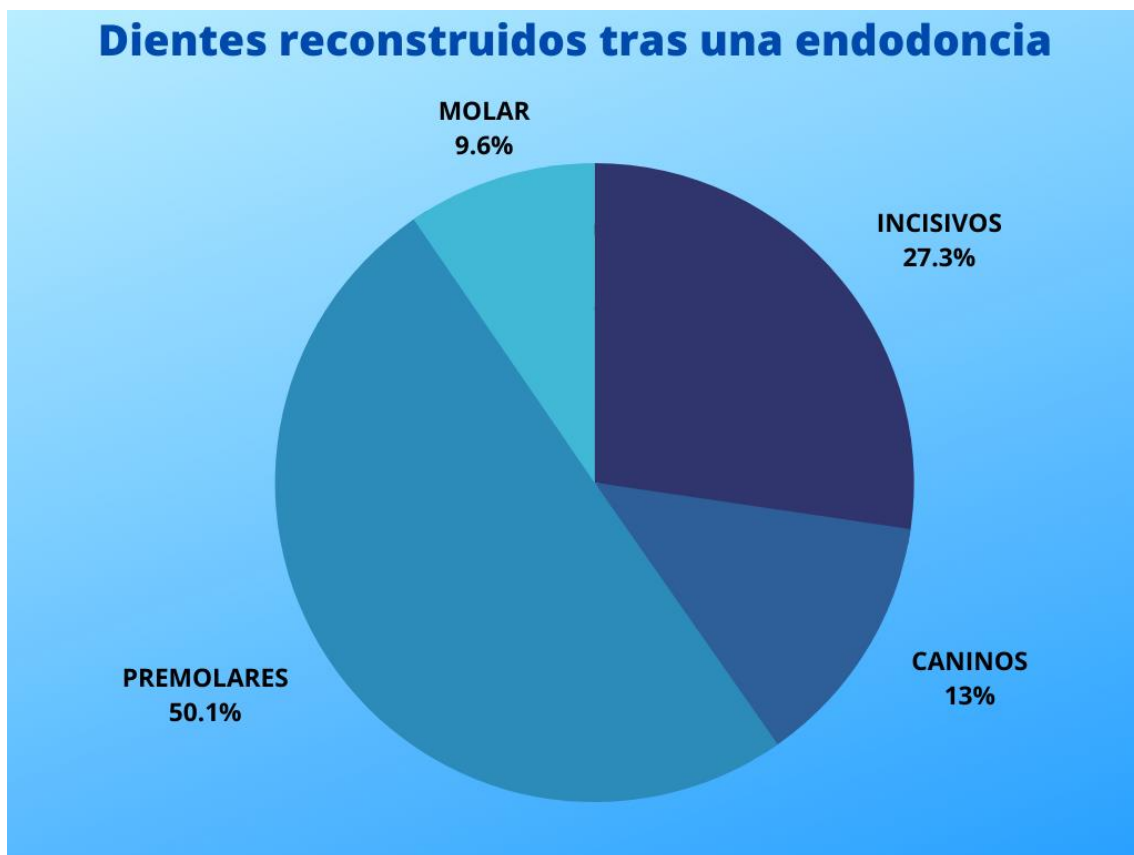
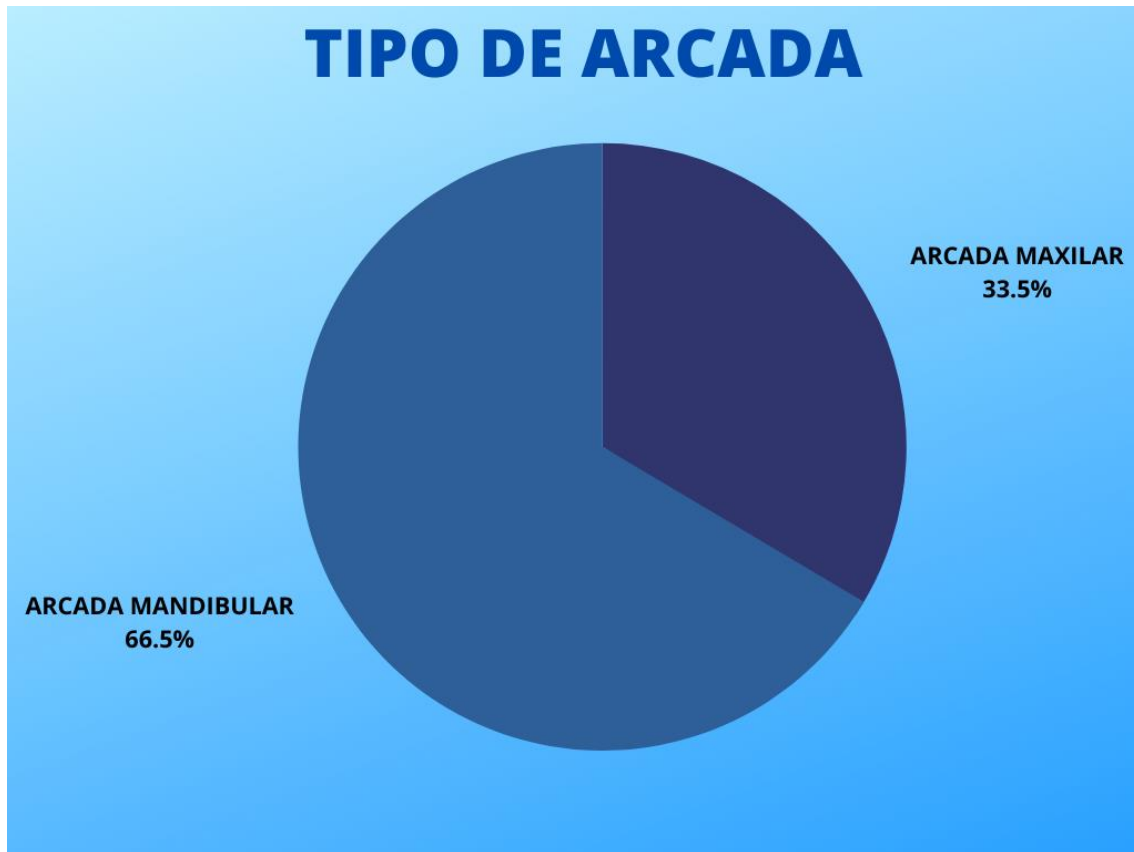


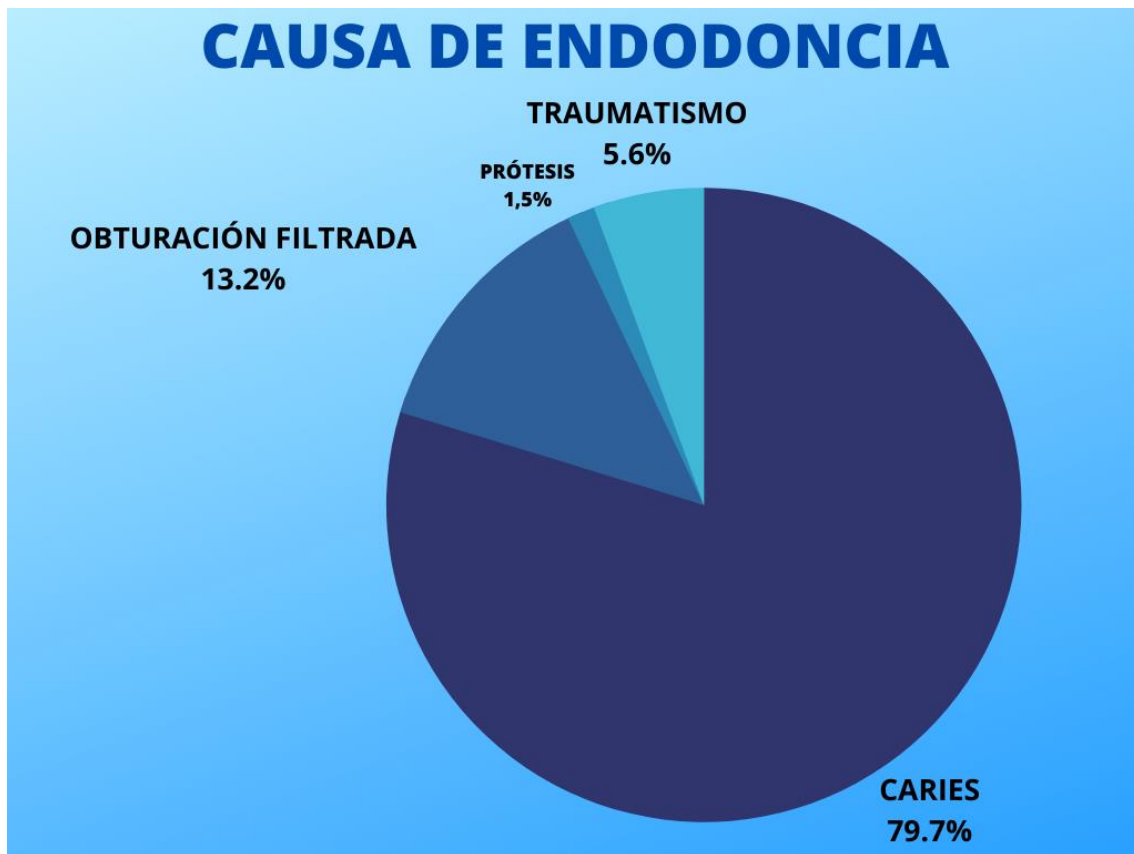
Fig. 4. Gráfico circular de los grupos de dientes tratados

De los 355, 119 (33,52%) eran dientes de la arcada mandibular y 236 (66,48%) de la arcada maxilar. (fig.5)



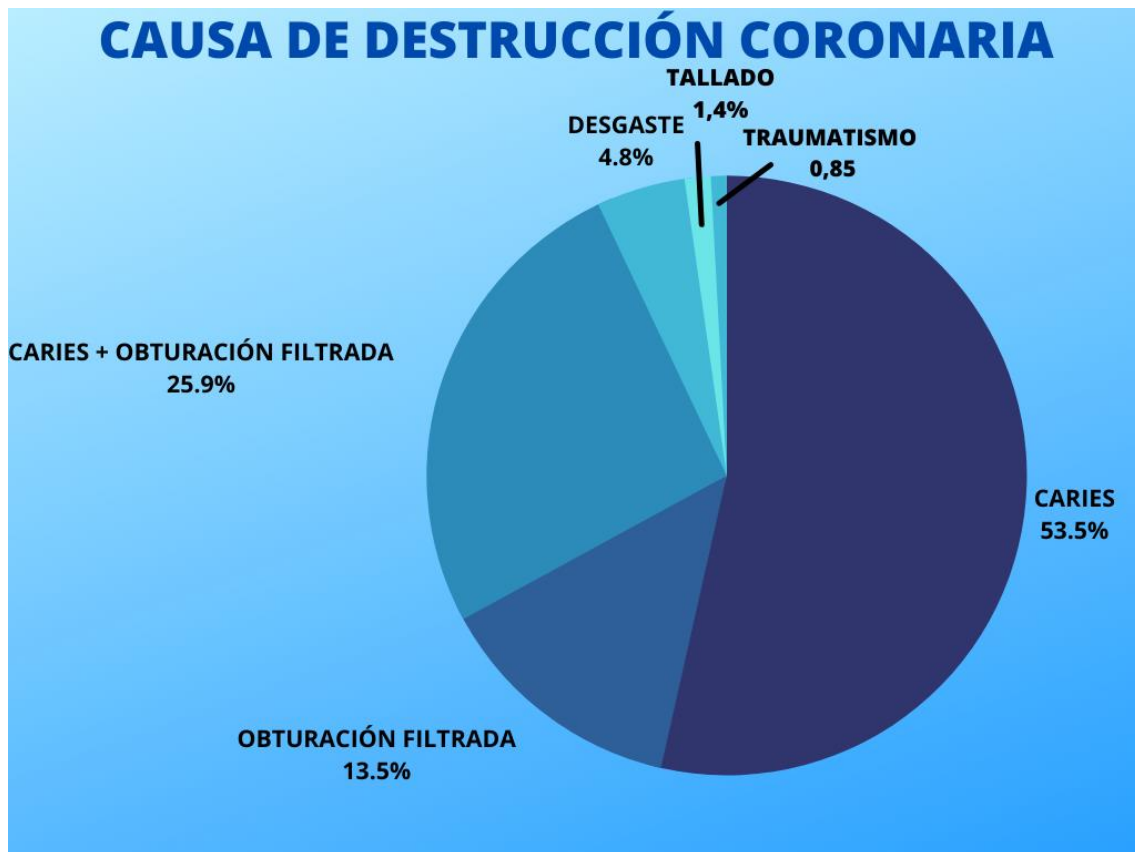
**Fig. 5.** Gráfico circular de la clasificación de los dientes según la arcada

Hubo varios motivos para la realización de las endodoncias; 283 casos (79,72%) fueron derivadas de caries, 47 (13,24%) causada por la obturación, 5 (1,41%) por culpa de la prótesis y 20 (5,63%) por traumatismos. (Fig.6)



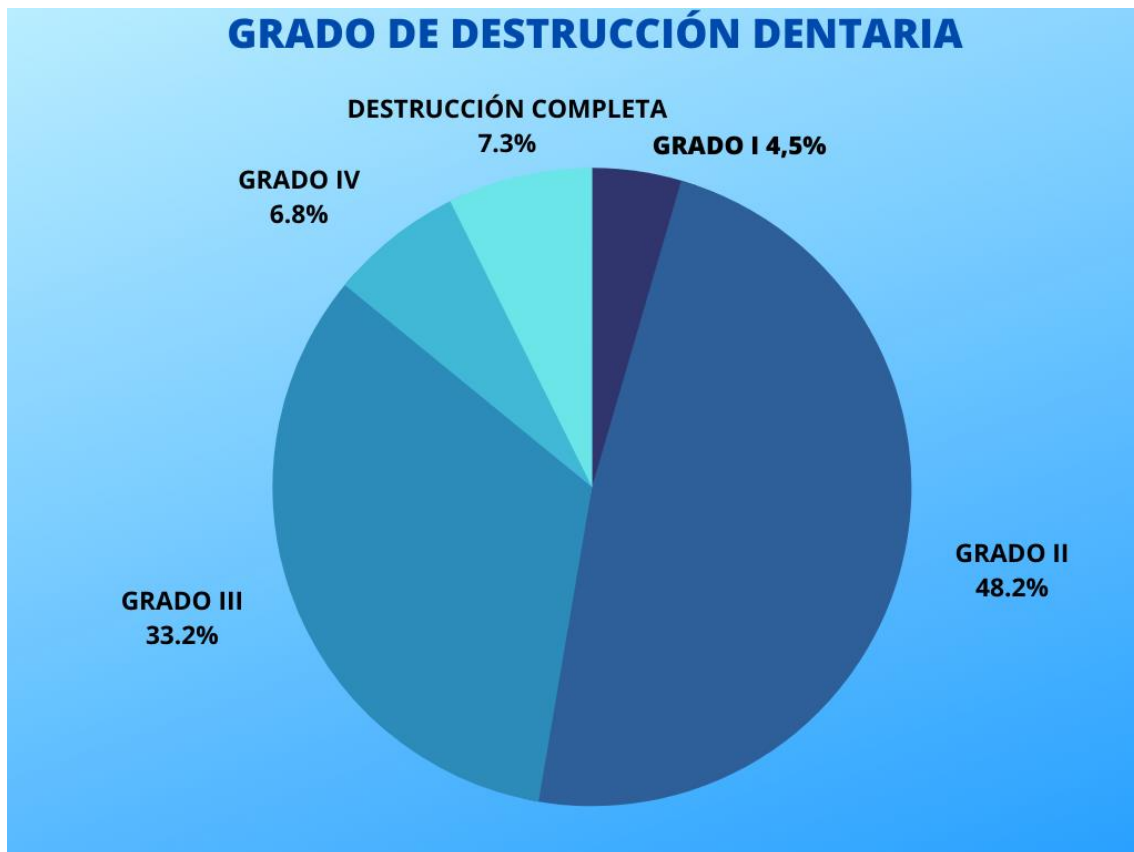
**Fig. 6.** Gráfico circular de la clasificación de los dientes según la causa de endodoncia.

Las causas de la destrucción de la corona encontradas en este estudio, fueron 190 (53,52%) casos por caries, 48 (13,52%) por obturación, 92 (25,92%) por caries y obturación, 17 (4,79%) por desgaste, 3 (0,85%) casos por fractura y 5 (1,41%) por tallado. (Fig. 7)



**Fig. 7.** Gráfico circular de la clasificación de los dientes según la causa de destrucción coronal.

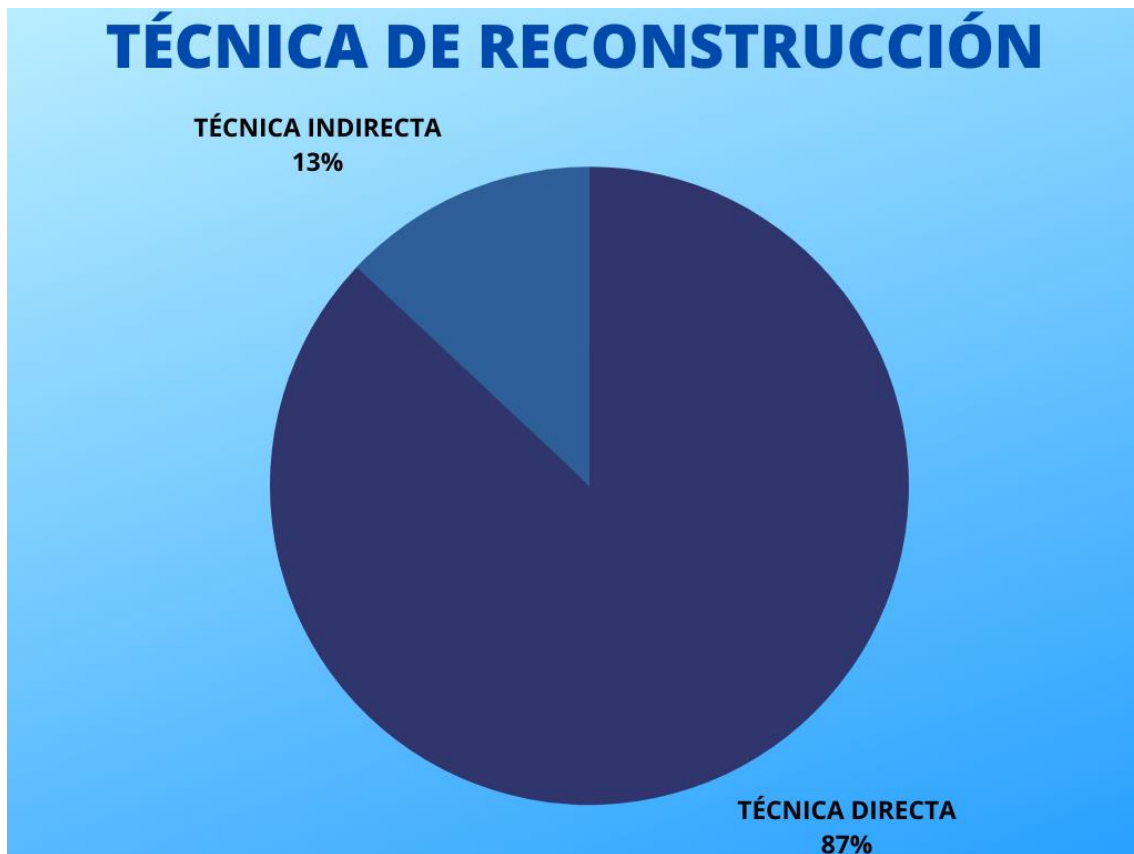
Según el grado de destrucción dentaria se distinguen varios casos: grado I con 16 (4,51%) casos, grado II con 171 (48,17%) casos, grado III con 118 (33,24%) casos, grado IV con 24 (6,76%) y completa 26 (7,32%). (Fig.8)



**Fig. 8.** Gráfico circular de la clasificación de los dientes según el grado de destrucción

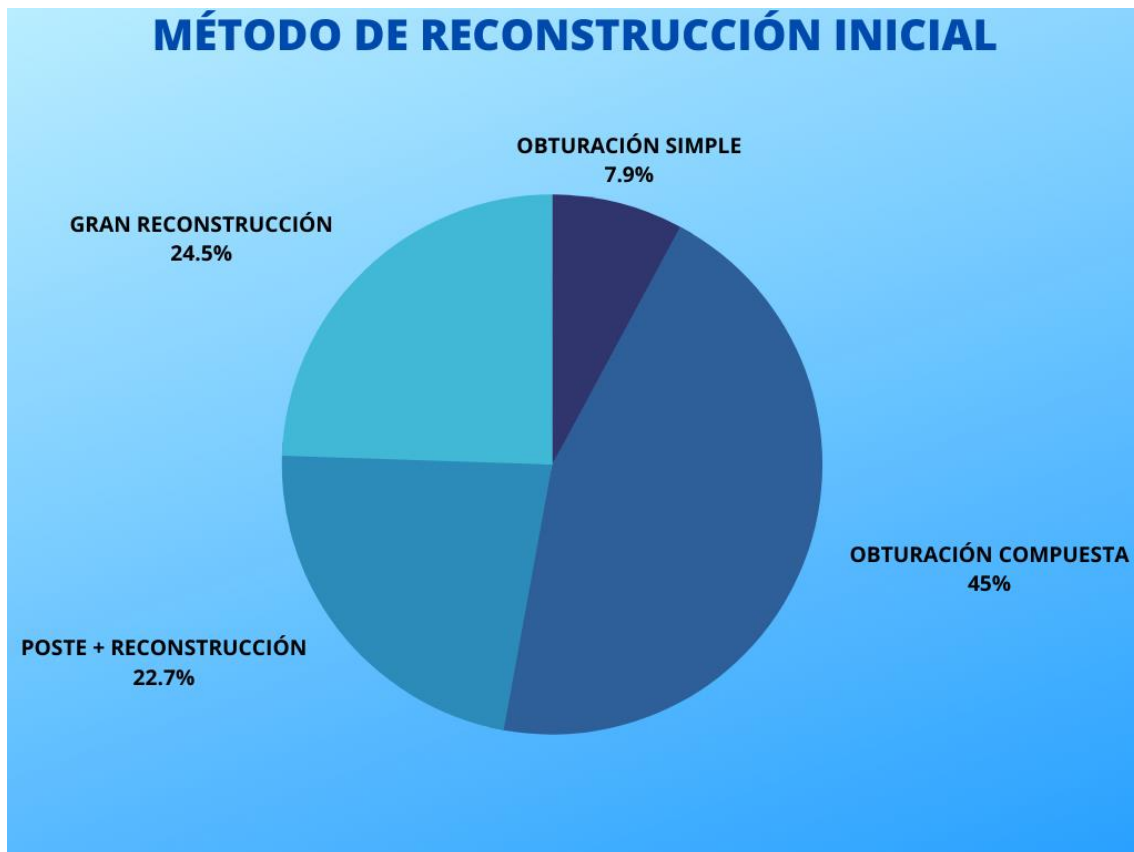
De los 355 casos, 331 se han reconstruido de manera completa y 24 no. De estos 331 casos que se han reconstruido completamente, 288 (87,01%) han sido restauraciones directas y 43 (12,99%) restauraciones directas e indirectas. (Fig.9)





**Fig. 9.** Gráfico circular de la clasificación de los dientes según el tipo de reconstrucción

A continuación, diferenciaremos los 331 casos que se han reconstruidos de manera completa según los métodos de reconstrucción, ya sea en la reconstrucción inicial o en la final en los casos que fueron necesarios: según el método del primer tipo de reconstrucción, 26 (7,85%) casos fueron obturados de manera simple, 149 (45,02%) con obturaciones complejas, 75 (22,66%) con poste y reconstrucción y 81 (24,47%) con una gran reconstrucción. (Fig. 10)



**Fig. 10.** Gráfico circular de la clasificación de los dientes según el método de reconstrucción inicial

Los materiales en este primer tipo de reconstrucción fueron 260 (78,55%) casos con composite, y 71 (21,45%) con poste de fibra y composite.

Hubo un total de 45 casos en los que fue necesario un segundo método de reconstrucción, en la que todas fueron restauraciones indirectas, en 20 (44,44%) casos se usaron coronas de metal-porcelana y 25 (55,56%) casos incrustaciones de composite.

En el análisis de los datos obtenidos podemos observar datos muy curiosos y significativos en los dientes tratados ya que un porcentaje muy alto (50,14%) de los dientes tratados fueron premolares, cabe destacar que las

endodoncias complicadas de molares son derivadas a la clínica del máster, y de ahí que su porcentaje sea tan bajo (9,58%).

También hay que destacar que sólo un tercio de los dientes tratados fueron mandibulares, teniendo una clara mayoría de dientes maxilares.

## 5. DISCUSIÓN

El principal motivo de la realización de una endodoncia coincide entre la revisión literaria y el estudio realizado, ya que la causa principal es la caries (>79%) seguida por la filtración de obturaciones (>13%)<sup>1</sup>.

Casi todos los autores explican que un buen sellado coronal y una buena técnica de endodoncia, son los factores más importantes para determinar el éxito de la endodoncia, así como la elección del material.<sup>2,3,4,5</sup>

El estado periodontal influye directamente en el éxito de la endodoncia, varios autores coinciden que un periodonto sano tiene una tasa más alta de probabilidad de éxito en la endodoncia<sup>1,6</sup>.

También se ha demostrado que la cantidad de tejido remanente del diente influye directamente en el pronóstico de la endodoncia, siendo el grado I el más favorable, y el de destrucción completa el más desfavorable<sup>7,8,9,10</sup>(Tabla 3). Según los datos recogidos los casos más comunes eran con una pérdida de tejido dentario de grado II (48,17%) y grado III (33,24%).

La preservación del tejido coronario también afecta al efecto ferrule, el cual es fundamental tanto para el éxito de la endodoncia como para la supervivencia del diente<sup>8,10,11,12</sup>. (Tabla 3)

Un diente endodonciado no es como un diente sano, tras la pérdida de tejido, el diente endodonciado se vuelve más débil, las cargas funcionales se ven alteradas y son más rígidos y menos flexibles que los dientes sanos, haciéndolos más predisponentes a la fractura. Además, al perder parte de la propiocepción del diente, hace que estos dientes tengan que soportar hasta dos veces más las

cargas oclusales. Un diente endodonciado también puede ver comprometida su estética debido al cambio de color que pueden sufrir<sup>13,15</sup>.

Con respecto al tiempo máximo de espera para realizar la restauración definitiva tras la endodoncia, se han encontrado discrepancias, varios artículos revisados afirman que el tiempo transcurrido para la reconstrucción tras la endodoncia ha de ser lo antes posible<sup>3</sup>, en cambio, un estudio realizado por Kwang y cols.<sup>17</sup> afirma que el tiempo máximo de espera entre el tratamiento endodóntico y la restauración coronaria, puede llegar a ser de 9 meses<sup>17</sup>.

Según los datos recogidos, los dientes con mayor índice de endodoncia en la policlínica de la Universidad Europea de Madrid son los premolares (>50%), cabe destacar que molares con raíces curvadas o con gran destrucción, así como retratamientos de conductos, son derivados a la clínica de Máster de la Universidad Europea de Madrid, y hay un mayor número de dientes maxilares (>66%) que dientes mandibulares

En este estudio, los casos en los que se ha reconstruido el diente de manera directa comparados con los datos recogidos del grado de destrucción dentaria, podemos observar que la técnica directa está bien usada en contraposición de la técnica indirecta, dejando sólo 45 casos en los que se ha realizado técnica indirecta, y según la literatura revisada, el uso de restauraciones indirectas en casos de grados altos de destrucción dentaria favorece el pronóstico de la endodoncia<sup>8,10,11,12</sup>.(Tabla 3, Tabla 5).

Se ha detectado un número demasiado amplio de grandes reconstrucciones con técnica directa, que según la literatura, tienen mal pronóstico en comparación con técnicas indirectas<sup>8,10</sup>.

El uso de incrustaciones en grados bajos de destrucción dentaria, con recubrimiento cuspídeo en las cúspides afectadas y en las cúspides activas en casos en los que el diente tiene una anatomía normal y bajo índice de caries, puede mejorar significativamente el pronóstico de la endodoncia<sup>22</sup>.

En los casos en los que se ha colocado poste en la Policlínica, se ha realizado en una cita diferente a la de la endodoncia. Por el tiempo en el que los alumnos tardan en realizar los tratamientos no es posible realizar el tratamiento endo-restaurador a la vez. Aunque recientemente Eyogoblu y cols (2020) han observado que realizarlo en la misma cita puede incrementar el dolor postoperatorio debido al efecto acumulativo de ambos tratamientos.

El número de casos realizados de poste concuerdan con la literatura revisada, en cambio, el uso de técnicas indirectas está muy por debajo de las recomendadas según la literatura<sup>10,19,20</sup>. (Tabla 5)

El poste usado en la policlínica es el poste de fibra, lo cual concuerda con la literatura revisada<sup>19,20</sup>.

Tras comparar todos estos datos obtenidos en la policlínica de la Universidad Europea de Madrid en el año 2019 con la literatura revisada, podemos observar que en cuanto a los grados de destrucción del diente y el tipo de reconstrucción seleccionada, hay discrepancias a los de los artículos revisados a la hora de hacer este estudio con respecto a la técnica indirecta. Los casos en los que se usó técnica directa como restauración definitiva con los datos recogidos de grados de destrucción dentaria se contraponen con la literatura revisada. El número de casos en los que se seleccionó la técnica

indirecta para la reconstrucción final es demasiado bajo en contraposición de la técnica directa.

#### 5.1 Propuesta de protocolo de actuación para la reconstrucción de un diente endodonciado en la policlínica de la Universidad Europea de Madrid

##### a) Conocer el estado pulpar del diente.

Para ello realizaremos las pruebas de vitalidad, percusión, palpación y sondaje, además de la radiografía periapical. En caso de que la pulpa esté sana o pulpitis reversible, no se realizará la endodoncia.

##### b) Realizar la endodoncia.

Se realizará la endodoncia eliminando los tejidos afectados y siendo lo más conservadores posibles, siguiendo siempre los pasos del protocolo del alumno de la policlínica de la Universidad Europea de Madrid.

##### c) ¿Cuándo realizar la reconstrucción del diente?

Se realizará en la siguiente cita a la endodoncia, evitando períodos de tiempo excesivamente extensos.

##### d) ¿Cómo realizar la reconstrucción del diente?

En este paso tendremos en cuenta el tejido remanente del diente y el material que se usará.

##### d.1 Diente con grado 1 (4 paredes intactas)

En este caso se realizará una reconstrucción directa con composite.

##### d.2 Diente con grado 2 (3 paredes intactas).

Se diferencian dos opciones:

Técnica directa con composite.

Tiene buen pronóstico y permite conferir al diente la anatomía deseada. Técnica de elección en pacientes con poca higiene oral o si el diente va a servir como diente pilar de una prótesis.

d.2.2 Incrustación onlay de composite.

Buen pronóstico. Se usa cuando el diente tiene una anatomía normal y con suficiente retención. Los pacientes deben tener una buena higiene oral y está contraindicado en pacientes con alto índice de caries o si el diente va a servir como diente pilar de una prótesis.

e. Diente con grado 3 (2 paredes intactas)

Se diferencian dos opciones:

e.1 Poste de fibra y reconstrucción de composite.

Tratamiento de elección. Buenos resultados y buen pronóstico

e.2 Poste de fibra, reconstrucción de composite y corona.

Se usará en los casos en que haya poco tejido remanente, tejido remanente débil, o casos en los que el paciente tenga un alto índice de caries.

En caso del sector anterior se hará una corona de porcelana por ser más estética y en posterior de metal-porcelana para soportar mejor las fuerzas de oclusión.

f. Diente con grado 4 (1 pared intacta)



El tratamiento de elección será de poste de fibra, reconstrucción de composite y corona.

En caso del sector anterior se hará una corona de porcelana por ser más estética y en posterior de metal-porcelana para soportar mejor las fuerzas de oclusión.

g. Diente con toda la corona afectada.

g.1 Endocrown

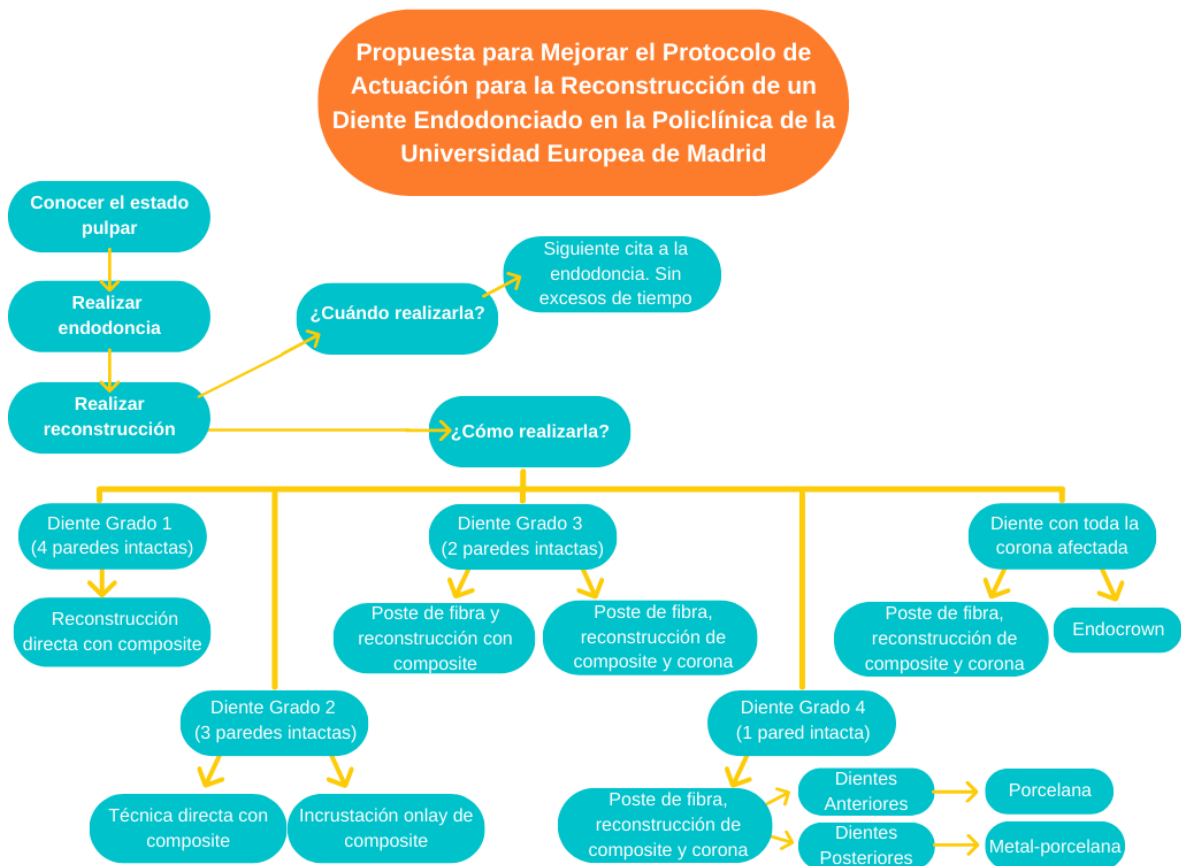
Se usa solo en dientes posteriores, mejores resultados en molares que en premolares. Es el mejor tratamiento de en estos casos siempre que se cumpla que el diente tenga una buena retención en la cámara pulpar. El material será de composite o por CAD-CAM de disilicato de litio.

Contraindicaciones del endocrown:

- Mala retención pulpar.
- Que no se pueda asegurar una buena adhesión.
- Sector anterior.

g.2 Poste de fibra, reconstrucción de composite y corona

Tratamiento de elección en sectores anteriores o premolares. En caso del sector anterior se hará una corona de porcelana por ser más estética y en posterior de metal-porcelana para soportar mejor las fuerzas de oclusión.



**Fig. 11.** Esquema de la propuesta para mejorar el protocolo de actuación para la reconstrucción de un diente endodonciado.

## 6. CONCLUSIÓN

Tras comparar la literatura revisada y los datos obtenidos en el estudio podemos determinar que:

- 1) La mayoría de las reconstrucciones completas tras la endodoncia han sido restauraciones directas (87,01%), un total de 288 casos, de los cuales 26 casos fueron obturados de manera simple, 149 con obturaciones complejas, 75 con poste y reconstrucción y 81 con una gran reconstrucción. Sólo en 45 casos se realizaron restauraciones indirectas. 24 casos han quedado sin restaurar
- 2) Gracias al estudio y a la revisión literaria de la reconstrucción de dientes endodonciados, hemos propuesto un protocolo de tratamiento para la policlínica de la Universidad Europea de Madrid. (Fig.11)
- 3) La causa de destrucción dentaria más frecuente que afecta a los dientes endodonciados de los pacientes tratados por los alumnos de grado en 2019 es la caries (79,72%) seguido de obturaciones filtradas (13,24%)
- 4) Hemos determinado el grado de destrucción del diente en función del tejido remanente, siendo grado I, cuando todas las paredes están sanas, grado II cuando hay una pared afectada, grado III cuando hay dos paredes afectadas, grado IV cuando hay tres paredes afectadas y completa cuando todas las paredes del diente están afectadas. En nuestro estudio la mayoría de los casos presentaban grado II (48,17%) y grado III (33,24%)
- 5) El diente que presenta mayor destrucción dentaria según los resultados y que más se ha tratado en la policlínica es el premolar

(50,14%). La arcada maxilar también presenta un mayor índice de casos (66,48%) con respecto a la arcada mandibular (33,52%)

- 6) El tiempo máximo de espera entre el tratamiento endodóntico y la restauración coronaria es de 9 meses, en cambio, también se ha demostrado que realizar la reconstrucción lo antes posible mejora el pronóstico de la endodoncia.
- 7) El porcentaje de dientes endodonciados por los alumnos que no han recibido tratamiento restaurador definitivo fue de un 6,76% del total de los dientes tratados
- 8) En los dientes endodonciados en la policlínica realizadas por los alumnos de grado en 2019 se han usado las siguientes técnicas de reconstrucción: obturación simple, obturación compleja, poste más reconstrucción, una gran reconstrucción, y algunos de estos casos se le han añadido coronas o incrustación, siendo la obturación compleja la opción más usada.
- 9) Los materiales empleados en las reconstrucciones de los dientes endodonciados realizadas por los alumnos de grado en 2019 fueron en su mayoría obturaciones de composite, siendo también usados, el poste de fibra, la incrustación de composite y la corona metal-cerámica.

## 7. PROPUESTAS DE MEJORA

Se ha elaborado una serie de propuestas acorde a las limitaciones que puede tener una policlínica universitaria.

- A) Se ha elaborado una propuesta para el de protocolo de actuación para la reconstrucción de un diente endodonciado en la policlínica de la Universidad Europea de Madrid, anteriormente expuesto.
- B) Fomentar el uso de restauraciones indirectas, como pueden ser las incrustaciones en casos en los que el paciente tenga bajo índice de caries y tenga una anatomía del diente normal.
- C) Disminuir el tiempo entre la finalización de endodoncia y tratamiento restaurador para mejorar el pronóstico. En ocasiones debido a festivos y festividades, los tiempos entre citas pueden alargarse demasiado, empeorando el pronóstico. Para ello debemos elaborar un mejor plan de tratamiento para evitar que esto ocurra, en caso de que sea inevitable, sellar la entrada a conductos con composite fluido.
- D) En los casos en que sea posible, realizar la reconstrucción de la endodoncia el mismo día de la endodoncia, aunque por los tiempos de trabajo que se manejan en la policlínica es complicado.
- E) Hacer controles de los casos con seguimiento anual. Esto mejoraría la fidelización del paciente, el pronóstico, y nos ayudaría a conocer qué técnicas tienen mayor índice de éxito en una policlínica universitaria.
- F) Concienciar al paciente de la importancia de la reconstrucción final tras la endodoncia. El objetivo debe ser que no quede ninguna endodoncia sin la restauración final, para ello debemos explicar muy bien al paciente las consecuencias que puede conllevar el no hacerlo.

## **Bibliografía**

1) Monardes H, Lolas C, Aravena J, González H, Abarca J. Evaluación del tratamiento endodóntico y su relación con el tipo y la calidad de la restauración definitiva. Rev Clínic Perio, Implan, Rehab Oral [Internet]. 2016 [citado 3 diciembre de 2020]; 9(2):108-113.

2) Mannocci F, Cowie J. Restoration of endodontically treated teeth. British Dent J [Internet]. 2014 [citado 5 diciembre de 2020]; 216(6): 341-346.

3) Pratt I, Aminoshariae A, Montagnese T, Williams K, Khalighinejad N, Mickel A. Eight-Year Retrospective Study of the Critical Time Lapse between Root Canal Completion and Crown Placement: Its Influence on the Survival of Endodontically Treated Teeth. J Endo. 2016; 42(11): 1598-1603.

4) Gomes A, Nejaim Y, Silva A, Haiter-Neto F, Cohenca N, Zaia A y cols. Influence of Endodontic Treatment and Coronal Restoration on Status of Periapical Tissues: A Cone-beam Computed Tomographic Study. J Endo [Internet]. 2015 [citado 16 marzo de 2021]; 41(10):1614-1618.

5) Heling I, Gorfil C, Slutzky H, Kopolovic K, Zalkind M, Slutzky-Goldberg I. Endodontic failure caused by inadequate restorative procedures: Review and

treatment recommendations. J of Prosthodontics [Internet]. 2002 [citado 10 diciembre de 2020]; 87(6):674-678.

6) Zabalegui B, Zabalegui I. Síndrome de pérdida ósea alveolar. Concepto diagnóstico para la toma de decisión en endodoncia, periodoncia e implantología. Rev Perio Clin: SEPA [Internet]. 2017; 9 (14).

7) Corsentino G, Pedullà E, Castelli L, Liguori M, Spicciarelli V, Martignoni M, Ferrari M, Grandini S. Influence of Access Cavity Preparation and Remaining Tooth Substance on Fracture Strength of Endodontically Treated Teeth. J Endod [Internet]. 2018 [citado 12 diciembre de 2020]; 44(9):1416-1421. Disponible en: <https://doi.org/10.1016/j.joen.2018.05.012>.

8) Atlas A, Grandini S, Martignoni M. Evidence-based treatment planning for the restoration of endodontically treated single teeth: importance of coronal seal, post vs no post, and indirect vs direct restoration. Quintessence Int [Internet]. 2019 [citado 16 marzo de 2021]; 50(10): 772-781. Disponible en: <https://doi.org/10.3290/j.qi.a43235>.

9) Soares C, Rodrigues M, Faria-e-Silva A, Santos-Filho P, Veríssimo C, Kim H y cols. How biomechanics can affect the endodontic treated teeth and their restorative procedures?. Brazilian Oral Research [Internet]. 2018 [citado 16 marzo de 2021]; 32 (1).

10) Ferrari M, Vichi A, Fadda G, Cagidiaco M, Tay F, Breschi L y cols. A Randomized Controlled Trial of Endodontically Treated and Restored Premolars. *J of Dental Research* [Internet]. 2012 [citado 16 marzo 2021]; 91(7): S72-S78.

11) Naumann M, Schmitter M, Frankenberger R, Krastl G. "Ferrule Comes First. Post Is Second!" Fake News and Alternative Facts? A Systematic Review. *J Endo* [Internet]. 2018 [citado 14 marzo de 2021]; 44(2):212-219. Disponible en: <https://doi.org/10.1016/j.joen.2017.09.020>.

12) Juloski J, Radovic I, Goracci C, Vulicevic Z, Ferrari M. Ferrule Effect: A Literature Review. *J Endo* [Internet]. 2012 [citado 10 marzo de 2021]; 38(1):11-19

13) Carvalho MA, Lazari PC, Gresnigt M, Del Bel Cury AA, Magne P. Current options concerning the endodontically-treated teeth restoration with the adhesive approach. *Braz Oral Res* [Internet]. 2018 [citado 16 marzo de 2021]; 32(1): e74. Disponible en: <https://doi.org/10.1590/1807-3107bor-2018.vol32.0074>.

14) Timmerman A, Parashos P. Bleaching of a Discolored Tooth with Retrieval of Remnants after Successful Regenerative Endodontics. *J Endo* [Internet]. 2018 [citado 16 marzo de 2021]; 44(1): 93–97. Disponible en: <https://doi.org/10.1016/j.joen.2017.08.032>



15) Galeote F, Dominguez A, Cañadas D. Aprovechamiento de raíces en prostodoncia fija (I). Rev Euro de Odonto-Estoma. 2002; 14 (3):129-136.

16) Eliyas S, Jalili J, Martin N. Restoration of the root canal treated tooth. British Dental J [Internet]. 2015 [citado 16 marzo de 2021]; 218(2): 53-62.

17) Kwang S, Aminoshariae A, Harding J, Montagnese T, Mickel A. The Critical Time-lapse between Various Restoration Placements and Subsequent Endodontic Intervention. J Endo [Internet]. 2014; 40(12): 1922-1926.

18) Zarow M, Ramírez-Sebastia A, Paolone G, de Ribot Porta K, Mora J, Espona J, Duran-Sindreu F, Roig M. A New Classification System for the Restoration of Root Filled Teeth. Inter Endo J [Internet]. 2018 [citado 16 marzo de 2021]; 51: 318-334. Disponible en: <https://doi.org/10.1111/iej.12847>

19) Schwartz R, Robbins J. Post Placement and Restoration of Endodontically Treated Teeth: A Literature Review. J Endo [Internet]. 2004; 30(5):289-301.

20) von Stein-Lausnitz M, von Stein-Lausnitz A, Reissmann DR, Roggendorf MJ, Beuer F, Naumann M, Sterzenbach G. Impact of endodontic post material on longitudinal changes in interproximal bone level: a randomized controlled pilot

trial. Clin Oral Investig [Internet]. 2019 [citado 4 abril de 2021]; 23(5): 2303-2311. Disponible en: <https://doi.org/10.1007/s00784-018-2698-1>.

21) Shu X, Mai QQ, Blatz M, Price R, Wang XD, Zhao K. Direct and Indirect Restorations for Endodontically Treated Teeth: A Systematic Review and Meta-analysis, IAAD 2017 Consensus Conference Paper. J Adhes Dent [Internet]. 2018 [citado 4 abril de 2021]; 20(3):183-194. Disponible en: <https://doi.org/10.3290/j.jad.a40762>.

22) Azeem RA, Sureshababu NM. Clinical performance of direct versus indirect composite restorations in posterior teeth: A systematic review. J Conserv Dent [Internet]. 2018 [citado 16 marzo de 2021]; 21(1):2-9. Disponible en: [https://doi.org/10.4103/JCD.JCD\\_213\\_16](https://doi.org/10.4103/JCD.JCD_213_16).

23) Govare N, Contrepolis M. Endocrowns: A systematic review. J Prosthet Dent [Internet]. 2020 [citado 16 marzo de 2021]; 123(3): 411-418.e9. Disponible en: <https://doi.org/10.1016/j.prosdent.2019.04.009>.

24) Peumans M, Van Meerbeek B, Lambrechts P, Vanherle G. Porcelain veneers: a review of the literature. J Dentistry. 2000; 28(3):163-177.

25) Bremer BD, Geurtsen W. Molar fracture resistance after adhesive restoration with ceramic inlays or resin-based composites. Am J Dent [Internet]. 2001 [citado 5 abril de 2021]; 14(4):216-20. PMID: 11699740

## Anexos

### CLINICA UNIVERSITARIA UNIVERSIDAD EUROPEA

Este centro pertenece a la Universidad Europea.

Las actividades son realizadas por alumnos de Pregrado bajo supervisión de los Profesores de la Universidad Europea.

Dichas actividades les proporcionan un estudio diagnóstico y un plan de tratamiento global que usted conocerá en detalle y aceptará libremente.

De igual manera será informado/a de los mejores tratamientos previstos para el mantenimiento o recuperación de la salud en su caso particular.

Todos los documentos y registros, que se derivan de esta actividad, son propiedad de la Universidad que los podrá utilizar con fines docentes o científicos, cumpliendo siempre la Ley de Protección de Datos.

Si está usted de acuerdo en aceptar la mutua colaboración que le ofrece la Universidad Europea, le agradecemos firme el presente impreso.

Nombre y Apellidos : .....

D.N.I./N.I.E./Nº Pasaporte : .....

Firma:

Fecha : .....

Los datos que se faciliten a la UNIVERSIDAD en virtud del presente documento serán tratados por el responsable del tratamiento, UNIVERSIDAD EUROPEA DE MADRID, S.L.U., con las finalidades de guardar registro de su historial médico, ofrecerle un servicio de diagnóstico y tratamiento médicos, así como remitirles cualquier información relativa a los servicios prestados y actividades de la Policlínica. La base para el tratamiento de los datos personales facilitados al amparo del presente documento se encuentra en el desarrollo y ejecución de la relación formalizada con el titular de los mismos, así como en el cumplimiento de obligaciones legales de UNIVERSIDAD EUROPEA DE MADRID, S.L.U. y el consentimiento inequívoco del titular de los datos. Los datos facilitados en virtud del presente documento se incluirán en un fichero automatizado y mixto cuyo responsable es UNIVERSIDAD EUROPEA DE MADRID, S.L.U., con domicilio en la C/ Tajo s/n, 28670 Villaviciosa de Odón. Asimismo, de no manifestar fehacientemente lo contrario, el titular consiente expresamente el tratamiento automatizado total o parcial de dichos datos por el tiempo que sea necesario para cumplir con los fines indicados. El titular de los datos tiene derecho a acceder, rectificar y suprimir los datos, limitar su tratamiento, oponerse al tratamiento y ejercer su derecho a la portabilidad de los datos de carácter personal, todo ello de forma gratuita, tal como se detalla en la información completa sobre protección de datos en el enlace <https://madrid.universidadeuropea.es/proteccion-de-datos>. El titular de los datos podrá revocar el consentimiento otorgado para la recepción de comunicaciones comerciales o promocionales, en cualquier momento, dirigiéndose a UNIVERSIDAD EUROPEA DE MADRID, S.L.U., en la dirección de su domicilio social en la C/ Tajo s/n, 28670, Villaviciosa de Odón (Madrid) o enviando un mensaje de correo electrónico a la dirección [di@universidadeuropea.es](mailto:di@universidadeuropea.es), indicando en el asunto la referencia "Revocación de consentimiento".



Anexo 1. Consentimiento para acceso a la historia clínica por los alumnos.



TRABAJO DE INVESTIGACIÓN

Evaluación del tratamiento endodóntico y su relación  
con el tipo y la calidad de la restauración definitiva



Héctor Monardes<sup>a,\*</sup>, Claudia Lolas<sup>b</sup>, Juan Aravena<sup>b</sup>, Héctor González<sup>c</sup> y Jaime Abarca<sup>d</sup>

<sup>a</sup> Facultad de Odontología, Universidad San Sebastián, Santiago, Chile

<sup>b</sup> Programa de Especialización en Endodoncia, Facultad de Odontología, Universidad San Sebastián, Santiago, Chile

<sup>c</sup> Programa de Especialización en Rehabilitación Oral, Universidad Andrés Bello, Santiago, Chile

<sup>d</sup> Facultad de Odontología, Universidad San Sebastián, Puerto Montt, Chile

Recibido el 9 de octubre de 2015; aceptado el 3 de marzo de 2016

Disponibles en Internet el 8 de abril de 2016

**PALABRAS CLAVE**

Tratamiento de canal  
radicular;  
Éxito endodóntico;  
Restauración  
dentaria;  
Dientes

**Resumen**

**Introducción:** El éxito endodóntico está determinado por la calidad de los tratamientos de canales radiculares y restaurador, en conjunto con la ausencia de signos y síntomas.

**Objetivo:** Determinar el porcentaje de éxito de tratamientos de conductos y su relación con el tipo y la calidad de la restauración coronaria.

**Materiales y métodos:** Se realizó un estudio clínico retrospectivo en donde se evaluaron 227 dientes sometidos a tratamiento de canales radiculares con 4 años de evolución, por un dentista controlador, que realizó el examen clínico y radiográfico de estos dientes, evaluando los signos y síntomas que presentaron y el tipo y la calidad del tratamiento restaurador. Los datos se analizaron mediante el programa estadístico STATA 13.

**Resultados:** En los tratamientos evaluados existe un porcentaje de éxito del 93,85 y un 6,25 de fracaso, además de una asociación significativa en cuanto a que los dientes con una restauración coronaria adecuada, directa o indirecta, están relacionados con tratamientos considerados como exitosos, mediante test de Fisher (valor  $p < 0,01$ ) con un nivel de confianza del 95%.

**Conclusiones:** Los resultados obtenidos en este estudio muestran un alto porcentaje de éxito de los dientes tratados endodónticamente (93,85) y que existe una asociación estadísticamente significativa entre la calidad de la obturación y la sintomatología ( $p < 0,01$ ) con un nivel de confianza del 95%.

© 2016 Sociedad de Periodoncia de Chile, Sociedad de Implantología Oral de Chile y Sociedad de Prótesis y Rehabilitación Oral de Chile. Publicado por Elsevier España, S.L.U. Este es un artículo Open Access bajo la licencia CC BY-NC-ND (<http://creativecommons.org/licenses/by-nc-nd/4.0/>).

\* Autor para correspondencia.

Correo electrónico: [hector.monardes@uss.cl](mailto:hector.monardes@uss.cl) (H. Monardes).

<http://dx.doi.org/10.1016/j.jco.2016.03.004>

0718-5391/© 2016 Sociedad de Periodoncia de Chile, Sociedad de Implantología Oral de Chile y Sociedad de Prótesis y Rehabilitación Oral de Chile. Publicado por Elsevier España, S.L.U. Este es un artículo Open Access bajo la licencia CC BY-NC-ND (<http://creativecommons.org/licenses/by-nc-nd/4.0/>).

Anexo 2: Monardes H, Lolas C, Aravena J, González H, Abarca J. Evaluación del tratamiento endodóntico y su relación con el tipo y la calidad de la restauración definitiva. Rev Clínic Perio, Implan, Rehab Oral [Internet]. 2016 [citado 3 diciembre de 2020]; 9(2):108-113.

# Restoration of endodontically treated teeth

F. Mannocci<sup>1</sup> and J. Cowie<sup>2</sup>

## IN BRIEF

- Shows that the endodontically treated tooth needs to be restored back to form, function and aesthetics.
- Highlights the choices available to restore both anterior and posterior teeth.
- Provides an update on contemporary adhesive techniques.

PRACTICE

The restoration of endodontically treated teeth has undergone significant changes in the last 20 years. Most of these changes are associated with the preservation of tooth structure, this has been achieved first of all with the increasing use of operative microscopes, nickel titanium instruments and more recently cone beam computed tomography; these instruments have allowed the clinicians to reduce significantly the amount of coronal and radicular hard tooth tissue removed in the process of cutting access cavities. The use of composites has also allowed the clinicians to restore with adhesive techniques teeth that would otherwise require extensive and destructive mechanical retentions. The use of partial crowns is becoming increasingly popular and this also helps prevent tooth structure loss. This article will focus on the choices available to restore both anterior and posterior teeth and will focus more on these contemporary adhesive techniques.

The completion of root canal treatment does not signal the end of patient management. The endodontically treated tooth needs to be restored back to form, function and aesthetics. The quality of the coronal restoration will directly impact on the survival and success of the endodontically treated tooth. The provision of a restoration with a good coronal seal has been suggested to reduce the risk of failure of a root canal treated tooth by reducing bacterial microleakage into the recently cleaned, shaped, and filled root canal system.<sup>1</sup>

Additionally, provision of a well-executed restoration will return the tooth to form and function, re-establish proximal contacts and occlusal stability as well as protecting the tooth from future breakdown, both non-carious (fracture) and carious.

The restoration of endodontically treated teeth has changed in recent years. The availability of adhesive techniques has increased the clinician's repertoire in terms of restoring teeth. Amalgam cores and cast metal posts are being replaced by direct composite and fibre-posts, all ceramic crowns and composite resin crowns are often chosen because of their superior aesthetic outcomes.

This article will focus on the choices available to restore both anterior and posterior

teeth and will focus more on these contemporary adhesive techniques.

## EFFECTS OF ENDOODONTIC TREATMENT ON THE TOOTH

A tooth that requires endodontic treatment is commonly a tooth that has lost a large volume of tooth tissue and is heavily restored. These teeth are often more prone to fracture. The fracture of endodontically treated teeth may range from a simple cusp fracture all the way to catastrophic root fracture requiring extraction. The loss of marginal ridge/s has been shown to reduce cuspal stiffness. In the case of the MOD cavity, this was to an extent of 63%.<sup>2</sup> In a more recent study using micro-computed tomography a significant reduction in tooth stiffness was noted with an access cavity preparation and more so with a post preparation for a cast metal post. The preparation for a fibre-post proved more conservative and less tooth tissue needed to be removed.<sup>3</sup>

The medicaments and irrigants used during root canal treatment can alter the physical properties of dentine and the prolonged use of calcium hydroxide renders the dentine more brittle and prone to fracture.<sup>4,5</sup> Additionally, non-vital teeth lose proprioception and are less adept at perceiving increased load.<sup>6</sup>

Preservation of coronal tooth tissue without compromising endodontic access is desirable. Adhesive techniques allow the clinician to add to existing, residual tooth tissue and do not require creation of macro-mechanical retention; this permits preservation rather than removal of hard tooth structure.

## TIMING OF THE RESTORATIVE PROCEDURE

The factors to consider in terms of timing of the restorative phase of treatment are:

- Pre-existing endodontic status
- Quality of root canal filling
- Position of tooth in the mouth
- Type of restoration planned.

If root canal treatment has been completed to a technically satisfactory standard and the tooth is asymptomatic free from it is sensible to proceed with the final restoration straight away. This is particularly true when dealing with a previously vital, unerupted tooth. If the tooth was symptomatic that is, tender to biting and on lateral pressure, then delaying the final restoration for a few weeks while the tooth settles would be prudent. If the tooth fails to settle then root canal retreatment may well be required.

If the tooth had a small pre-existing periapical radiolucency (less than 2 mm) then the tooth should be treated in the same manner as the vital tooth. If the tooth had a larger post-operative periapical radiolucency and a good root filling has been completed then a short review period should be considered.

There is conflicting evidence whether the post-operative lesion size has an effect on endodontic success; some authors report it makes no difference,<sup>7,8</sup> while others suggest a larger lesion has a negative effect on outcome.<sup>9,10</sup> A larger lesion might indicate the presence of a higher bacterial load within the root canal. In this scenario a more conservative review approach should be taken.

<sup>1</sup>King's College Dental Institute, London, SE7 8RT

<sup>2</sup>Correspondence to: Dr Francesco Mannocci  
Email: francesco.mannocci@kcl.ac.uk

Received Paper

Accepted 28 January 2014

DOI: 10.1038/dj.bdj.2014.188

<sup>3</sup>British Dental Journal 2014; 218: 343-348

Anexo 3: Mannocci F, Cowie J. Restoration of endodontically treated teeth. British Dent J [Internet]. 2014 [citado 5 diciembre de 2020]; 216(6): 341-346.



# Eight-Year Retrospective Study of the Critical Time Lapse between Root Canal Completion and Crown Placement: Its Influence on the Survival of Endodontically Treated Teeth



Isaac Pratt, DDS, MS,<sup>2</sup> Anita Aminoshariae, DDS, MS,<sup>3</sup> Thomas A. Montagnese, DDS, MS,<sup>4</sup> Kristin A. Williams, DDS, MPH,<sup>1</sup> Navid Khalighinejad, DDS,<sup>2</sup> and Andre Mickel, DDS, MS<sup>2</sup>

**Abstract**

**Introduction:** The purpose of this study was to investigate the effects of factors associated with various coronal restorative modalities after root canal treatment (RCT) on the survival of endodontically treated teeth (ETT) and to assess the effect of time lapse between RCT and crown placement after RCT to form a tooth less hazard model. **Methods:** Computerized analysis was performed for all patients who received posterior RCT from 2008 to 2016 in the graduate endodontic department. Data collected included dates of RCT, type of post-endodontic restoration, and time of extraction if extracted. Teeth that received crown after RCT were also divided into 2 groups: receiving crown before 4 months and after 4 months after RCT. Data were analyzed by using Kaplan-Meier log-rank test and Cox regression model ( $\alpha = 0.05$ ) by using SPSS Statistic 21. **Results:** Type of restoration after RCT significantly affected the survival of ETT ( $P = .001$ ). ETT that received composite/amalgam buildup restorations were 2.29 times more likely to be extracted compared with ETT that received crown (hazard ratio, 2.29; confidence interval, 1.25–4.06;  $P = .005$ ). Time of crown placement after RCT was also significantly correlated with survival rate of ETT ( $P = .001$ ). Teeth that received crown 4 months after RCT were almost 3 times more likely to get extracted compared with teeth that received crown within 4 months of RCT (hazard ratio, 3.38; confidence interval, 1.56–6.33;  $P = .002$ ). **Conclusions:** Patients may benefit by maintaining their natural dentition by timely placement of crown after RCT, which otherwise may have been extracted and replaced by implant because of any delay in crown placement. (J Endod 2016;42:1598–1603)

**Key Words**

Endodontically treated teeth, restoration, root canal treatment, survival analysis, survival rate

Numerous studies have focused on a different set of preoperative, intraoperative, and postoperative factors such as the periapical status, quality of root canal treatment

(RCT), and prosthetic restorability of the tooth that can affect the survival of endodontically treated teeth (ETT) (1–4). Crown and root fractures are among the main causes of tooth loss after RCT (5). This finding might be explained by a catastrophic sequela that has been attributed to reinfection of the root canal system through coronal microleakage or complete loss of coronal tooth structure after crown fracture (6). Consequently, coronal restoration has been considered one of the major factors affecting the survival of ETT (7).

Different clinical studies have investigated the effect of coronal restorations on the outcome of RCT. Ray and Trope (8) concluded that periapical health depends significantly more on the coronal restoration than on the quality of the endodontic treatment. Also, Gillen et al (7) reported that appropriate coronal coverage after RCT is as critical as high-quality RCT for the integrity of the periapical tissue. Analysis from an epidemiology study on extracted ETT notably revealed that 85% had no coronal restorations after RCT (9).

Although studies increasingly emphasize the importance of the coronal seal after RCT, others have questioned the influence of coronal restorations (10). Nevertheless, dental practitioners still debate about the most appropriate restorative modality after RCT that can improve the longevity of ETT (11). Controversy exists regarding the effect of the type of coronal restoration after RCT on the survival of ETT. Aquilino and Caplan (12) reported that ETT not crowned are 6 times more likely to get extracted than teeth crowned after RCT. However, Safavi et al (11) reported that there is no significant difference between the survival of ETT that have been restored with amalgam, composite fillings, or cast crowns.

Considering the importance of coronal restoration on the survival of ETT (3), we performed an extensive search of the literature to gain a deeper understanding of the

**Significance**

This study demonstrated that timing of the crown placement after root canal treatment can significantly affect the survival rate of endodontically treated teeth.

From the Departments of <sup>1</sup>Endodontics and <sup>2</sup>Public Health, Case School of Dental Medicine, Case Western Reserve University, Cleveland, Ohio. Address requests for reprints to Dr Navid Khalighinejad, Department of Endodontics, Case School of Dental Medicine, Case Western Reserve University, Cleveland, OH 44106. E-mail address: nk1226@case.edu  
0090-2394/\$ - see front matter  
Copyright © 2016 American Association of Endodontists.  
<http://dx.doi.org/10.1016/j.jen.2016.08.006>

Anexo 4: Pratt I, Aminoshariae A, Montagnese T, Williams K, Khalighinejad N, Mickel A. Eight-Year Retrospective Study of the Critical Time Lapse between Root Canal Completion and Crown Placement: Its Influence on the Survival of Endodontically Treated Teeth. J Endo. 2016; 42(11): 1598-1603.

## Influence of Endodontic Treatment and Coronal Restoration on Status of Periapical Tissues: A Cone-beam Computed Tomographic Study

Aline C. Gomes, DDS, MSc,<sup>1</sup> Yuri Nejaim, DDS, MSc,<sup>2</sup>  
Amaro I.V. Silva, DDS, MSc, PhD,<sup>3</sup> Francisco Haiter-Neto, DDS, MSc, PhD,<sup>4</sup>  
Nestor Cohenca, DDS,<sup>5</sup> Alexandre A. Zaia, DDS, MSc, PhD,<sup>6</sup> and  
Emmanuel João Nogueira Leal Silva, DDS, MSc, PhD<sup>7</sup>

### Abstract

**Introduction:** This cross-sectional study determined the prevalence of apical radiolucency in 1280 root canal-treated teeth and the correlation between endodontic treatment quality and the presence of coronal restorations with apical radiolucency using cone-beam computed tomographic imaging. **Methods:** Cone-beam computed tomographic scans were analyzed, and teeth were classified as healthy or diseased according to the periapical status. Other factors were also evaluated for their association with the apical diagnosis including sex, quality of endodontic treatment, presence of coronal restorations and posts, and apical level of filling. **Results:** Of the treated teeth, 48.83% were classified as healthy. Only 55.11% of the teeth had endodontic treatment rated as adequate. The quality of endodontic treatment and the presence of coronal restoration were statistically correlated with the presence or absence of an apical radiolucency ( $P < .0007$ ). Combined data revealed that teeth with both adequate endodontic treatment and the presence of coronal restoration showed significantly better apical status than the other combinations ( $P < .001$ ). Canals filled up to 0–2 mm short of the apex had a significantly higher number of teeth rated as healthy compared with overfilled or underfilled cases ( $P = .007$ ). The presence of a post was not found to be a statistical significant factor ( $P = .81$ ). **Conclusions:** Data showed a relatively high prevalence of apical radiolucencies in root canal-treated teeth. The quality of the endodontic treatment, the presence of coronal restoration, and apical extent of the root canal filling were significantly associated with healthy apical tissues. (*J Endod* 2015;41:1614–1618)

### Key Words

Apical radiolucency, cone-beam computed tomography, coronal restoration, cross-sectional studies, root canal therapy

Cross-sectional studies performed in several countries revealed the prevalence of apical radiolucency in root endodontically treated teeth to be relatively high, ranging from 55%–60% (1–12). Ray and Trope (13) examined the radiographs of 1010 endodontically treated teeth and observed the presence of periapical pathology in 39.87% of the cases, showing a strong correlation among the technical quality of endodontic treatment and coronal restoration and apical radiolucency. These statistics are in contrast to the outcome of endodontic treatment obtained in follow-up clinical studies (ie, 90%–95%) (14–16).

Most cross-sectional studies evaluating the apical status of endodontically treated teeth have been performed using 2-dimensional (2D) periapical radiographs (2–9) or panoramic radiographs (10–12). However, current literature has shown the limited diagnostic value of 2D periapical radiographs, especially for determination of the quality of treatment as well as its limitation in the detection of apical radiolucency (17). Cone-beam computed tomographic (CBCT) imaging has the potential to circumvent most of the limitations of 2D radiographs, and its high sensitivity for the detection of bone changes has comparatively disclosed a higher prevalence of apical radiolucency than radiographs (18, 19). A recent clinical study showed a 14 times increase in the periapical radiolucency rate when teeth were assessed with CBCT imaging when compared with periapical radiographs (20).

To the best of our knowledge, there are no studies evaluating the correlation between qualities of endodontic treatment with apical radiolucency using CBCT scanning. The aim of the present study was to assess the prevalence of apical radiolucency in endodontically treated teeth and its correlation to several clinical variables.

### Materials and Methods

#### Study Population

The sample for this cross-sectional prospective study consisted of 454 adult patients who were referred to the oral and maxillofacial radiology department in 2008 requiring 3-dimensional CBCT scanning as part of their dental examination, diagnosis, and treat-

From the <sup>1</sup>Department of Restorative Dentistry, Endodontic Division and <sup>2</sup>Department of Oral Diagnosis, Dental Radiology Division, Piracicaba Dental School, State University of Campinas, Piracicaba, São Paulo, Brazil; <sup>3</sup>Department of Pediatric Dentistry, University of Washington, Seattle, Washington; and <sup>4</sup>Department of Endodontics, School of Dentistry, Grande Rio University (UNIGRAHIED), Rio de Janeiro, Rio de Janeiro, Brazil.

Address requests for reprints to Dr Emmanuel João Nogueira Leal Silva, Rua Venâncio de Oliveira, 61/902, Icaraí, Niterói, RJ, Brazil. E-mail address: [nogueiraemmanuel@hotmail.com](mailto:nogueiraemmanuel@hotmail.com)

0899-2286/5 - see front matter

Copyright © 2015 American Association of Endodontists

<http://dx.doi.org/10.1016/j.jen.2015.07.008>

Anexo 5: Gomes A, Nejaim Y, Silva A, Haiter-Neto F, Cohenca N, Zaia A y cols. Influence of Endodontic Treatment and Coronal Restoration on Status of Periapical Tissues: A Cone-beam Computed Tomographic Study. *J Endo* [Internet]. 2015 [citado 16 marzo de 2021]; 41(10):1614-1618.



## Endodontic failure caused by inadequate restorative procedures: Review and treatment recommendations

Ilana Heling, DMD, MSc,<sup>a</sup> Colin Gorfil, DDS,<sup>b</sup> Hagay Slutzky, DMD,<sup>c</sup> Katarina Kopolovic, DMD,<sup>d</sup> Maya Zalkind, DMD,<sup>e</sup> and Iris Slutzky-Goldberg, DMD<sup>f</sup>

The Hebrew University–Hadassah School of Dental Medicine, Jerusalem; and School of Dental Medicine, Tel Aviv University, Tel Aviv, Israel

A review of the literature was performed to determine whether prompt placement of coronal restorations, including sealing and placement of posts and cores, can positively influence the long-term prognosis of teeth after root canal therapy. Both hand and MEDLINE searches were employed to identify peer-reviewed articles on radicular apical integrity after coronal restorations, especially where root canal space was used for post and core fabrication. A total of 41 articles published between 1969 and 1999 (the majority from the 1990s) were reviewed. The literature suggests that the prognosis of root canal-treated teeth can be improved by sealing the canal and minimizing the leakage of oral fluids and bacteria into the periradicular areas as soon as possible after the completion of root canal therapy. (J Prosthet Dent 2002;87:674-8.)

The biological rationale for endodontic treatment has been studied extensively. Recently, attention has focused on procedures performed after the completion of root canal treatment (RCT) and their impact on the prognosis of root canal therapy. These procedures may result in delayed failures by allowing the passage of microorganisms and their by-products into the apical portion of the root and into the alveolar bone.

Ray and Tropé<sup>1</sup> evaluated the relationship between the quality of coronal restorations and coronal obstruction by examining periapical status radiographs of endodontically treated teeth. They observed that a combination of good coronal restorations and endodontic treatment resulted in fewer periradicular inflammatory lesions, whereas poor coronal restorations and endodontic treatment resulted in the absence of periradicular inflammation in only 18.1% of the teeth examined. Furthermore, when poor endodontic treatments were followed by good permanent restorations that radiographically appeared sealed, the refractant success rate was 67.6%. The authors concluded that apical periodontal health depends significantly more on the coronal restoration than on the technical quality of the endodontic treatment.

During and after the restoration of endodontically treated teeth, contamination of the root canal can occur. A review of the literature was undertaken to identify treatment pitfalls that may compromise the long-term prognosis of teeth with radiographically well-performed endodontic treatments and good coronal restorations. A total of 41 references published in refereed journals between 1969 and 1999 (the majority from the 1990s) were identified through hand and MEDLINE searches. The following influences on apical seal and periapical integrity were reviewed: microleakage of saliva, microleakage after post space preparation, microleakage after post cementation, placement of provisional restorations, placement of permanent restorations, and use of endodontic disinfectants.

### MICROLEAKAGE OF SALIVA

Periapical periodontitis may be caused by either bacteria or endotoxins, the latter being cell wall fragments of Gram-negative bacteria that possess potential inflammatory characteristics. It has been shown that endotoxins from mixed bacterial communities can penetrate the root canal system easily and more quickly than bacteria.<sup>2,3</sup>

Salivary microleakage is considered a major cause of endodontic failure due to bacteria and endotoxin penetration along the root canal filling.<sup>4,5</sup> Magara et al<sup>6</sup> assessed salivary penetration through obturated root canals *in vitro* with 2 methods of analysis: histological stainings (hematoxylin and eosin stain and Brown and Hoppes stain) and dye penetration. A significantly greater penetration of saliva was observed after 3 months of incubation than after only 1 month. Khayat et al<sup>7</sup> isolated microorganisms from obturated root canals after 22 days of exposure to saliva. Both lateral and vertical condensation methods of obturation were

<sup>a</sup>Clinical Associate Professor, Department of Endodontics, The Hebrew University–Hadassah School of Dental Medicine.

<sup>b</sup>Senior Lecturer, Department of Restorative Dentistry, Tel Aviv University School of Dental Medicine.

<sup>c</sup>Clinical Instructor, Department of Restorative Dentistry, Tel Aviv University School of Dental Medicine.

<sup>d</sup>Instructor, Department of Restorative Dentistry, The Hebrew University–Hadassah School of Dental Medicine.

<sup>e</sup>Associate Professor, Department of Prosthodontics, The Hebrew University–Hadassah School of Dental Medicine.

<sup>f</sup>Instructor, Department of Endodontics, The Hebrew University–Hadassah School of Dental Medicine. Head of Endodontics, Medical Corps, Israel Defense Forces.

Anexo 6: Heling I, Gorfil C, Slutzky H, Kopolovic K, Zalkind M, Slutzky-Goldberg I. Endodontic failure caused by inadequate restorative procedures: Review and treatment recommendations. J of Prostho Dentistry [Internet]. 2002 [citado 10 diciembre de 2020]; 87(6):674-678.

# SÍNDROME DE PÉRDIDA ÓSEA ALVEOLAR. CONCEPTO DIAGNÓSTICO PARA LA TOMA DE DECISIÓN EN ENDODONCIA, PERIODONCIA E IMPLANTOLOGÍA.

BORJA ZABALEGUI, ION ZABALEGUI.

**Borja Zabalegui.** Profesor Titular. Patología y Terapéutica Dental. Universidad del País Vasco. Práctica privada Endodoncia Microscópica. Bilbao.

**Ion Zabalegui.** Profesor Colaborador Máster de Periodoncia e Implantes. Universidad Complutense. Madrid. Práctica privada Periodoncia e Implantes. Bilbao.

## RESUMEN

EL CONCEPTO DIAGNÓSTICO PROPUESTO POR ZABALEGUI (2001), y denominado "síndrome de pérdida ósea alveolar" engloba todas aquellas entidades clínicas cuya patología cursa, o puede cursar, con dolor, supuración e impotencia funcional, asociada a la presencia de una imagen radiolúcida, tanto periapical como perirradicular. Las entidades que constituyen este síndrome de pérdida ósea alveolar constituyen una dificultad diagnóstica para el establecimiento de un plan de tratamiento interdisciplinar.

El objetivo de este artículo es describir las entidades que constituyen el "síndrome de pérdida ósea alveolar" y establecer una clasificación basada en las características clínicas de la pérdida del hueso alveolar que ayuden al establecimiento del pronóstico y un plan de tratamiento interdisciplinar.

## INTRODUCCIÓN


EN LA SITUACIÓN CLÍNICA ACTUAL son muchas las variables que intervienen en la toma de decisión de mantener el diente en la arcada, o su extracción y sustitución por una restauración con o sin implante. Este análisis se conoce bajo el nombre de algoritmo endodoncia-periodoncia-implante, que debe considerar aspectos restauradores, periodontales y de origen endodóntico al objeto de tomar la decisión terapéutica.

### Correspondencia a:

Borja Zabalegui  
borja.endo@gmail.com

Anexo 7: Zabalegui B, Zabalegui I. Síndrome de pérdida ósea alveolar. Concepto diagnóstico para la toma de decisión en endodoncia, periodoncia e implantología. Rev Perio Clin: SEPA [Internet]. 2017; 9 (14).

# Influence of Access Cavity Preparation and Remaining Tooth Substance on Fracture Strength of Endodontically Treated Teeth



Giacomo Corsentino, DDS, PhD,<sup>1\*</sup> Eugenio Pedullà, DDS, PhD,<sup>2</sup> Laura Castelli, DDS,<sup>3\*</sup> Marzia Liguori, DDS,<sup>4\*</sup> Valentina Spicciarelli, DDS,<sup>5\*</sup> Marco Martignoni, DDS,<sup>2</sup> Marco Ferrari, DDS, PhD,<sup>6</sup> and Simone Grandini, DDS, MSc, PhD<sup>7</sup>

## Abstract

**Introduction:** The purpose of this study was to assess the impact of access cavity preparation and the remaining tooth substance on the fracture strength of endodontically treated teeth. **Methods:** One hundred sound mandibular first and second molar teeth were selected and divided into 1 control and 9 test groups ( $n = 10$ /group) as follows: control group, intact teeth; group 1, teeth prepared with traditional endodontic access cavity (TEC); group 2, teeth prepared with conservative endodontic access cavity (CEC); group 3, teeth prepared with truss endodontic access cavity (TREC); group 4, TEC + 3 residual walls; group 5, CEC + 3 residual walls; group 6, TREC + 3 residual walls; group 7, TEC + 2 residual walls; group 8, CEC + 2 residual walls; and group 9, TREC + 2 residual walls. After access cavity preparation, all test teeth were endodontically treated and restored. The specimens were then loaded to fracture in a universal loading machine (Triaxial Tester T400 Digital; Controls srl, Cernusco, Italy), and fracture values were recorded in newtons. The data were analyzed with 2-way analysis of variance and Tukey post hoc analysis for multiple comparisons ( $P < .05$ ). **Results:** Intact teeth were more resistant to fracture than the teeth in all the test groups. No statistically significant differences were found between the 3 tested access cavities ( $P > .05$ ). Significant differences were observed between the different number of residual walls ( $P < .05$ ). **Conclusions:** TRECs do not increase the fracture strength of endodontically treated teeth in comparison with CECs and TECs. Moreover, the loss of mesial and distal ridges reduced the fracture strength of teeth significantly. (*J Endod* 2018;44:1416–1421)

## Key Words

Conservative access cavity, fracture strength, mesio-occlusal-distal cavity, residual walls, truss access cavity

Endodontically treated teeth are more exposed than vital teeth to fracture risk during function (1–4). A large number of factors, especially the loss of dental substance, contribute to this failure (1, 5–9). Endodontic access cavity preparation could influence the quantity of the residual dental substance (10). Consequently, inspired by the minimally invasive dentistry concept (11), conservative endodontic access cavity (CEC) preparation was proposed to preserve tooth structure maximally (11, 12). The CEC technique has been widely described in the literature (13–16). Some endodontists have emphasized this principle by creating “ninja” and “truss” endodontic access cavities (NECs and TRECs, respectively). An NEC consists of a small hole on the occlusal surface that should allow the clinician to find and access all of the canal orifices (16). On the other hand, a TREC consists of direct access from the occlusal surface to each canal orifice, avoiding removal of the whole pulp chamber roof (17). An NEC could compromise the complete removal of the infected pulp tissue as well as make canal shaping more difficult and less safe (16). A TREC, also called orifice-directed dentin conservation access, significantly compromised debridement of the pulp chamber of endodontically treated teeth (18).

It was reported that CEC preparation could increase the strength to fracture of endodontically treated teeth in comparison with a traditional endodontic access cavity (TEC) (7), but at the same time it could compromise instrumentation efficacy in distal canals of mandibular molars (15). Regarding the influence on the strength of endodontically treated teeth, only a previous study evaluated NECs (16), whereas no articles are actually available on TRECs.

The fracture strength of endodontically treated teeth also could be affected by insufficient residual dental substance because of caries that produce the loss of 1 or more dental walls (19, 20). Indeed, it is more clinically common to treat endodontically teeth that have lost structure for several reasons (16). Therefore, the aim of the present study was to evaluate the influence of the loss of the mesial or the mesial and distal walls in combination with TEC, CEC, and TREC preparation on the fracture strength of endodontically treated teeth.

## Significance

The endodontic access cavity design and the loss of 1 or 2 walls reduce the fracture strength of intact teeth. The access cavity designs tested did not influence the fracture strength of treated teeth that was reduced by the loss of 2 marginal walls.

From the Departments of <sup>1</sup>Endodontics and Restorative Dentistry and <sup>2</sup>Prosthodontics, University of Siena, Siena, Italy; <sup>3</sup>Department of General Surgery and Surgical-Medical Specialties, University of Catania, Catania, Italy; and <sup>4</sup>Private Practice, Rome, Italy.

Address requests for reprints to Dr Giacomo Corsentino, Via B Peruzzi n 51/a, 53100, Siena, Tuscany, Italy. E-mail address: giacomo.corsentino@libero.it

0099-2399/5 - see front matter

Copyright © 2018 American Association of Endodontists.

<https://doi.org/10.1016/j.joen.2018.05.012>

Anexo 8: Corsentino G, Pedullà E, Castelli L, Liguori M, Spicciarelli V, Martignoni M, Ferrari M, Grandini S. Influence of Access Cavity Preparation and Remaining Tooth Substance on Fracture Strength of Endodontically Treated Teeth. *J Endod* [Internet]. 2018 [citado 12 diciembre de 2020]; 44(9):1416-1421. Disponible en: <https://doi.org/10.1016/j.joen.2018.05.012>.





## Evidence-based treatment planning for the restoration of endodontically treated single teeth: importance of coronal seal, post vs no post, and indirect vs direct restoration

Alan Atlas, DMD/Simone Grandini, DDS, MSc, PhD/Marco Martignoni, DMD

Every orthograde endodontic procedure requires restoration of the coronal (access) cavity. The specific type of treatment used in individual cases greatly depends on the amount and configuration of the residual coronal tooth structure. In practice there are Class I access cavities as well as coronally severely damaged, even decapitated, teeth and all conceivable manifestations in between. The latest attempts to review results from clinical trials to answer the question of whether post placement or crowning can be recommended for the restoration of

endodontically treated teeth or not are inconclusive. For dental practitioners, this is not a satisfactory result. This appraisal evaluates available evidence and trends for coronal restoration of single endodontically treated teeth with a focus on clinical investigations, where available. It provides specific recommendations for their coronal restoration to assist clinicians in their decision making and treatment planning. (*Quintessence Int* 2019;50:772-781; doi: 10.3290/j.qi.a43235)

**Key words:** coronal restoration, direct restoration, endodontically treated teeth (ETT), endodontics, fiber post, indirect restoration, seal

Every orthograde endodontic procedure requires restoration of the coronal (access) cavity. The specific type of treatment used in individual cases greatly depends on the amount and configuration of the residual coronal tooth structure. In practice there are Class I access cavities as well as coronally severely damaged, even decapitated, teeth and all conceivable manifestations in between.

The latest attempts to review results from clinical trials to answer the question of whether post placement or crowning can be recommended for the restoration of endodontically treated teeth (ETT) or not are inconclusive. For dental practitioners, this is not a satisfactory result.

This appraisal evaluates available evidence and trends for coronal restoration of single ETT with a focus on clinical investigations, where available. It provides specific recommendations for their coronal restoration to assist clinicians in their decision making and treatment planning.

### The importance of coronal restoration for endodontic treatment outcome

Leaking coronal restorations dramatically reduce the chance of endodontic treatment success. Numerous studies by renowned authors provide appropriate evidence, concluding that the coronal restoration is at least as important for apical periodontal health as the quality of the endodontic treatment itself.<sup>1-4</sup>

An early study on the influence of the marginal integrity of coronal restorations on endodontic treatment outcome assessed more than 1,000 teeth radiologically that had undergone endodontic treatment.<sup>1</sup> It was apparent that the absence of apical periodontitis was significantly dependent on the marginal integrity of the coronal restoration; 90% of endodontically sufficiently treated teeth were free of apical foci, assuming these were also restored coronally and a marginal seal achieved. The success rate dropped to 44% for coronal restorations that appeared to have marginal leakage (Fig 1).

Anexo 9: Atlas A, Grandini S, Martignoni M. Evidence-based treatment planning for the restoration of endodontically treated single teeth: importance of coronal seal, post vs no post, and indirect vs direct restoration. *Quintessence Int* [Internet]. 2019 [citado 16 marzo de 2021]; 50(10): 772-781. Disponible en: <https://doi.org/10.3290/j.qi.a43235>.

## How biomechanics can affect the endodontic treated teeth and their restorative procedures?

Carlos José SOARES<sup>1M</sup>  
Monise de Paula RODRIGUES<sup>2M</sup>  
André Luis FÁRIA-E-SILVA<sup>3M</sup>  
Paulo Cesar Freitas SANTOS-FILHO<sup>4M</sup>  
Crisnicaw VERÍSSIMO<sup>5M</sup>  
Hyeon-Cheol KIM<sup>6M</sup>  
Antheunis VERSLUIS<sup>7M</sup>

<sup>1M</sup>Universidade Federal de Uberlândia – UFU, Dental School, Department of Operative Dentistry and Dental Materials, Uberlândia, MG, Brazil.

<sup>2M</sup>Universidade Federal de Sergipe, Dental School, Department of Dentistry, Aracaju, SE, Brazil.

<sup>3M</sup>Universidade Federal de Goiás – UFG, Department of Restorative Dentistry, School of Dentistry, Goiânia, GO, Brazil.

<sup>4M</sup>Pusan National University, School of Dentistry, Department of Conservative Dentistry, Busan, Busan, South Korea.

<sup>5M</sup>University of Tennessee Health Science Center, College of Dentistry, Department of Bioscience Research, Memphis, TE, USA

**Declaration of Interests:** The authors certify that they have no commercial or associative interest that represents a conflict of interest in connection with the manuscript.

**Corresponding Author:**  
Carlos José Soares  
E-mail: carlosjsoares@ufu.br

<https://doi.org/10.1590/1807-3107bor-2018-rc02-0076>

Submitted: May 12, 2018  
Accepted for publication: May 29, 2018  
Last revision: June 13, 2018



**Abstract:** Endodontic treatment is a common dental procedure used for treating teeth which the pulp tissue has become irreversibly inflamed or necrotic as a result of the carious process or dental trauma. This procedure which involves mechanical and chemical preparation of root canal may affect several mechanical and physical properties of the tooth structure. The endodontic treatment can also influence the longevity of the rehabilitation of endodontically treated teeth and biomechanics during the oral function. For restoring endodontically treated teeth several factor and clinical decisions should be observed. The decision of the fiberglass post usage and the restorative materials are related to several factors such as the quantity and quality of remaining dental structure, presence of ferrule, post cementation length and final coronal restoration. In this review, the authors will address the effect of the endodontic treatment procedures on canal shape and mechanical properties of a tooth, and also discuss the parameters and the biomechanical principles of root canal treated teeth.

**Keywords:** Tooth, Nonvital; Root Canal Therapy; Biomechanical Phenomena.

### Introduction

The primary function of the human dentition is the preparation and processing of food through a biomechanical process of biting and chewing. This process is based on the transfer of masticatory forces, mediated through the teeth.<sup>1</sup> The synergism of enamel, coronal dentin and root dentin creates an integrated organ that is capable of supporting high masticatory stresses. Root dentin is an important structure to integrate the dentition with muscle-bone support. Human root dentin has higher flexural strength and more significant inelastic deformation than coronal dentin.<sup>2</sup> Understanding the mechanical behavior of dentin and the detailed relations to the dentinal structure provides insight into the design strategies to recover tooth functions and helps to improve dental restoration techniques, preventing catastrophic failures.<sup>3</sup>

When the tooth crown is structurally compromised by caries or defective restorations, root canal treatment may be necessary to maintain tooth integrity and to provide stability for coronal rehabilitation. Endodontic treatment is mainly purposed to remove the infected tissues and

Anexo 10: Soares C, Rodrigues M, Faria-e-Silva A, Santos-Filho P, Veríssimo C, Kim H y cols. How biomechanics can affect the endodontic treated teeth and their restorative procedures?. Brazilian Oral Research [Internet]. 2018 [citado 16 marzo de 2021]; 32 (1).

# A Randomized Controlled Trial of Endodontically Treated and Restored Premolars

M. Ferrari<sup>1\*</sup>, A. Vichi<sup>1</sup>, G.M. Fadda<sup>1</sup>, M.C. Cagidiaco<sup>1</sup>, F.R. Tay<sup>2</sup>, L. Breschi<sup>3</sup>, A. Polimeni<sup>4</sup>, and C. Goracci<sup>1</sup>

**Abstract:** This *in vivo* study examined the contribution of remaining coronal dentin and placement of a prefabricated (LP) or customized fiber post (ES) to the six-year survival of endodontically treated premolars. A sample of 345 patients provided 6 groups of 60 premolars each in need of endodontic treatment. Groups were classified according to the number of remaining coronal walls before abutment build-up. Within each group, teeth were allocated to one of three subgroups: (A) no post retention; (B) LP; or (C) ES ( $N = 20$ ). All teeth were protected with a crown. Cox regression analysis revealed that fiber post retention significantly improved tooth survival ( $p < 0.001$ ). Failure risk was lower in teeth restored with prefabricated ( $p = 0.001$ ) than with customized posts ( $p = 0.009$ ). Teeth with one ( $p = 0.004$ ), two ( $p < 0.001$ ), and three coronal walls ( $p < 0.001$ ) had significantly lower failure risks than those without ferrule. Similar failure risks existed for teeth without coronal walls, regardless of the presence/absence of ferrule ( $p = 0.151$ ). Regardless of the restorative procedure, the preservation of at least one coronal wall significantly

reduced failure risk (ClinicalTrials.gov number CT01532947).

**Key Words:** fiber posts, clinical trial, luting, restorations, ferrule, failure risk.

## Introduction

Fiber posts have been used clinically as an alternative to metal posts in the restoration of endodontically treated teeth (Ferrari *et al.*, 2000a,b, 2007b; Cagidiaco *et al.*, 2008b; Goracci and Ferrari, 2011). Although *in vitro* tests provide valuable information to predict the clinical outcome of restorative materials and techniques, clinical trials indisputably generate the most reliable evidence. The clinical literature on the use of fiber posts includes retrospective (Fredriksson *et al.*, 1998; Ferrari *et al.*, 2000a, b, 2007a) and prospective studies (Glazer, 2000; Mannocci *et al.*, 2002; Malferrari *et al.*, 2003; Monticelli *et al.*, 2003; Naumann *et al.*, 2005a,b; Ferrari *et al.*, 2007b; Cagidiaco *et al.*, 2008a; Mancebo *et al.*, 2010; Zicari *et al.*, 2011). Different failure rates have been reported for post-endodontic restorations

(Naumann *et al.*, 2005a; Ferrari *et al.*, 2007a,b; Mancebo *et al.*, 2010; Zicari *et al.*, 2011). Among the baseline factors influencing the clinical outcome of restored pulpless teeth, tooth type and position within the dental arch in relation to occlusal forces (Naumann *et al.*, 2005a,b), existence of proximal contacts (Caplan *et al.*, 2002), and the type of final restoration (Aquilino and Caplan, 2002) have been identified to play a relevant role. Moreover, preservation of coronal dental tissues (the so-called 'ferrule effect', a circumferential dentin collar of at least 2 mm in height) has emerged as the critical condition for functioning of post-endodontic restorations (Stankiewicz and Wilson, 2002; Zhi-Yue and Yu-Xing, 2003; Akkayan, 2004; Tan *et al.*, 2005; Pereira *et al.*, 2006; Dietschi *et al.*, 2008; Mancebo *et al.*, 2010; Juloski *et al.*, 2011).

In a Cochrane systematic review on post-retained restorations, the authors advised that clinical protocols should feature well-defined inclusion criteria, including delineation of the number of residual coronal walls, for a clearer assessment of the influence of the remaining tooth structure on treatment

DOI: 10.1177/0022034512447949. <sup>1</sup>Department of Dental Materials and Fixed Prosthodontics of the University of Siena, Tuscan School of Dental Medicine, University of Firenze and Siena, Policlinico 'Le Scotte', viale Bracci, Siena 53100, Italy; <sup>2</sup>Department of Endodontics, College of Dentistry, Georgia Health Sciences University, 1120 15th Street, Augusta, GA, USA; <sup>3</sup>Department of Medical Sciences, University of Trieste, Piazza, Ospedale 1, Trieste 34129, Italy; and <sup>4</sup>Department of Oral Sciences, 'Sapienza' University of Rome, viale Regina Elena 287/A, Roma, Italy; \*corresponding author: ferrari@unisi.it

© International & American Associations for Dental Research

Anexo 11: Ferrari M, Vichi A, Fadda G, Cagidiaco M, Tay F, Breschi L y cols. A Randomized Controlled Trial of Endodontically Treated and Restored Premolars. J of Dental Research [Internet]. 2012 [citado 16 marzo 2021]; 91(7): S72-S78.



# "Ferrule Comes First. Post Is Second!" Fake News and Alternative Facts? A Systematic Review



Michael Naumann, DMD,\* Marc Schmitter, DMD,<sup>†</sup> Roland Frankenberger, DMD,<sup>‡</sup> and Gabriel Krastl, DMD<sup>§</sup>

## Abstract

**Introduction:** Both the role of an endodontic post and the ferrule effect have been discussed for decades. The clinical impact of endodontic posts compared with post-free restoration with or without ferrule support was not systematically reviewed so far. It was assumed that the effect of an endodontic post compared with a post-free restoration can be evaluated only when at the same time a ferrule or no-ferrule situation was clinically compared. **Methods:** The specific PICO question was as follows: Patient: adults with sufficient endodontic treatment needing a core or post; Intervention: post-endodontic treatment using posts with or without ferrule; Comparison: post-endodontic treatment without posts with or without ferrule; Outcomes: failure rates of post/core complexes with or without ferrule support. A Medline search was performed via PubMed in June 2017 using relevant electronic databases. Additionally, hand search was performed. Only prospective clinical studies in humans comparing the success/survival of teeth restored with or without posts over a minimum time of observation of 5 years were included. **Results:** In total, 7 randomized controlled trials and 1 prospective clinical trial met inclusion criteria. Cochrane rating showed high risk of bias in 5 studies. Two of 3 studies support the ferrule-effect concept. Seven of 8 show no post effect. Clinical evidence regarding the influence of tooth location on its survival is scarce. **Conclusion:** Ferrule effect and maintaining cavity walls are the predominant factors with regard to tooth and restoration survival of endodontically treated teeth. Most studies do not confirm a positive effect of post placement. (*J Endod* 2018;44:212–219)

## Key Words

Buildup, clinical trial, core, dowel, endodontically treated teeth, no-post, post-and-core, post-free, post-retained, screw

In contrast to vital teeth, the complication rate of restorations on endodontically treated teeth (ETT) is considerably increased, maybe finally resulting in tooth loss. Therefore, ETTs are often judged as "less valuable" as abutments for prosthodontic restorations

when it comes to reliability and cost-effectiveness compared with vital teeth (1) or implants (2). Systematically reviewed (SR) data over 3 to 25 years showed that survival rates of restorations after endodontic treatment ranged between approximately 81% and 100% (3).

Over the past decades, much research focused on the question of which post-and-core technique/material should be used to increase ETT and restoration survival (4). A wide range of post materials with different mechanical properties, such as cast gold (5), stainless steel (6, 7), titanium (8), zirconia (9), or less rigid materials, such as fiber posts (10) was applied. A recent survey reported that a great variety of options is presently used, also including no post placement depending on the final restoration planned (11). However, unequivocal guidelines do not exist.

The aim of the present SR was to look for high-level clinical evidence comparing post *versus* no-post placement in ferruled and unferruled teeth to distinguish between post and ferrule effect and to exclude the blurring impact of the latter. The null hypothesis was that post placement is superior to post-free restorations (post effect) irrespective of the presence of a ferrule (ie, ferrule effect) for restoration and/or tooth survival.

## Significance

Ferrule effect and maintaining cavity walls are predominant factors with regard to tooth and restoration survival of endodontically treated teeth. Considerable clinical evidence to the influence of the tooth type on the survival of endodontically treated teeth is scarce. Most studies do not confirm a positive effect of post placement for indirect restoration.

## Material and Methods

### PICO Question

The specific PICO question was as follows:

*P (patient):* adults with sufficient endodontic treatment needing a dentin core buildup procedure

*I (intervention):* post-endodontic treatment using posts with or without ferrule support

*C (comparison):* post-endodontic treatment without posts with or without ferrule support

*O (outcomes):* tooth and/or restoration survival

Anexo 12: Naumann M, Schmitter M, Frankenberger R, Krastl G. "Ferrule Comes First. Post Is Second!" Fake News and Alternative Facts? A Systematic Review. *J Endo* [Internet]. 2018 [citado 14 marzo de 2021]; 44(2):212-219. Disponible en: <https://doi.org/10.1016/j.joen.2017.09.020>.

# Ferrule Effect: A Literature Review

Jelena Juloski, DDS,\* Ivana Radovic, DDS, MSc, PbD,<sup>†</sup> Cecilia Goracci, DDS, MSc, PbD,\*  
Zoran R. Vulicevic, DDS, MSc, PbD,<sup>‡</sup> and Marco Ferrari, MD, DDS, PbD\*

## Abstract

**Introduction:** Preserving intact coronal and radicular tooth structure, especially maintaining cervical tissue to create a ferrule effect, is considered to be crucial for the optimal biomechanical behavior of restored teeth. The ferrule effect has been extensively studied and still remains controversial from many perspectives. The purpose of this study was to summarize the results of research conducted on different issues related to the ferrule effect and published in peer-reviewed journals listed in PubMed. **Methods:** The search was conducted using the following key words: "ferrule" and "ferrule effect" alone or in combination with "literature review," "fracture resistance," "fatigue," "finite element analysis," and "clinical trials." **Results:** The findings from reviewed articles were categorized into three main categories: laboratory studies, computer simulation, and clinical trials. Laboratory studies were further classified into subchapters based on the main aspect investigated in relation to the ferrule effect. **Conclusions:** The presence of a 1.5- to 2-mm ferrule has a positive effect on fracture resistance of endodontically treated teeth. If the clinical situation does not permit a circumferential ferrule, an incomplete ferrule is considered a better option than a complete lack of ferrule. Including a ferrule in preparation design could lead to more favorable fracture patterns. Providing an adequate ferrule lowers the impact of the post and core system, luting agents, and the final restoration on tooth performance. In teeth with no coronal structure, in order to provide a ferrule, orthodontic extrusion should be considered rather than surgical crown lengthening. If neither of the alternative methods for providing a ferrule can be performed, available evidence suggests that a poor clinical outcome is very likely. (*J Endod* 2012;38:11–19)

## Key Words

Endodontically treated teeth, ferrule effect, post and core, review

The restoration of endodontically treated teeth involves a variety of treatment options and still represents a challenging task for clinicians. Whether a tooth requires a post or not is determined by the amount of remaining coronal tooth structure and the functional requirements (1). Frequently, the remaining tooth structure is not sufficient, and a post is indicated to provide retention for crown restoration (1–3). Cast post and core systems were the standard for many years. However, demands for simpler procedures and esthetic restorations led to the development of prefabricated posts, initially made from metal and more recently from ceramics and fiber-reinforced composites (FRCs) (1, 4, 5).

A successful clinical outcome of endodontically treated teeth depends on adequate root canal treatment as well as on adequate restorative treatment performed afterwards (6). Therefore, research has focused on finding the most promising post and core system (7–9), luting agent (10–12), and crown type (13, 14). Even though a strengthening effect of the post is desirable and very often needed, it was questioned in the literature (1). Despite extreme efforts to reinforce endodontically treated teeth, biomechanical failures still represent a critical issue (4, 15). The lack of a protective feedback mechanism after pulp removal may be a contributing factor to frequent tooth fractures (16). However, beside noncontrollable risk factors, the high occurrence of fractures may be attributed to various operative procedures, such as access cavity preparation and restoration, root canal preparation, irrigation and obturation, post space preparation, and final coronal restoration (15, 17).

Preserving intact coronal and radicular tooth structure and maintaining cervical tissue to create a ferrule effect are considered to be crucial to optimize the biomechanical behavior of the restored tooth (17, 18). A ferrule effect is defined as a "360° metal collar of the crown surrounding the parallel walls of the dentine extending coronal to the shoulder of the preparation. The result is an elevation in resistance form of the crown from the extension of dentinal tooth structure" (19). More precisely, parallel walls of dentin extending coronally from the crown margin provide a "ferrule," which after being encircled by a crown provides a protective effect by reducing stresses within a tooth called the "ferrule effect" (20) (Fig. 1).

Growing attention has been given to the prognosis of endodontically treated teeth, and, generally, the ferrule effect is considered necessary to stabilize restored tooth (1, 3, 17, 21–24). Then again, the cost of getting this support in teeth with no coronal dentin is the additional loss of tooth tissue, and although a ferrule would be desirable, it should not be provided at the expense of the remaining coronal or root structure (25, 26). However, it is important to bear in mind that a ferrule effect is just one part of the restored endodontically treated tooth that represents a complex system. The clinical performance of the entire complex is also affected by several other factors including the post and core material, the luting agent, the overlying crown, and functional occlusal loads

Anexo 13: Juloski J, Radovic I, Goracci C, Vulicevic Z, Ferrari M. Ferrule Effect: A Literature Review. *J Endo* [Internet]. 2012 [citado 10 marzo de 2021]; 38(1):11-19



## Current options concerning the endodontically-treated teeth restoration with the adhesive approach

Marco Aurélio de CARVALHO<sup>1</sup>  
Priscilla Cardoso LAZARI<sup>2</sup>  
Marco GRESNIGT<sup>3</sup>  
Altair Antoninha DEL BEL CURY<sup>4</sup>  
Pascal MAGNE<sup>5</sup>

<sup>1</sup>Universidade Federal de Goiás – UFG, Dental School, Department of Stomatology Sciences, Goiânia, GO, Brazil.

<sup>2</sup>University of Groningen, University Medical Center Groningen, Direct Restorative Department, Groningen, The Netherlands.

<sup>3</sup>Universidade Estadual de Campinas – Unicamp, Piracicaba Dental School, Department of Prosthodontics and Periodontology, Piracicaba, SP, Brazil.

<sup>4</sup>University of Southern California – USC, Herman Ostrow School of Dentistry, Division of Restorative Sciences, Los Angeles, CA, USA.

**Declaration of Interests:** The authors certify that they have no commercial or associative interest that represents a conflict of interest in connection with the manuscript.

**Corresponding Author:**  
Marco Aurélio de Carvalho  
E-mail: marco\_carv@hotmail.com

<https://doi.org/10.1590/1807-3107bor-2018.vol32.0074>

Submitted: May 10, 2018  
Accepted for publication: May 29, 2018  
Last revision: June 12, 2018



**Abstract:** Adhesive procedures have changed the way to restore endodontically treated teeth (ETT). It started with the shift from cast post-and-core to fiber post. The original focus on strength also shifted towards failure modes, revealing that catastrophic failures are still a concern when restoring endodontically-treated teeth even with fiber posts. As an alternative, postless approaches have been proposed in order to improve the chances of repair. The goal of this critical review is to present a survey of the current knowledge on adhesive approaches to restore endodontically treated teeth with and without extensive coronal tissue loss. The preservation of tooth structure of endodontically treated teeth is paramount. Partial versus full coverage of ETT, the role of the ferrule, the post type effect on catastrophic failures and postless alternatives as endocrowns and postless build-ups are reviewed. There is a consensus that the remaining tooth structure plays an important role in ETT survival, although the current literature still is contradictory on the influence of post type on root fractures as well as the benefits of avoiding a post or partially restoring a tooth. More clinical studies should be carried out with the modern postless adhesive alternatives to conventional approaches.

**Keywords:** Tooth, Nonvital; Dental Materials; Crowns; Dental Restoration Failure; Dental Bonding.

### Introduction

The optimal way to restore teeth after endodontic treatment continues to remain a controversial topic of heated debate to this day. Endodontically treated teeth (ETT) present with significantly different mechanical properties compared to vital teeth.<sup>1,2</sup> The modifications in the biomechanical properties and structural integrity of the teeth are most-likely attributed to the volumetric loss of the hard tissues, extent of carious lesion, fracture propagation, final cavity preparation in addition to the access cavity prior to endodontic therapy.<sup>3,4,5,6,7</sup>

There is still a debate regarding which technique would be ideal for ETT restoration, since those teeth are considered to have a higher risk of fracture than vital teeth.<sup>4,7,8,9,10</sup> From a biomimetic perspective, the preservation and conservation of tooth structure is paramount in maintaining the balance between biological, mechanical, adhesive, functional, and esthetic

Anexo 14: Carvalho MA, Lazari PC, Gresnigt M, Del Bel Cury AA, Magne P. Current options concerning the endodontically-treated teeth restoration with the adhesive approach. Braz Oral Res [Internet]. 2018 [citado 16 marzo de 2021]; 32(1): e74. Disponible en: <https://doi.org/10.1590/1807-3107bor-2018.vol32.0074>.

## Bleaching of a Discolored Tooth with Retrieval of Remnants after Successful Regenerative Endodontics

Aovana Timmerman, BDS, DCD, and Peter Parashos, MDS, PhD

### Abstract

**Introduction:** This report presents the retrieval of remnants from a discolored mandibular right second premolar (tooth #29) of a 17-year-old female after a successful regenerative endodontic procedure (REP). **Methods:** The REP was performed in October 2011. Coronal discoloration became of great concern to the patient at a review visit in 2016. A cone-beam computed tomographic scan was taken to investigate the formation of hard tissues within the root canal as well as a region of no calcified tissue formation. During internal bleaching of tooth #29, a black material with particulate inclusions was retrieved and examined histopathologically. **Results:** Five years after the REP,

there was complete periapical healing, hard tissue formation within the root canal, and complete maturation of the root apex. A hard tissue bridge was noted at the cemento-enamel junction when the pulp chamber of #29 was reaccessed. The remnants retrieved from the pulp chamber were confirmed to be partly mineral trioxide aggregate (MTA). A normal tooth color was achieved after 3 weeks of internal bleaching. **Conclusions:** MTA remnants within the pulp chamber contributed to the tooth discoloration and appear to have obstructed hard tissue formation. A matrix of oxidized regenerated cellulose seems not to hinder tissue regeneration and is resorbed by these tissues. Other materials with color stability should be selected as coronal barriers for REPs to avoid a potential adverse effect of the MTA on the REP outcome and discoloration. (*J Endod* 2017; ■:1–5)

### Key Words

Dens evaginatus, internal bleaching, mineral trioxide aggregate, nonvital bleaching, revascularization, revitalization, tissue regeneration, tooth discoloration, walking bleach

**D**ens evaginatus (DE) is a dental anomaly that occurs during tooth development resulting in protrusion of a tubercle on the occlusal surface of posterior teeth or the lingual surface of anterior teeth (1). Because the tubercle

may extend above the occlusal surface, malocclusion with the opposing tooth occurs as the affected tooth erupts into the dental arches (1). With wear or fracture of the tubercle leading to exposure of dentin or pulp and subsequent ingress of bacteria from the oral cavity, pulp and periapical pathoses may develop. Regenerative endodontic procedures

(REPs) for teeth with necrotic pulps and immature root apices and mostly affected by DE have shown favorable treatment outcomes in recent retrospective cohort studies in comparison with apexification (2, 3).

An unfavorable outcome associated with REPs is potential coronal discoloration, which has been reported in case reports (4), case series (5), and cohort studies (6). Currently, both the American Association of Endodontists (AAE) (7) and the European Society of Endodontology (ESE) (8) have mentioned in their position statements the risk of tooth discoloration after REPs. To minimize the risk of coronal staining, the AAE guidelines have recommended the use of either calcium hydroxide or a low concentration of triple antibiotic paste or double antibiotic paste as the medicament below the cemento-enamel junction (CEJ) and the use of other tricalcium silicate cements besides mineral trioxide aggregate (MTA). The ESE guidelines have mentioned the use of calcium hydroxide as the medicament but still propose the use of either MTA or tricalcium silicate cement beneath the CEJ. However, there are no recommendations in the literature concerning the management of tooth discoloration after an REP. Such discoloration can potentially impact a patient's quality of life and warrants further research.

Tooth discoloration associated with a maxillary central incisor after an REP has been reported, and it was hypothesized that the presence of minocycline within the antibiotic paste had led to the discoloration (5). Remnants retrieved from the pulp canal space after REPs may provide further insight into the reasons for tooth discoloration, but there has been no further investigation on these remnants reported in the literature (9, 10). Internal bleaching has been shown to be a predictable treatment option for discolored maxillary anterior teeth after REPs by leaving part of the MTA barrier (4, 11). This article reports the management of a discolored permanent

### Significance

Regenerative endodontics is incomplete when remnants of MTA obstruct the process of calcification, but oxidized regenerated cellulose seemed not to be a hindrance. This and the discoloration caused by MTA indicate that alternative calcium silicate-based materials should be sought.

From the Melbourne Dental School, University of Melbourne, Melbourne, Victoria, Australia.

Anexo 15: Timmerman A, Parashos P. Bleaching of a Discolored Tooth with Retrieval of Remnants after Successful Regenerative Endodontics. *J Endo* [Internet]. 2018 [citado 16 marzo de 2021]; 44(1): 93–97. Disponible en: <https://doi.org/10.1016/j.joen.2017.08.032>

## Aprovechamiento de raíces en prostodoncia fija (II)

**Autores:** Francisco Galeote Gago, Antonio Domínguez Fresco, Diego Cañadas-Rodríguez

**Localización:** Revista europea de odonto-estomatología, ISSN 0214-8668, Vol. 14, Nº. 4 (JUL-AGO), 2002, págs. 193-202

**Idioma:** español

*Texto completo no disponible (Saber más ...)*

### Resumen

Continuamos con este artículo el estudio iniciado sobre el aprovechamiento de raíces con fines prostodóncicos. Analizamos las distintas posibilidades terapéuticas, los procedimientos de confección en el laboratorio y los materiales empleados en la elaboración de los elementos terapéuticos. En el presente artículo, por lo extensa de la revisión bibliográfica realizada y por los problemas de espacio estudiamos las coronas espigas, los pernos-muñones colados y los pernos prefabricados-muñones colados, analizando los procedimientos clínicos y de laboratorio. PALABRAS CLAVES: Aprovechamiento de raíces. Prótesis fija.

Anexo 16: Galeote F, Domínguez A, Cañadas D. Aprovechamiento de raíces en prostodoncia fija (I). Rev Euro de Odonto-Estoma. 2002; 14 (3):129-136.

# Restoration of the root canal treated tooth

S. Elyas,<sup>1</sup> J. Jalili<sup>2</sup> and N. Martin<sup>3</sup>

VERIFIABLE CPD PAPER

## IN BRIEF

- Provides a synopsis of the effects of root canal treatment on the strength of teeth.
- Summarises the available literature pertaining to the restoration of root filled teeth.
- Shows practitioners in formation on how to choose the appropriate temporary, aesthetic and definitive restorations required for anterior and posterior root filled teeth.

PRACTICE

When considering endodontically treated teeth, the quality of the restoration is important from the outset. It sheds light into possible causes of pulp necrosis or failure of endodontic treatment and influences the outcome of future endodontic treatment. A tooth undergoing endodontic treatment requires an effective coronal seal during and following completion of endodontic treatment. This paper discusses, using the available literature, the maintenance of optimal coronal seal and coronal integrity during and after root canal treatment.

## INTRODUCTION

Root canal treatment involves the removal of necrotic and infected tissue followed by the provision of a well-condensed obturation to prevent further microbial proliferation within the canal system.<sup>1</sup> The potential ingress of microbes into the canal system will compromise the outcome of endodontic treatment. The importance of an effective coronal seal in endodontics is well documented (Table 1).

A root filled tooth is unlike a vital tooth due to the effect of endodontic treatment. It is thought that endodontic treatment leads to 'weakening' of the remaining tooth structure as a result of various factors: changes in tooth architecture, changes in the preparation of dentine and changes in proprioception. Although the effects are similar for both anterior and posterior teeth, the consequences are different due to the difference in tooth morphology and loading patterns.

The changes in tooth architecture are often attributed to the access cavity preparation and removal of the vital tissues, supposedly rendering the tooth weaker and more

Table 1. The importance of a good coronal seal (GR = good endodontics, QR = good restoration)

Study	Measure of coronal seal	No. of teeth	Outcome
Ray & Ingle <sup>2</sup>	Radio	1,000 (no post + crown)	GR more important than QR
Prentiss et al. <sup>3</sup>	Radio	1,000 (post + crown included)	QR more important than GR
Kirkcaldy et al. <sup>4</sup>	Radio	773	Better periapical status with GR
Romero et al. <sup>5</sup>	Exam & radio	740	Better periapical status with GR
Brewer et al. <sup>6</sup>	Radio	1,373	No coronal restoration more periapical status
Seung-Sik et al. <sup>7</sup>	Radio	93	Better periapical status with GR
Teles et al. <sup>8</sup>	Radio	1,006	Better periapical status with GR
Ng et al. <sup>9</sup>	Exam & radio	1,462	Better periapical status with GR

susceptible to fracture. In anterior teeth, no difference in fracture susceptibility of root-filled and non-root-filled anterior teeth has been shown.<sup>4</sup> In posterior teeth endodontic procedures were shown to reduce the stiffness of teeth by 9%, however, the presence of an occlusal restoration reduced stiffness by 20% and the presence of a mesio-occluso-distal restoration reduced tooth stiffness by 67%.<sup>4</sup> It is the loss of the marginal ridges and occlusal lethanas that leads to weakening of teeth.<sup>10</sup> Some have theorised that obtaining straight-line access may weaken adjacent cusps;<sup>11</sup> others have suggested that post preparation removes radicular dentine, which weakens teeth<sup>12</sup> or that excess force during canal obturation causes tooth weakening.<sup>13</sup> However, it must be remembered that most teeth requiring endodontic treatment have already suffered caries, cracks, trauma and previous restorations which may be the cause of weakness.

Proprioception is also purportedly affected by endodontic treatment with higher pain threshold seen in non-vital teeth and therefore increased loading of non-vital teeth. It is thought that proprioception is reduced by 10% after endodontic treatment as a result of pulpal nerves being involved in regulating masticatory load.<sup>14</sup> The periodontal ligament may act as a protective feature. The relevance of loading forces may be more gradient in parafunctional patients as parafunctional loads can be six times the normal chewing force (1.5 to 7 kg) for an excess of 35 minutes in 24 hours, whereas normally teeth come together for chewing and empty swallows (eight minutes) for about 17.5 minutes every 24 hours. Chewing forces are predominantly vertical, but in parafunction they can also be horizontal,<sup>15</sup> though in anterior teeth there is a much greater horizontal vector of force depending on the guidance on the

<sup>1</sup>Senior Consultant in Restorative Dentistry, Sheff Hall Hospital, University Hospital of Leicester NHS Trust, Groby Road, Leicestershire, UK; <sup>2</sup>Operative Registrar in Restorative Dentistry, Charles Clifford Dental Hospital, Sheffield Teaching Hospitals NHS Foundation Trust, Wincobury Road, Sheffield, S12 9SD, UK; <sup>3</sup>Professor and Honorary Consultant in Restorative Dentistry, Academic Unit of Restorative Dentistry, School of Clinical Dentistry, University of Sheffield

<sup>4</sup>Correspondence to: Saba Shajana Elyas Email: shajana@sheffhall.nhs.uk

Received Paper Accepted 12 November 2014 DOI: 10.1038/dj.bdj.2015.37 British Dental Journal 2015; 218: 53-62

Anexo 17: Elyas S, Jalili J, Martin N. Restoration of the root canal treated tooth. British Dental J [Internet]. 2015 [citado 16 marzo de 2021]; 218(2): 53-62.

# The Critical Time-lapse between Various Restoration Placements and Subsequent Endodontic Intervention

Sarab Kwang, DDS, MSD,\* Anita Aminoshariae, DDS, MS,\* Jarrod Harding, MS, MSM,<sup>†</sup>  
Thomas A. Montagnese, DDS, MS,\* and Andre Mickel, DDS, MSD<sup>‡</sup>

## Abstract

**Introduction:** The purpose of this study was 2-fold: (1) to investigate the critical time-lapse of endodontic intervention subsequent to various restorations and tooth surfaces and (2) to assess and compare the risk factors associated with the restorations, tooth surfaces, and endodontic treatment. **Methods:** A comprehensive computerized analysis of all dental school patients at the Case Western Reserve University School of Dental Medicine who received restorations from 2008–2013 was obtained. Inclusion and exclusion criteria were applied. The sample size was limited to teeth with endodontic treatment completed by the endodontic post-graduate dental clinic. Data collected included restoration type, restored tooth surfaces, tooth type, and the dates of restoration and subsequent endodontic treatment. A 2-sample paired *t* test (95% confidence interval, *P* < .05) and pair-wise comparison with Bonferroni corrections were implemented. **Results:** The mean time between restoration placement and resultant endodontic intervention was 270 days, with a mean difference of 247–294 days (*P* < .0001). Further analysis revealed composite resin was 1.91 times more likely than amalgam and 5.69 times more likely than crowns to cause resultant endodontic intervention. Teeth with 2 or more restorative surfaces required endodontic intervention (*P* < .001). **Conclusions:** Of the patients who required endodontic treatment after restoration placement, the critical time-lapse was 9 months. Composite restorations and teeth with 2 or more restorative surfaces were significantly associated with endodontic treatment. From the results of the current study, we recommended that all dental practitioners should perform a thorough endodontic evaluation and diagnosis before, during, and after all restorative procedures. (*J Endod* 2014;40:1922–1926)

## Key Words

Endodontics, restorations, restorative procedure, risk period, time-lapse, treatment time

The ultimate goals of endodontic treatment are the eradication of microbial etiology (1); complete healing of periapical pathosis (2–4); and restoration to provide a coronal seal (5), restore function (6), and prevent reinfection (7). Pulpal inflammation has predominantly been associated with the involvement of microbes (1) and/or dental trauma (8). However, it is a multifactorial reactionary process, and current evidence supports that every element involved in restorative dental procedures can be harmful to the pulp of vital teeth (9–13).

Although there are limitations with modern diagnostic technology (14), determining pulpal vitality before any restorative procedure is recommended to all restorative dental practitioners to aid in the prevention of foreseen complications of patient care before (15, 16), during, and after the procedure.

Patients' perceptions of restorative success include a lack of postoperative sensitivity (17) and for endodontic success a lack of pain (18). Several studies report numerous ways to classify restorative success as symptom free, tooth in function, free of any dental intervention, and tooth survival. In our opinion, with the numerous ways to account for the patients' and dental clinicians' perception of restorative success, essentially, endodontic intervention is perceived as a complication and/or failure (16, 19–22).

A thorough search of the literature showed a varying degree of methodologies, observation periods, patient recall rates, and incidence of endodontic treatment subsequent to the placement of various restorations (16, 22–24). To the best of our knowledge, we found no studies that have reported on a risk time period for endodontic intervention after restoration placement. Is there a critical time period for loss of pulpal deterioration after restorative treatment? Therefore, the purpose of this study was 2-fold: (1) to investigate the critical time-lapse of endodontic intervention subsequent to various restorations and tooth surfaces and (2) to assess and compare the risk factors associated with the restorations, tooth surfaces, and endodontic treatment.

## Materials and Methods

The study design was approved by the Case Western Reserve University Institutional Review Board (CWRU IRB). A computerized search analysis using the General Systems Design Academic software (GSD, Cedar Rapids, IA) was achieved. The American Dental Association code of dental procedures was used to acquire patients who had restorative treatment from January 1, 2008, to December 31, 2013. The search encompassed the dental codes for composite resin, amalgam, buildups, and all fixed full-coverage restorations. Buildups are used when minimal tooth structure remains. They were categorized as a separate restoration because their composition can include amalgam or composite resin restorative materials (at our institution, glass ionomer is not used). An additional search was implemented to include teeth that were associated with the code for nonsurgical root canal therapy after restoration placement. Each tooth that

Anexo 18: Kwang S, Aminoshariae A, Harding J, Montagnese T, Mickel A. The Critical Time-lapse between Various Restoration Placements and Subsequent Endodontic Intervention. *J Endo* [Internet]. 2014; 40(12): 1922-1926.



## A new classification system for the restoration of root filled teeth

M. Zarow<sup>1</sup>, A. Ramirez-Sebastia<sup>2</sup>, G. Paolone<sup>3</sup>, J. de Ribot Porta<sup>2</sup>, J. Mora<sup>2</sup>, J. Espona<sup>2</sup>, F. Duran-Sindreu<sup>2</sup> & M. Roig<sup>2</sup>

<sup>1</sup>Private Practice, Krakow, Poland; <sup>2</sup>Department of Restorative Dentistry and Endodontics, School of Dentistry, Universitat Internacional de Catalunya, Barcelona, Spain; and <sup>3</sup>Dental School, Università Vita e Salute San Raffaele, Milan, Italy

### Abstract

Zarow M, Ramirez-Sebastia A, Gaetano P, de Ribot Porta J, Mora J, Espona J, Duran-Sindreu F, Roig M. A new classification system for the restoration of root filled teeth. *International Endodontic Journal* 51, 318–334, 2018.

The aim of this report is to (i) review the current literature on the status of root filled teeth, (ii) analyse the most important factors in decision-making, (iii) discuss the current restorative concepts, and (iv) classify both the evidence and clinical practice in a way that

seeks to be clear, understandable and helpful for clinicians. Restoration of root filled teeth represents a challenge for the clinician and remains a controversial subject. The guidelines describe a new classification that is drawn from evidence presented in the literature and also from clinical expertise-based reviews. It describes five categories of teeth.

**Keywords:** dental restoration, endodontics, post-and-core technique, root canal treatment.

Received 5 December 2017; accepted 23 August 2017

### Introduction

Restoration of root filled teeth is a controversial subject and a challenge because of the confusing range of opinions presented by dentists and scientists, which makes it difficult to select the most appropriate restorative option (Vire 1991, Morgano *et al.* 1994). The ongoing debate on whether a post is necessary also remains controversial. The aim of this article is to classify both the evidence and clinical practice in a way that seeks to be clear, understandable and helpful for clinicians.

### Current status of root filled teeth

Root filled teeth are structurally and aesthetically compromised (Morgano *et al.* 1994). The loss of tissue

at root and crown levels leads to significant biomechanical changes (Cariso *et al.* 1987, Robbins 1990, Sjögren *et al.* 1990, Peruz *et al.* 2005) resulting in a high incidence of fractures (Sjögren *et al.* 1990). Evidence suggests that fracture of root filled teeth and, in consequence, the risk of tooth loss are considerably higher than that of teeth with vital pulps. Using data from more than 46 000 patients from 28 dental practices, Fennis *et al.* (2002) found a positive correlation between root filled teeth and subgingival fracture location. Loss of internal tooth structure leads to increased cuspal deflection during occlusal function. Deflection is more pronounced in root filled premolars with mesial, occlusal and distal (MOD) cavities, and by doubling the depth of the MOD cavity, the cuspal deflection has been reported to increase by a factor of eight (Hood 1985).

Root filled teeth are more vulnerable to tooth loss than teeth with vital pulps due to the following risk factors:

- Post-treatment disease following root canal treatment (de Chevigny *et al.* 2008).

Correspondence: Fernando Duran-Sindreu, Department of Restorative Dentistry and Endodontics, School of Dentistry, Universitat Internacional de Catalunya (UIC), Sant Cugat del Vallès, Barcelona, Spain (e-mail: fduran@uic.es).

Anexo 19: Zarow M, Ramírez-Sebastia A, Paolone G, de Ribot Porta K, Mora J, Espona J, Duran-Sindreu F, Roig M. A New Classification System for the Restoration of Root Filled Teeth. *Inter Endo J* [Internet]. 2018 [citado 16 marzo de 2021]; 51: 318-334. Disponible en: <https://doi.org/10.1111/iej.12847>

# Post Placement and Restoration of Endodontically Treated Teeth: A Literature Review

Richard S. Schwartz, DDS, and James W. Robbins, DDS, MA

**The restoration of endodontically treated teeth is a topic that is extensively studied and yet remains controversial from many perspectives. This article reviews the major pertinent literature on this topic, with an emphasis on major decision-making elements in post placement and restoration of endodontically treated teeth. Recommendations are made for treatment planning, materials, and clinical practices from restorative and endodontic perspectives.**

There are few subjects in dentistry that have been studied more than the restoration of endodontically treated teeth. Yet, many practical questions and controversies remain in this clinically important element of the treatment plan. Unfortunately, the diversity of published opinions is confusing and may lead to less than optimal treatment selections. Fortunately, there are a number of areas in which the preponderance of research supports specific clinical procedures. The purpose of this review is to organize this topic into its component parts and provide evidence-based principles that are sound from a restorative as well as an endodontic perspective. The article focuses primarily on recent publications, although some of the classic literature also is discussed. With one exception, all the references cited are full-text articles from refereed journals.

## ARE ENDODONTICALLY TREATED TEETH DIFFERENT?

Several classic studies have proposed that the dentin in endodontically treated teeth is substantially different than dentin in teeth with "vital" pulps (1-3). It was thought that the dentin in endodontically treated teeth was more brittle because of water loss (1) and loss of collagen cross-linking (3). However, more recent studies (4, 5) dispute this finding. In 1991, Huang et al. (4) compared the physical and mechanical properties of dentin specimens from teeth with and without endodontic treatment at different levels of hydration. They concluded that neither dehydration nor endodontic treatment caused degradation of the physical or mechanical properties of dentin. Sedgley and Messer (5) tested the

biomechanical properties of dentin from 23 endodontically treated teeth with an average of 10 yr of post treatment. They compared them to their contralateral "vital" pairs. Aside from a slight difference in hardness, the properties were comparable. The study did not support the conclusion that endodontically treated teeth are more brittle.

These and other studies support the interpretation that it is the loss of structural integrity associated with the access preparation, rather than changes in the dentin, that lead to a higher occurrence of fractures in endodontically treated teeth compared with "vital" teeth (6). Access preparations result in increased cuspal deflection during function (7, 8) and increase the possibility of cusp fracture and microleakage at the margins of restorations. In most endodontically treated teeth, there also is missing tooth structure caused by caries or existing restorations. Randow and Glantz (9) reported that teeth have a protective feedback mechanism that is lost when the pulp is removed, which also may contribute to tooth fracture. Fennis et al. (10) studied more than 46,000 patients from insurance claims and reported significantly more fractures in teeth with endodontic treatment. Taken together, these studies indicate that restorations that enhance structural integrity would be expected to increase the prognosis of endodontically treated teeth exposed to heavy masticatory loading forces.

## RESTORATIVE FACTORS THAT AFFECT THE PROGNOSIS OF ENDODONTIC TREATMENT

Contamination of the root-canal system by saliva, often referred to as "coronal leakage" or "coronal microleakage," is a potential cause of endodontic failure (11). In addition, recurrent caries or fractured restorations may lead to recontamination of the root-canal system. Under the best of conditions, the oral environment is rich in microorganisms, and dental restorations must withstand repeated exposure to physical, chemical, and thermal stressors. It is a difficult environment in which to maintain a hermetically sealed system. In vitro studies have shown that exposure of coronal gutta-percha to bacterial contamination can lead to migration of bacteria to the apex in a matter of days (12, 13). Bacterial by-products and endotoxins can penetrate to the apex in an even shorter time than bacteria (14). When the root canal space has been

Anexo 20: Schwartz R, Robbins J. Post Placement and Restoration of Endodontically Treated Teeth: A Literature Review. J Endo [Internet]. 2004; 30(5):289-301.

# Direct or Indirect Restoration of Endodontically Treated Maxillary Central Incisors with Class III Defects? Composite vs Veneer or Crown Restoration



Manja von Stein-Lausnitz<sup>a</sup> / André Mehnert<sup>b</sup> / Maria Bruhnke<sup>c</sup> / Guido Sterzenbach<sup>d</sup> / Martin Rosentritt<sup>e</sup> / Benedikt C. Spies<sup>f</sup> / Kerstin Bitter<sup>g</sup> / Michael Naumann<sup>h</sup>

**Purpose:** The aim of this ex-vivo study was to evaluate the load capacity of direct or indirect endodontically restored maxillary central incisors with Class III defects, with or without glass-fiber posts.

**Materials and Methods:** Seventy-two extracted human maxillary central incisors were endodontically treated and biproximal Class III cavities were prepared. Specimens were randomly allocated to six groups (n = 12): direct restoration with composite (C); direct restoration with composite and additional glass-fiber post (CP); ceramic veneer restoration (V), ceramic veneer restoration and additional glass-fiber post (VP), ceramic crown restoration (Cr), ceramic crown restoration and additional glass-fiber post (CrP). Specimens were exposed to thermomechanical loading (TML: 1.2 million cycles, 1 to 50 N; 6000 thermal cycles between 5°C and 55°C for 1 min each), and subsequently linearly loaded until failure ( $F_{max}$  [N]) at an angle of 135 degrees 3 mm below the incisal edge on the palatal side. Statistical tests were performed using the Kruskal-Wallis and Mann-Whitney U-Test.

**Results:** During dynamic loading by IML, one early failure occurred in group C, CP, and CrP. Subsequent linear loading resulted in mean fracture load values [N] of C =  $483 \pm 219$ , CP =  $536 \pm 281$ , V =  $908 \pm 293$ , VP =  $775 \pm 333$ , Cr =  $549 \pm 258$ , CrP =  $593 \pm 259$ . The Kruskal-Wallis test showed significant differences of load capacity between groups ( $p < 0.05$ ). Mann-Whitney U-test revealed significantly lower maximum fracture load values of group C compared to group V ( $p = 0.014$ ), after Bonferroni-Holm correction. Non-restorable root fracture was the most frequent type of failure.

**Conclusion:** Endodontically treated maxillary central incisors with Class III defects directly restored with composite are as loadable as indirect crown restorations. Compared to full-coverage restorations, less invasive veneers appear to be more beneficial. Additional placement of glass-fiber posts shows no positive effect.

**Keywords:** all-ceramic crown, Class III restorations, direct composite restorations, endodontically treated teeth, indirect restoration, post and core, veneers.

J Adhes Dent 2018; 20: 519-526.  
doi: 10.3290/jad.a41635

Submitted for publication: 02.08.18; accepted for publication: 30.10.18

Anexo 21: von Stein-Lausnitz M, von Stein-Lausnitz A, Reissmann DR, Roggendorf MJ, Beuer F, Naumann M, Sterzenbach G. Impact of endodontic post material on longitudinal changes in interproximal bone level: a randomized controlled pilot trial. Clin Oral Investig [Internet]. 2019 [citado 4 abril de 2021]; 23(5): 2303-2311. Disponible en: <https://doi.org/10.1007/s00784-018-2698-1>.



# Direct and Indirect Restorations for Endodontically Treated Teeth: A Systematic Review and Meta-analysis, IAAD 2017 Consensus Conference Paper

Xin Shu<sup>a</sup> / Qing-qing Mai<sup>b</sup> / Markus Blatz<sup>c</sup> / Richard Price<sup>d</sup> / Xiao-dong Wang<sup>e</sup> / Ke Zhao<sup>f</sup>

**Purpose:** The primary objective of this systematic review was to compare treatment outcomes of direct and indirect permanent restorations in endodontically treated teeth, and provide clinical suggestions for restoring teeth after endodontic treatment.

**Materials and Methods:** Electronic databases (Medline, EMBASE, CENTRAL) and gray literature were screened for articles in English that reported on prospective and retrospective clinical studies of direct or indirect restorations after endodontic treatment with an observation period of at least 3 years. Primary outcomes were determined to be short-term ( $\leq 5$  years) and medium-term ( $> 5$  and  $\leq 10$  years) survival. Secondary outcomes included restorative and endodontic success of restored teeth. The quality of included studies and risk of bias were assessed using Cochrane Collaboration's tool for RCTs (randomized controlled trials), the Newcastle-Ottawa Scale for cohort studies, and the Agency for Healthcare Research and Quality (AHRQ) methodology checklist for cross-sectional studies. The GRADE system was used for assessing collective strength of the overall body of evidence.

**Results:** Of 2547 screened articles, only 9 (2 RCTs, 3 retrospective cohort studies, 3 cross-sectional studies) met the inclusion criteria, and 8 studies were used in the meta-analysis. In general, indirect restorations (mostly full crowns) showed higher 5-year survival (OR 0.28, 95% CI 0.19-0.43,  $p < 0.00001$ ) and 10-year survival (OR 0.20, 95% CI 0.12-0.31,  $p < 0.00001$ ) than direct restorations. However, there was no statistical difference in short-term ( $\leq 5$ -years) restorative success (OR 0.32, 95% CI 0.05-2.12,  $p = 0.24$ ) and endodontic success (OR 0.88, 95% CI 0.72-1.08,  $p = 0.22$ ).

**Conclusions:** Based on current evidence, there is a weak recommendation for indirect restorations to restore endodontically treated teeth, especially for teeth with extensive coronal damage. Indirect restorations using mostly crowns have higher short-term (5-year) and medium-term (10-year) survival than do direct restorations using composite or amalgam (GRADE quality of evidence: low to moderate), but no difference in short-term ( $\leq 5$  years) restorative success (low quality) and endodontic success (very low quality). There is a need for high-quality clinical trials, especially well-designed RCTs.

**Keywords:** endodontic treatment, direct restorations, indirect restorations, survival rates, success rates, apical periodontitis.

*J Adhes Dent* 2018; 20: 183-194.  
doi: ##.###/j.jad.a#####

Submitted for publication: 09.09.17; accepted for publication: 28.03.18

Anexo 22: Shu X, Mai QQ, Blatz M, Price R, Wang XD, Zhao K. Direct and Indirect Restorations for Endodontically Treated Teeth: A Systematic Review and Meta-analysis, IAAD 2017 Consensus Conference Paper. *J Adhes Dent* [Internet]. 2018 [citado 4 abril de 2021]; 20(3):183-194. Disponible en: <https://doi.org/10.3290/j.jad.a40762>.

## Abstract

**Background:** Composite resin, serves as esthetic alternative to amalgam and cast restorations. Posterior teeth can be restored using direct or indirect composite restorations. The selection between direct and indirect technique is a clinically challenging decision-making process. Most important influencing factor is the amount of remaining tooth substance.

**Aim:** The aim of this systematic review was to compare the clinical performance of direct versus indirect composite restorations in posterior teeth.

**Materials and Methods:** The databases searched included PubMed CENTRAL (until July 2015), Medline, and Cochrane Database of Systematic Reviews. The bibliographies of clinical studies and reviews identified in the electronic search were analyzed to identify studies which were published outside the electronically searched journals. The primary outcome measure was evaluation of the survival of direct and indirect composite restorations in posterior teeth.

**Results:** This review included thirteen studies in which clinical performance of various types of direct and indirect composite restorations in posterior teeth were compared. Out of the thirteen studies which were included seven studies had a high risk of bias and five studies had a moderate risk of bias. One study having a low risk of bias, concluded that there was no significant difference between direct and indirect technique. However, the available evidence revealed inconclusive results.

**Conclusion:** Further research should focus on randomized controlled trials with long term follow-up to give concrete evidence on the clinical performance of direct and indirect composite restorations.

**Keywords:** Clinical evaluation; indirect technique; posterior teeth; single-visit direct composite restorations, survival rate

Anexo 23: Azeem RA, Sureshabu NM. Clinical performance of direct versus indirect composite restorations in posterior teeth: A systematic review. J Conserv Dent [Internet]. 2018 [citado 16 marzo de 2021]; 21(1):2-9. Disponible en: [https://doi.org/10.4103/JCD.JCD\\_213\\_16](https://doi.org/10.4103/JCD.JCD_213_16).

## Endocrowns: A systematic review



Nicolas Govare, DDS<sup>a</sup> and Mathieu Contrepois, DDS<sup>b</sup>

The restoration of extensively damaged endodontically treated teeth remains a challenge. Their biomechanical deterioration impacts the tooth's long-term prognosis.<sup>1,2</sup> The most commonly used restoration for these teeth still involves a post-retained foundation restoration and a crown.<sup>2-5</sup> The only advantage of inserting a post is to increase the retention of the core foundation. Conversely, intracanal retention weakens the tooth structure and increases the risk of root fractures.<sup>6-10</sup> In the event of failure, in addition to exposing the tooth to irreversible fractures, the invasive nature of this type of restoration often excludes the possibility of further intervention.<sup>11</sup>

With progress in the development of adhesive techniques, the emergence of minimally invasive dentistry without a post or crown is challenging the post-and-crown concept.<sup>12</sup> First described in 1995 by Pissis,<sup>13</sup> the monoblock technique was the forerunner of the endocrown. The term endocrown was first used by Bindl and Mormann in 1999.<sup>14</sup> They described an adhesive monolithic ceramic restoration anchored in the pulp chamber, exploiting the micromechanical retention properties of the pulp-chamber walls (Fig. 1).

The purpose of this systematic review was to determine whether endocrowns are a reliable alternative to post-retained restorations for extensively damaged

### ABSTRACT

**Statement of problem.** The restoration of extensively damaged endodontically treated teeth remains a challenge. The use of post-retained restorations has been questioned because of potential tooth weakening.

**Purpose.** The purpose of this systematic review was to determine whether endocrowns are a reliable alternative to post-retained restorations for extensively damaged endodontically treated teeth and to determine which preparation design is most appropriate and which materials are best adapted for fabricating endocrowns.

**Material and methods.** The literature that was analyzed covered endocrowns from 1995 to June 2018. A search was conducted for in vitro and clinical studies in English in 3 research databases (PubMed, Cochrane, and Scopus), and this was complemented by a manual search in the bibliographies of the studies found. Case reports were excluded.

**Results.** A total of 41 publications consisting of 8 clinical studies and 33 in vitro studies were included in this systematic review. Several analysis parameters were identified: for the clinical studies, survival rate, failure modes, and clinical criteria; for the in vitro studies, fracture resistance, stress distribution, preparation criteria, and materials used.

**Conclusions.** Endocrowns are a reliable alternative to post-retained restorations for molars and seem promising for premolars. A certain preparation design and a rigorous adhesion protocol must be respected. Among the available materials, lithium disilicate glass-ceramic and nanofilled composite resin stand out. (J Prosthet Dent 2020;123:411-8)

endodontically treated teeth and to determine which materials are best for fabricating endocrowns and what preparation criteria should be used.

### MATERIAL AND METHODS

The review was established in accordance with the Preferred Reporting Items for Systematic Reviews and Meta-analyses (PRISMA) guidelines. An electronic search in PubMed, Scopus, and the Cochrane Library of articles published from January 1995 to June 2018 was conducted by using combinations of the following search terms: (endocrown OR endocrowns OR endo crown OR endo-crown) AND (computer aided design OR post and

Anexo 24: Govare N, Contrepois M. Endocrowns: A systematic review. J Prosthet Dent [Internet]. 2020 [citado 16 marzo de 2021]; 123(3): 411-418.e9. Disponible en: <https://doi.org/10.1016/j.prosdent.2019.04.009>.

## Review

### Porcelain veneers: a review of the literature

M. Peumans\*, B. Van Meerbeek, P. Lambrechts, G. Vanherle

*Department of Operative Dentistry and Dental Materials, School of Dentistry, Oral Pathology and Maxillo-Facial Surgery, Catholic University of Leuven, Kapucijnenvoer 7, B-3000 Leuven, Belgium*

Received 15 April 1999; received in revised form 25 June 1999; accepted 10 September 1999

---

#### Abstract

**Objectives:** Porcelain veneers are steadily increasing in popularity among today's dental practitioners for conservative restoration of unaesthetic anterior teeth. As with any new procedure, *in vitro* and *in vivo* investigations are required to assess the ultimate clinical efficacy of these restorations. The current literature was therefore reviewed in search for the most important parameters determining the long-term success of porcelain veneers.

**Data sources:** Laboratory studies focusing on parameters in prediction of the clinical efficacy of porcelain veneers such as the tooth preparation for porcelain veneers, the selection and type of the adhesive system, the quality of marginal adaptation, the resistance against microleakage, the periodontal response, and the aesthetic characteristics of the restorations have been reviewed. The clinical relevance of these parameters was then determined by reviewing the results of short and medium to long-term *in vivo* studies involving porcelain veneers performed during the last 10 years.

**Conclusions:** The adhesive porcelain veneer complex has been proven to be a very strong complex *in vitro* and *in vivo*. An optimal bonded restoration was achieved especially if the preparation was located completely in enamel, if correct adhesive treatment procedures were carried out and if a suitable luting composite was selected. The maintenance of aesthetics of porcelain veneers in the medium to long term was excellent, patient satisfaction was high and porcelain veneers had no adverse effects on gingival health in patients with an optimal oral hygiene. Major shortcomings of the porcelain veneer system were described as a relatively large marginal discrepancy, and an insufficient wear resistance of the luting composite. Although these shortcomings had no direct impact on the clinical success of porcelain veneers in the medium term, their influence on the overall clinical performance in the long term is still unknown and therefore needs further study. © 2000 Elsevier Science Ltd. All rights reserved.

**Keywords:** Porcelain veneers; Adhesion; Clinical effectiveness; Laboratory performance; Literature review

---

Anexo 25: Peumans M, Van Meerbeek B, Lambrechts P, Vanherle G. Porcelain veneers: a review of the literature. *J Dentistry*. 2000; 28(3):163-177.

#### Abstract

**Purpose:** To determine the fracture resistance of teeth, following treatment with various types of adhesive restorations.

**Materials and methods:** 50 caries-free, extracted human molars were randomly divided into five groups consisting of 10 molars each. MOD cavities were prepared in 40 molars with a width in the facio-lingual direction of 50% of the intercuspal distances. The cavities were filled with the following materials: Cerec or IPS Empress ceramic inlays, Arabesk or Charisma F resin-based composite (RBC) restorations. The control group consisted of 10 sound, non-restored molars. All 50 teeth were loaded occlusally until fracture using a tensile testing machine. The statistical analysis included ANOVA, Kolmogorov-Smirnov-test, Scheffé test, and boxplots.

**Results:** There was no significant difference ( $P > 0.05$ ) between the mean values of the sound teeth (2,102 N) and the teeth with the Cerec ceramic inlays (2,139 N). However, both groups demonstrated a significant difference ( $P < 0.05$ ) when compared with the teeth with IPS Empress ceramic inlays (1,459 N) and Arabesk RBC restorations (1459 N). No significant differences were found between the last two groups. Molars restored with Charisma F composite restorations (1,562 N) revealed no significant difference when compared with all other groups including controls ( $P > 0.05$ ). A stabilization of molars is possible by means of an adhesive restoration in the form of an "internal splinting" regardless of the restorative material used.

Anexo 26: Bremer BD, Geurtsen W. Molar fracture resistance after adhesive restoration with ceramic inlays or resin-based composites. *Am J Dent [Internet]*. 2001 [citado 5 abril de 2021]; 14(4):216-20. PMID: 11699740

