

TRABAJO DE FIN DE GRADO

Grado en Odontología

**STUDY OF AVAILABLE TECHNIQUES FOR
BONE ATROPHY IN THE ANTERIOR
SECTOR**

Madrid, curso 2020/2021

Número identificativo

155

Resumen estructurado

La regeneración de los defectos óseos intraorales siempre ha sido un reto para los dentistas quirúrgicos y los cirujanos maxilofaciales. Hemos visto cómo los defectos óseos del sector anterior, ya sean horizontales, verticales o combinados, pueden generar alteraciones funcionales y estéticas, muy graves, en nuestros pacientes.

Asimismo, el objetivo de nuestro estudio fue identificar las técnicas quirúrgicas y, los biomateriales más adecuados que pueden utilizarse en la regeneración de tejidos dentro del sector estético del maxilar y la mandíbula.

Por ello, a través de nuestra investigación bibliográfica se ha centrado en un análisis exhaustivo de las bases de datos de los últimos 10 años. El examen se realizó mediante motores de búsqueda como Medline Complite y Wiley Library.

Se examinaron un total de 57 artículos y, los resultados obtenidos mostraron que, independientemente del tipo de cirugía utilizada y del biomaterial empleado por el cirujano, hasta la fecha la regeneración de estos defectos óseos ofrecieron unos resultados muy satisfactorios además de un bajo riesgo de complicaciones.

Se ha visto como amenudo los cirujanos que se disponen a tratar defectos óseos de alta complejidad por extensión o por localización múltiple, se ven obligados a utilizar enfoques multimodales para resolver mejor las necesidades estéticas y funcionales del paciente.

En cuanto a los materiales que se pueden utilizar, se ha visto que el autoinjerto de hueso de origen oral asociado al uso de membranas de colágeno sigue siendo la mejor opción. En caso de defectos volumétricamente mayores, o de escasez de tejido óseo intraangular, hemos visto

como los cirujanos pueden recurrir a la extracción de hueso extraoral y a tejido óseo de origen no autólogo, como el xenoinjerto.

Palabras clave: atrofia ósea de la mandíbula anterior, atrofia ósea del maxilar anterior, injerto óseo, atrofia del maxilar, maxilar anterior, atrofia de la mandíbula, mandíbula anterior.

Abstract

The regeneration of intraoral bone defects has always been a challenge for surgical dentists and maxillofacial surgeons. We have seen how bone defects in the anterior sector, be they horizontal, vertical or combined, can generate even serious functional and aesthetic alterations in our patients.

The aim of our study was therefore to identify the most suitable surgical techniques and biomaterials that can be used in tissue regeneration in the aesthetic sector of the anterior maxilla and mandible.

Therefore, our bibliographic research focused on an in-depth analysis of the databases of the last 10 years. The search was carried out using search engines such as Medline Complite and Wiley Library.

A total of 57 articles were examined, and the results showed that, regardless of the type of surgery used and the biomaterial used by the surgeon, regeneration of these bone defects today offers highly satisfactory results with a low risk of complications.

It has been shown that surgeons often have to use multimodal approaches to treat highly complex bone defects in terms of extent or multiple locations in order to better meet the aesthetic and functional requirements of the patient.

With regard to the materials that can be used, it has been shown that the autograft of bone of oral origin associated with the use of collagen membranes is still the primary choice. In the case of larger volumetric defects, or shortage of intra-angular bone tissue, we have seen how surgeons can resort to extra-oral bone harvesting and bone tissue of non-autologous origin, such as xenograft.

Key words: anterior mandible bone atrophy, anterior maxilla bone atrophy, bone graft, maxilla atrophy, anterior maxilla, mandible atrophy, anterior mandible.

Índice

1. Introduction:	1
1.1 Bone cytology and histology	2
1.2 Surgical anatomy	5
1.3 Bone atrophy and alveolar ridge defect classifications	11
1.4 Bone graft and surgical procedures.....	16
2. Objective:.....	20
3. Materials and methods	21
4. Results	26
4.1 Medline Complete Mandible	26
4.2 Medline Complete Maxilla	28
4.3 Wiley Library Mandible	43
4.4 Wiley Librsy Maxilla.....	56
5. Discussions	62
Conclusions	68
Responsibility	71
References.....	72
Anexo	87

1. Introduction:

The modern dentist who deals with single or multiple missing teeth or damaged dentition finds several possible restorative and prosthetic strategies available today (1-6).

Dental implantology has indeed implemented the possible therapeutic choices from an aesthetic and, above all functional point of view, making it possible to improve the patient's quality of life (2-4).

Over the past decades, studies carried out by various researchers have amply demonstrated that three factors are necessary to ensure implant success and long term survival of the same dental implant (2,4).

According to this reason, dentists have begun to talk about "implant triangles" (4).

The three factors taken into consideration are: first, the correct placement of the implants guided by the restoration, second, the appearance of an adequate amount of bone reserve, as a basis for osseointegration, and third, eventually the presence of a salubrious soft tissue at peri-implant level, for precise implant sanitation and preservation (4).

Therefore, it is clear that biology and bone preservation play a vital role in the dental branch of implant surgery (1-6).

For this reason, we will now describe histology and bone anatomy before addressing bone atrophy, its causes, classification and possible surgical approaches.

1.1 Bone cytology and histology

Bone is a supporting connective tissue, highly specialised and defined by its own hardness and rigidity (7).

Bone is a highly mineralised connective tissue with a mineral matrix of 67% and a protein matrix of 33. 28% of these proteins are type I collagen while the remaining 5% of the matrix is made of noncollagenous proteins (9).

The inorganic matrix is essentially composed of calcium phosphate $[Ca_3(PO_4)_2]$, and this compound, in combination with other mineral salts such as calcium hydroxide $[Ca(OH)_2]$, gives rise to hydroxyapatite crystals $[Ca_{10}(PO_4)_6(OH)_2]$ (8,9).

The protein matrix, on the one hand, and the mineral matrix on the other contribute to the already mentioned hardness and rigidity properties (7).

The osteoid matrix is a collagen tissue made of type I collagen fibres, immersed in a gel of glycosaminoglycan and specific glycoproteins such as Osteocalcin, with the function of linking calcium. The deposit of mineral salts in the protein matrix gives the bone its typical functional characteristics. Osteoblasts synthesise the osteoid protein (7).

Four are the cell lines present within the bone tissue: “osteoprogenitor cells, osteoblasts, osteocytes, and osteoclasts” (8).

Osteoprogenitor cells are non-specialised stem cells originating from the mesenchyme. These are the isolated bone cells suffering cell division; the cells resulting from this process are the osteoblasts. Osteoprogenitor cells are present over the periosteum and endosteum, and in the vascular channels within the bone (7,8).

Osteoblasts are the cells that create the bone. They assemble and secrete the collagen type I fibres and additional organic compounds necessary to raise the extracellular matrix and induct

calcification. When osteoblasts enclose themselves within the extracellular matrix, they get caught in their secretions and convert in osteocytes (7,8).

Osteocytes, the mature and inactive form of bone cells, are the most abundant cells in the bone and guarantee tissue metabolism through the constant exchange of nutrients and metabolic waste with the bloodstream. As a common element with osteoblasts, osteocytes do not carry out any cell division process (7,8).

Osteoclasts are large multi-nucleated cells rich in the cytoplasm, derived from precursors of the myeloid/monocyte line. These cells are stored in the endosteum. Osteoclasts can release some acids and enzymes (lysosomal), capable to digest proteins and mineral parts of the extracellular bone matrix. This process is identified as bone resorption and is part of natural bone development, preservation and repair (7,8).

The common feature of all bones at histological level is the presence of a cortical, external layer of dense bone tissue, the compact bone. This outer layer encloses and protects an internal cavity. The cavity is filled with bone matrix (mostly found in long bones) and a network of bone trabeculae, known as spongy, trabecular or cancellous bone (8,9).

Both the outer and inner layers of bone tissue, both spongy and compact, are covered with a connective tissue membrane. On the outside of the bone cortical, we find a double layer of connective tissue known as the periosteum, which is active during bone formation and remodelling. Its outermost layer, the fibrous layer, is essentially made up of dense and irregular connective tissue, while the highly vascularized inner layer is rich in bone cells and bone line precursors (8,9).

The inner layer of bone tissue that looks at the bone marrow is also covered by a thin double layer of connective tissue known as endosteum. The tissue is rich in osteogenic cells and loose connective tissue (8,9).

The elementary unit, characteristic of compact bone is osteon or Haversian system. In each osteon, we recognise an internal channel, the so-called central, osteonic or Haversian channel, surrounded by a series of concentric lamellae of mineralised bone matrix. The appearance of these lamellae is reminiscent of tree trunk growth circles (8,9).

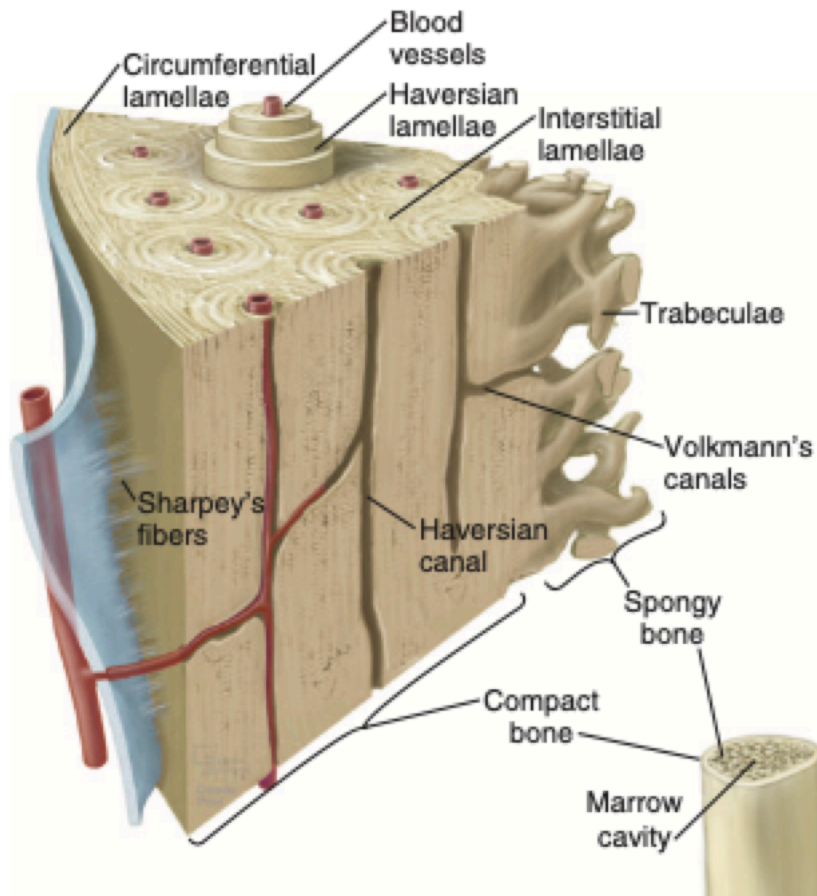


Image1: Bone osteon or Haversian system (9), page 94.

Blood vessels and nerves, run inside the aforementioned Haversian channels (8,9).

Various osteons are oriented parallel to each other and the major axis of the bone, and leave room for small areas called lacunae, where the osteocytes are located. Small canals branch out in every direction from the gaps, and the digitiform projections of the osteocytes occupy these internal lumen (8,9).

Also between an osteon and the nearest one are interstitial lamellae with their osteocytes and canaliculi. At the same time, the most extensive and internal layer consists of external and internal circumferential lamellae (8,9).

The outer circumferential lamellae are anchored to the periosteum by the perforating fibers of Sharpey (8,9).

The blood vessels and nerves coming from the periosteum penetrate the external circumferential lamellae at the level of special holes, the Volkmann's or perforating interosteonic canals giving rise to a network with those present inside the osteons and in the medullary cavity (8,9).

A layer of compact bone covers and protects the spongy bone tissue. Unlike compact bone, we can not find osteons here, and the bone tissue is organised in trabeculae, relatively thin bone columns consisting of lamellae arranged in an apparently irregular pattern. We can observe large empty space, visible without the help of any magnification instruments, between the trabeculae. These spaces are occupied with red bone marrow (only in the femur for the adults human been) only for those bones involved in hemopoiesis, and yellow bone marrow (normal adipose tissue) in all other bones (8,9).

The profuse surgical techniques available today, and the significant development of bioengineering, make necessary to have an in-depth knowledge of the bone structures on which we are going to operate (3).

It is therefore crucial for a correct analysis of the surgical techniques available to treat atrophy of the anterior bone sector to describe the surgical anatomy of the maxilla and mandible briefly.

1.2 Surgical anatomy

The upper jaw or maxillae is composed of two maxillas fused, along the midline, by means of the intermaxillary suture (10).

"Each maxilla articulates with the frontal bone, lacrimal bone, nasal bone, inferior nasal concha, vomer, sphenoid bone, ethmoid bone, palatine bone, and zygomatic bone" and "includes a body and four processes: the frontal, zygomatic, palatine, and alveolar processes" (10).

The body of the jaw is pyramid-shaped four surfaces "the orbital, nasal, infratemporal, and facial surfaces" (10). The zygomatic bone defines the apex of this pyramid (3,10).

The intra-oral limit of the jaw, covered by oral mucosa, is mucobuccal fold, or fornix (3,10).

The body of the maxilla, on the other hand, is only covered by subcutaneous tissue and skin (3,10).

The insertion of the masseter muscle, located in the molar portion of the maxilla, forms a barrier between the buccal vestibule and the subcutaneous tissue found in the buccal surgical space (3,10).

In the anterior region of the jaw, from canine to contralateral canine, no muscle insertion acts as a fornix barrier (3,10).

The alveolar process of the jaw can be divided into an anterior-lateral and posterior-lateral portion. The former serves as the bone base for "the incisors, canines, and premolars", while the latter, "the molars and ends as the maxillary tuberosity" (3).

Along the midline the front projection of the anterior nasal spine supporting the nasal septum cartilage (3,10).

Intraorally so can palpate two bone projections that can be used as important landmark. Posterio-laterally the maxillary process of the zygoma bone, and anteriorly the canine eminence (medial) and fossa la canine (lateral) (3).

Dorsally at the canine fossa, the anterior surface of the maxillary sinus can be palpated, and the infraorbital foramen can be located (3,10).

Posteriorly to the zygomatic process is the latero-posterior surface of the maxilla, divided by the fornix in its intraoral (inferior) and infratemporal (dorsal) part (3).

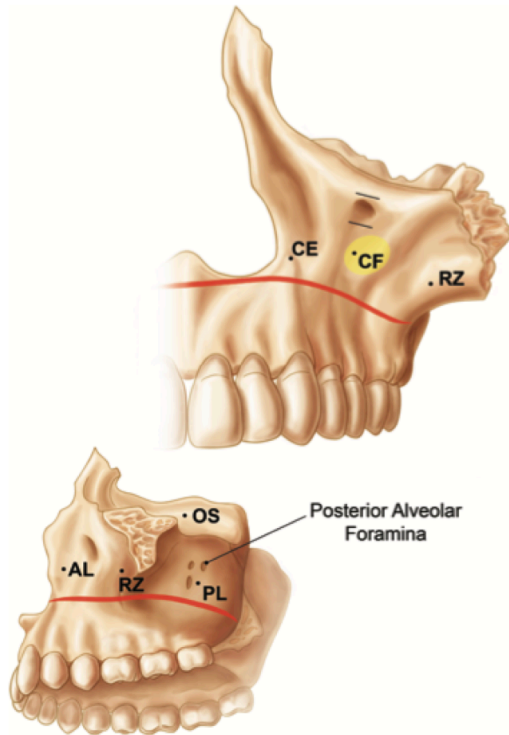


Image2: Maxilla anatomy (3), page 9.

The mandible, or lower jaw, is an uneven horseshoe-shaped skull bone. The mandible is the only mobile joint in the skull and is articulated with the temporal bones on both sides and generates the temporomandibular joint (3,10).

During an extraoral and intraoral inspection, the dentist can palpate various points of discovery. Directly through the skin, the surgeon can palpate "the mental eminence, inferior border premasseteric notch, gonial angle, lateral pole of the condyle, and coronoid process" (3).

While performing intraoral palpation of the external surface, the surgeon can locate "the external oblique ridge, coronoid process, and the boundaries of the retromolar triangle" (3).

Another element of fundamental importance for the localized nervous complex is the mental foramen that "can be palpated at the interpupillary line at the apices of the premolars" (3).

The jaw, or lower jaw, is an uneven horseshoe-shaped skull bone. The jaw is the only mobile joint in the skull and is articulated with the temporal bones on both sides and generates the temporomandibular joint.

During an extraoral and intraoral inspection, the dentist can palpate various points of discovery. Directly through the skin, the surgeon can palpate "the mental eminence, inferior border premasseteric notch, gonial angle, lateral pole of the condyle, and coronoid process" (3).

While performing intraoral palpation of the external surface, the surgeon can locate "the external oblique ridge, coronoid process, and the boundaries of the retromolar triangle" (3).

Another element of fundamental importance for the localized nervous complex is the mental foramen that "can be palpated at the interpupillary line at the apices of the premolars" (3).

Along the midline, at the anterior face of the mandible, it is easy to identify a slight relief, the mandibular symphysis, the result of the fusion of the two hemimandibles during the embryonic life (3,10).

Following the loss of any dental element, the causes of which we may discuss later, the dental alveolus and the surrounding bone gives rise to a so-called "alveolar ridge" (2-4)

Over time, this ridge reshapes and reabsorbs atrophic ridge that migrates apically towards the muscular insertions. For this reason, surgical incisions located at the bottom of the vestibule are purely intraoral in the healthy patient. These incisions can affect subcutaneous tissue in patients with atrophic bone, with possible iatrogenic damage to vital structures (vascular-black plexuses) and muscle insertions (3).

In severe cases of advanced mandibular atrophy, for example, the mylohyoid muscles push the sublingual glands dorsally, to the point where they exceed the edentulous crest in height; or the tendon insertion of the buccinators (posteriorly at the level of the molar region) may approach the residual crest until the muscle loses its bone insert in the underlying mandible. Also in cases of severe mandibular bone atrophies, in the anterior, an enlarged, disproportionally enlarged upper genial tubercle can be palpated along the lingual face at midline level (3).

For this reason, it is considered appropriate to briefly list the main muscle components and the nerve and vascular trophism of the jaw and mandible (3).

We must therefore remember the levator labii superioris muscle for its insertion immediately above the infraorbital foramen; the levator anguli oris (or caninus) muscle insert below the infraorbital foramen; the incisivus labii superior muscle, which takes its orientation from the incisor fossa above the lateral incisor. Eventually, we can find the buccinator muscle, whose insertion extends along the alveolar porch from the first to the third superior molar (3,10).

The main muscle insertions of surgical interest are those of the mylohyoid muscle bilaterally alveolus of the internal oblique ridge, then which represents the anatomical limit between the intraoral and under the mandibular area, forming the floor of the mouth (3,10).

We then find the genioglossus whose origin is inserted at the level of the superior genial tubercle.

As already mentioned above, we find the buccinator muscle which is inserted at the level of the external oblique ridge, at the height of three lower molars (3,10).

The medial and lateral pterygoid muscles, the temporal muscle and the masseter muscle, always inserted in the most caudal portion of the mandible (3,10).

And lastly, the mentalis muscle, mimic muscle inserted at the level of the mental tubercle and in the lateral portion of the mental eminence (3,10). The disinsertion of this muscle is

fundamental in the surgical phase in order to access the bone region of the mental symphysis, proceed to disconnect the periosteum from the mental eminence and proceed to the collection of bone tissue (3,4).

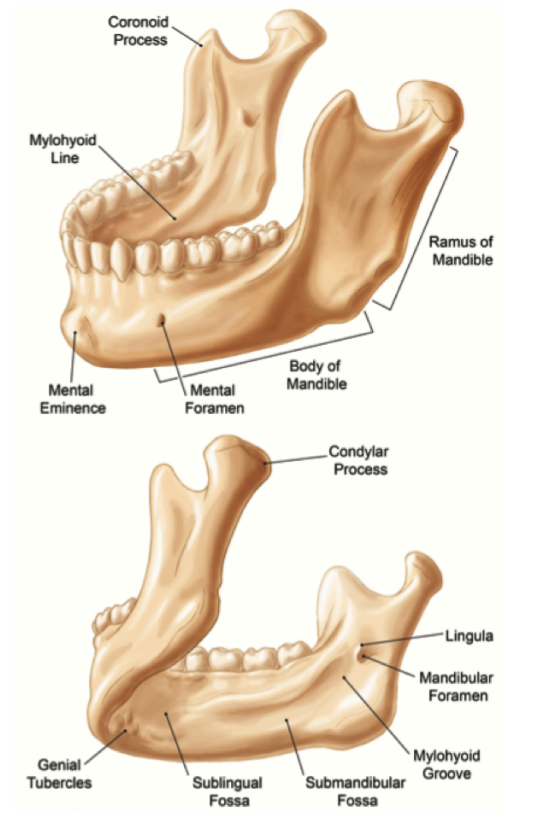


Image3: Mandible anatomy (3), page 13.

The innervation of the mandible is afferent to the maxillary nerve (V2) and the two branches. Leaving the cranial fossa middle in the nerve, it crosses the pterigopalatine fossa, thus defining the pterigopalatine portion. Its infratemporal portion crosses the fissure pterigopalatine and enters the infratemporal fossa. The nerve then crosses the orbit and the infraorbital fissure outwards through the foramen infraorbital. The portion inside the canal is called infraorbital portion, while the portion outside the canal is called facial portion (3,10).

The innervation of the mandible is afferent to the third division of the trigeminal nerve (V3). Its anterior division mainly originates motor branches that innervate the chewing muscles, while the posterior branch originates the two sensory branches and in a particular way from the lingual nerve and the inferior alveolar nerve (3,10).

The inferior alveolar nerve origin is found near the lower edge of the lateral pterygoid muscle and is directed towards the entrance of the mandibular foramen (3,10).

The inferior dental nerve then continues to pass through the entire mandibular canal to the level of the premolars, where it divides into the mental and incisive nerves. The latter continues its path inside the mandibular bone structure while, the mental nerve, exits through the foramen and is located along the outer surface of the mandibular cortex (3,10).

In cases of very marked atrophy of the anterior mandible, the vascular vasculature plexus exiting at the level of the mental foramen is localised at the level of the residual alveolar ridge, with the risk of possible iatrogenic damage (3). "The lingual nerve is one of the most commonly injured nerves in dental surgery" (3).

The lingual nerve, leaving the infratemporal fossa, runs between the lingual face of the jaw branch and the medial pterygoid muscle, the so-called pterygomandibular (3,10).

After entering the oral cavity, the nerve follows the medial cortical of the mandible body (3,10).

The maxillary artery and the maxillary vein, provide for the bloody inflow and drainage of the jaw, respectively (3,10).

1.3 Bone atrophy and alveolar ridge defect classifications

Tooth loss is often if not always associated with a significant change in the jawbone (2-4).

The most abundant and significant bone loss usually occurs during the first three months following a dental extraction, with a further possible volumetric loss of 11% over time (12).

In his books, Telstunov reports an average loss of 40-60% in height and thickness of the alveolar process in a time interval of 2-3 years after extraction (3,4).

For this reason, and following the concept of "implant triangles" (4) already mentioned above, many patients requiring a prosthetic resolution and, or an edentulous implant may be valid candidates for bone regeneration techniques (2-4).

However, not all bone defects are identical, and there are various classifications of maxillary or mandibular bone atrophy and bone quality that surgeons are preparing to diagnose, treat and resolve (3,4).

Several classifications are now available in the literature, some of the most used and of most significant impact are, the one introduced in 1985 by Lekholm and Zarb, and the one proposed by Siebert (3, 4, 11-16).

According to what reported in various books, (3,4,11,12) Lekholm and Zarb define bone atrophy according to the shape of the residual cross-section of the alveolar ridge; we find as grade "A" a bone in which most of the alveolus is still preserved and with grade "E" an atrophic bone section with almost complete disappearance of the basal bone. For what concerns the quality of bone that always observes in the cross-section, the authors describe with "1" a mainly compact bone, with "2" a thick cortical bone surrounding a dense host bone, with "3" a thin compact bone, surrounding a dense spongy bone, and finally, with grade "4" a thin compact bone, surrounding a spiny bone of low density (3,4,11,12).

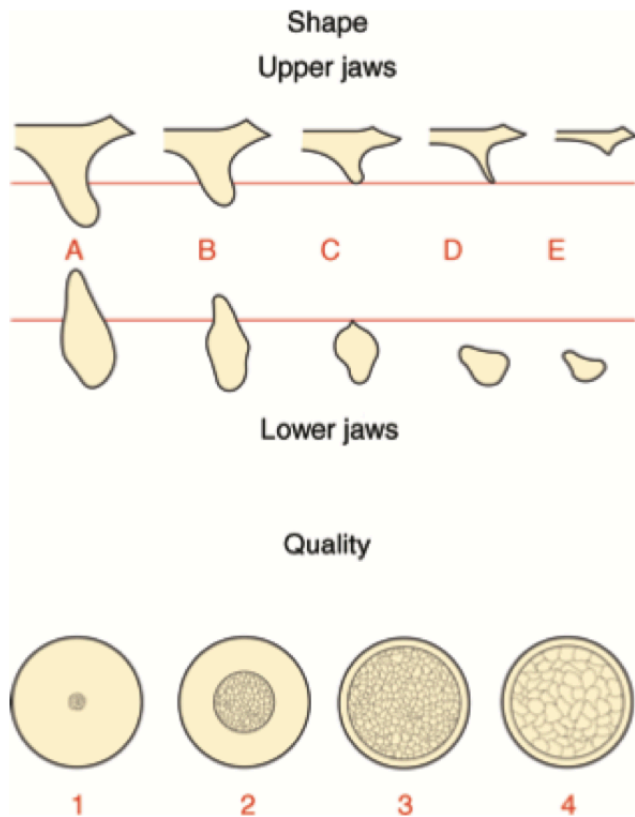


Image4: Lekholm and Zarb classification of bone atrophy (3), page 73.

A second classification also reported in some books (3,4), is that of Siebert where the defects of edentulous ridge shape are classified according to the direction of the most abundant bone loss. We find therefore bone defects in the bucco-lingual thickness with height preserved in "class I". Bone defects in apico-coronal directions with preserved thickness, in "class II". Furthermore, finally, combined defects in height and thickness of the residual alveolar ridge in "class 3" (3,4).

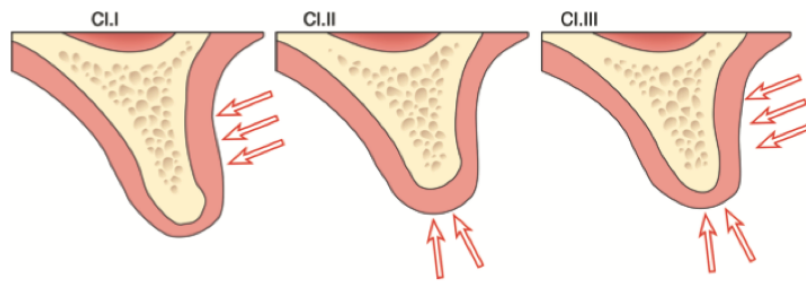


Image5: Siebert classification of bone atrophy (3), page 73.

Another classification of the anterior sector of the jaw and mandible, and which best combines defects of the bone tissue, with those of the gingival soft tissue, is Palacci-Ericsson's classification (3,4).

In order to better understand this classification, should be recalled the presence of the two main gingival profile biotypes known as, "thick gingival biotype" and "thin gingival biotype" (3,4,16).

The macroscopic micro and macroscopic architecture of the gingival tissue is conditioned by genetic bases and various local factors, such as the anatomy of the dental elements, and the quality of the points of contact (3,4,16); and the type of gingival biotype often reflects a similar development of the underlying bone tissue, more or less thick, flat or thin (16).

Palacci-Ericsson's classification divides vertical tissue defects into four classes (from I to IV) and vertical defects into four classes (from A to D) (3,4). Class I patients have almost intact or only slightly reduced papillae; Class II patients have a limited vertical papillae loss; Class III patients have severe papillary tissue loss; and, finally, Class IV patients have a complete absence of interdental papillae.

According to horizontal tissue defects, Class A patients present a slight loss of tissue; Class B subjects have limited buccal tissue loss; Class C subjects have a severe degree of tissue loss;

and finally, Class D subjects have very severe horizontal defects often associated with almost complete loss of attached mucosa (3,4).

As we have already seen in other classifications previously reported, horizontal and vertical tissue defects often combine, and in order to categorize the defects of the anterior sector of each patient, it is sometimes necessary to associate the two classes (I-IV and A-D) (3,4).

These classifications can be useful both in the diagnostic phase and in the treatment planning phase (3,4, 11-16).

1.4 Bone graft and surgical procedures

Various reconstructive surgical approaches can be used to treat the previously described and classified intr-oral bone defects. Reconstructive surgery involves the use of "grafts", materials of a different nature for re-integrating lost tissue (1-6, 12,13).

"A tissue that is transplanted and expected to become a part of the host to which it is transplanted is known as a graft" (12).

Another element of fundamental importance at the basis of tissue regeneration techniques is the particular biology of bone healing which partially differentiates it from other connective tissues. During the healing process, bone tissue obtains a complete "restitutio ad integrum" without the formation of scar tissue. As a result of the bone repair and remodelling phases, the new-formed bone tissue will be undesired by the surrounding basal bone tissue (7-9, 12, 13).

In order to better understand the mechanism of action of the grafts that can be used in dentistry, we must necessarily clarify three basic concepts: osteogenesis osteoinduction and osteoconduction.

Following the paradigm of osteogenesis, the surviving osteoprogenitor cells within the graft mature and thus give rise to new ossification centres (3).

In the osteoconduction model, on the other hand, the graft behaves exclusively as a "scaffold", providing physical support to the patient's progenitor cells and vascular elements, to migrate within this support and then generate new bone tissue (3).

The last concept is that of osteoinduction, according to which this graft attracts pluripotent cells nearby, and these cells then give rise to the osteoblastic or chondroblastic cell line (3).

Today the bone graft considered "gold standard" in the treatment of defective bone remains the autologous bone tissue, i.e. belonging to the same individual. This material has all the

characteristics we would like to look for in every graft: osteogenesis, osteoconduction, osteoinduction (3,4, 13, 17).

Various autologous tissue collection sites are reported in the literature; among these, there are possible extra-oral and other intraoral collection points.

Intraoral bone tissue can be collected at the level of the jaw branch, at the level of the Mentonaian symphysis, at the level of the maxillary tuberosity, and lingual or palata tori for example (3).

The main extraoral collection sites remain the calvarium, anterior iliac crest, posterior iliac crest, tibia (3,4,13,17).

Each collection site and each surgical technique has a number of advantages and, at the same time, a number of disadvantages.

Extraoral sampling sites, often associated with moderate morbidity at the sampling site, make it possible to treat complex in clinical cases (severe cases of bone atrophy and the need for high graft vouches). On the other hand, intra-oral sampling sites allow only limited graft propositions to be collected, but allow surgical approaches of minor extensions and at sites identical or very close to the future graft implantation site (3,4 13,17).

Among the various surgical techniques available in the literature to date, the "guided bone regeneration" is certainly worthy of note. This technique is mainly used to treat finite bone defects and involves the use of a particulate bone graft in association with a membrane above it. The membrane sustains the graft, protects it from dispersion in the surrounding tissues and prevents non-bone tissues (connective or epithelial) from migrating inside the graft and interfering with the successful outcome of the surgery (4, 18,19).

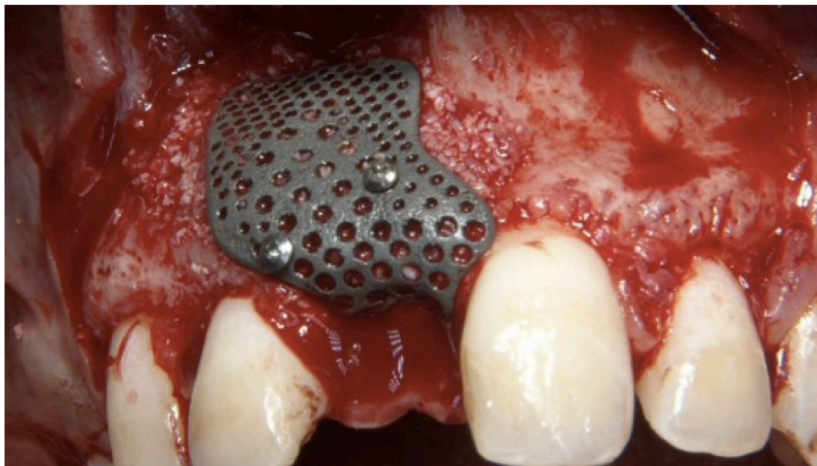


Image6: GBR in titanium mesh for anterior sector (32), pag 4

The surgeon can use resorbable and non-resorbable membranes, as well as titanium mesh. (4,18,19)

Other procedures described in the literature are called osteoperiosteal flap ridge-split procedures. This technique is used in residual ridge with mainly horizontal bone defects I, which are too thin for proper implant placement (4). This technique can be used at practically any level of the jaws. However, it is very suitable for anterior aesthetic areas and atrophic tracts of the posterior jaw with a surgical success rate of 98-100% (4). In case of very thin ridging, unfortunately, this technique alone is not sufficient to provide sufficient enlargement of the treated area (3.4).

A technique involving the simultaneous regeneration of intraoral soft tissue and bone tissue is distraction osteogenesis (4.20).

This technique foresees the realization of an osteotomy, the application of a distraction device, and a distraction protocol of the bone segment.

This surgical technique includes five variants depending on the vascularization or induction of the vascularization to be recreated (4).

We then find surgical block grafting techniques; depending on the level of the positioning of these blocks of bone tissue, the surgical techniques can be classified into veneer, inlay, onlay and, finally, saddle graft. The graft always foresees the presence of a portion of cortical bone tissue at the level of which the anchorage screw must be inserted (4,13).

Finally, other regenerative techniques involve the use of substances with purely osteoinductive properties together with morphogenic bone proteins of recombinant origin, RhBMP-2 (3,4).

2. Objective:

1. To identify the best bone grafting and surgical treatment for the treatment of anterior maxilla bone atrophy.
2. To identify the best bone grafting and surgical treatment for the treatment of anterior mandible bone atrophy.

3. **Materials and methods:**

It is decided to use the research source "Medline Complete" as a digital database.

The search term "anterior mandible bone atrophy" is used to search for 77 articles, so it is decided to set the limitation to only articles present as full text.

The limbs thus selected, and without the restriction of the year of publication would be 39.

Using the limitation date of publication last ten years (2010-2020) and without language restrictions, we still collect 20 articles.

By setting "English" as the primary language, the articles are reduced to 19.

It is decided to use the research source "Medline Complete" as a digital database.

The search term "anterior maxilla bone atrophy" is used to search for 118 articles, so it is decided to set the limitation to only articles present as full text.

The limbs thus selected, and without the restriction of the year of publication would be 63.

Using the limitation date of publication last ten years (2010-2020) and without language restrictions, we collect 46 articles.

By setting "English" as the primary language, the number of total articles does not change.

It is decided to use the research source "Wiley library" as a digital database.

The search terms "anterior mandible", "bone graft" and "mandible atrophy" are used and 2122 items are collected.

Using the limitation of journals only 1728 articles are selected

Using the limitation date of publication last ten years (2010-2020) we collect 770 articles

Narrowing the search to the dental branch alone, 377 items remain.

It is decided to use the research source "Wiley library" as a digital database.

The search terms "anterior maxilla", "bone graft" and "maxilla atrophy" are used and 2265 items are collected.

Using the limitation of journals only 1889 articles are selected

Using the limitation date of publication last ten years (2010-2020) we collect 794 articles

Narrowing the search to the dental branch alone, 477 items remain.

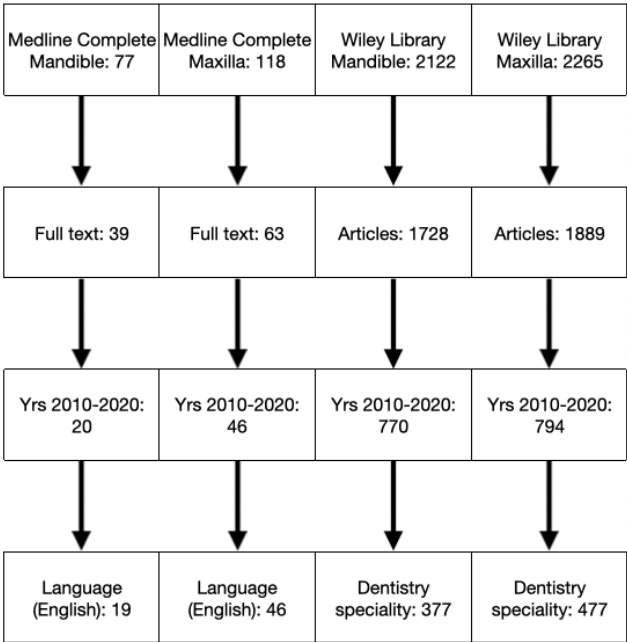


Image7: Flow chart of bibliographic research

We selected and organized, these exclusion criteria them a table::

1. Bone graft in general appearance
2. Correct bone segment but wrong sector (mandible or posterior jaw, paranasal sinuses)
3. Corrected bone segment and anterior sector but not related to bone atrophy (soft tissue alterations or fractures)
4. Anatomical studies
5. Implantology (post-mining, zygomatic implants, overdenture, all on 4/6, complications of implantology)
6. Other diseases affecting the bone segment (skull dysplasia, tomorias, degenerative diseases)
7. Posters, abstracts or short conference communications, or articles with insufficient bibliographical sources
8. Clinical studies on animals
9. Surgeries that do not have bone regeneration expertise.

	Medline Complete Mandible	Medline Complete Maxilla	Wiley Library Mandible	Wiley Library Maxilla
1	2	2	69	71
2	1	2	58	82
3	1	0	10	26
4	3	2	13	18
5	3	13	59	137
6	0	3	26	36
7	1	1	79	75
8	0	0	13	9
9	1	0	10	3
Remaining	7	23	31	20
Ripetitions	2	0	12	10
Final	5	23	19	10

Table1: Exclusion criteria

The articles so selected following the application of the inclusion criteria and eliminating any repetitions are:

- Medline Complete Mandible: 5
- Medline Complete Maxilla: 23
- Wiley Library Mandible: 19
- Wiley Library Maxilla: 10

Exclusion criteria	19	46	377	477
1	↓	↓	↓	↓
	17	44	308	406
2	↓	↓	↓	↓
	16	42	250	324
3	↓	↓	↓	↓
	15	42	231	298
4	↓	↓	↓	↓
	12	40	218	280
5	↓	↓	↓	↓
	9	27	159	143
6	↓	↓	↓	↓
	9	24	133	107
7	↓	↓	↓	↓
	8	23	54	32
8	↓	↓	↓	↓
	8	23	41	23
9	↓	↓	↓	↓
Remaining	7	23	31	20
Ripetitions	2	0	12	10
Final	5	23	19	10

Image8:. Flow chart of exclusion criteria

4. Results

4.1 Medline Complete Mandible

Ghassemi et al. analyzed retrospectively 54 patients undergoing reconstruction of mandibular bone deficits. The causes of these atrophies are malignant, benign, infectious and alveolar atrophy (only 1 case).

Practitioners claim that iliac bone grafting is an excellent alternative for bone regeneration because of its size and shape. The authors then focus on systems to assess pain and function at the harvesting site and the Harris Hip Score, in their opinion, is a reasonable means of determining this parameter (21).

In an observational study, Cohen et al., report four clinical cases of patients with edentulism and vertical bone atrophy of the anterior mandible treated with a bone graft in the onlay technique.

The bone graft is harvested from the region of the mandibular symphysis.

They present a surgical grafting technique without any additional means of stability (screws, plates or nails) and the bone gap is reduced.

The authors agree that the technique is a valid alternative and a predictable procedure for the subsequent application of osseointegrated implants.

Radiographic follow-up at the time of implant surgery found no bone deficits or signs of reabsorption, and the aesthetic, clinical and joint prosthetic results were all achieved (22).

Jeevan Kuma et al. present a study of 10 patients who underwent osteogenic alveolar distraction surgery to regenerate mandibular bone tissue of the anterior sector in the absence of bone grafting. The real increase of vertical bone size (in both apical coronal and lingual buccal dimensions) is evaluated using radiographic and CT scan.

The authors state that bone distraction to date is considered a highly predictable method for the restoration of alveolar bone deficiencies in the pre-prosthetic phase. This surgical technique allows for adequate soft tissue "development"/"preservation" in parallel with bone growth.

The authors conclude that the recovery of the vertical dimension can exceed 10mm. The morbidity reported by the patients is reduced, the regenerated bone is long-lasting and of comparable quality to the native bone, and the risks of post-surgical infections are limited (23).

Ergun et al. present a case report of 3 patients treated with bone distraction for severe alveolar bone atrophy in the mandible. Two of the patients had atrophy in the posterior sector and only one in the anterior sector. This 70-year-old female patient had a 6.3 mm recurrence at the end of the treatment and was prosthetised with two 4.1 mm diameter and 10 mm long implants.

The arthroplasty, therefore, reports the formation of ideal bone volume for the execution of implant-prosthetic procedures.

Nevertheless, the authors report some limitations of the surgical technique, such as the loss of regenerated bone tissue, the displacement of the transported bone secretion, and possible soft tissue complications. The authors point out that the anatomical region of the mandible is subject to the traction of the muscular tissues present at the floor of the mouth, which may affect the surgical outcome, and believe that further clinical studies are needed (24).

Parthiban et al. present a case report of a patient with a horizontal bone defect of the anterior mandibular sector. The bone deficit is treated with a ridge split technique, immediate endosseous implant application and application of platelet-rich fibrin (PRF) membrane. By following this technique, the authors predict a reduction in patient morbidity, avoiding re-intervention after a period (necessary for bone healing) when the implants are applied.

According to the authors, the advantage of this single-set approach is that it shortens the overall duration of dental prosthetic treatment. The authors point out that the surgical procedure is "technically sensitive" and is not without complications. The clinical case, however, presents a satisfactory and complication-free follow-up at six months (25).

4.2 Medline Complete Maxilla

French and Tallarico present a clinical case of a patient with implant-retained overdenture in the maxilla and mandible. The overdenture is supported by implants applied in the regenerated bone. The clinical case shows severe atrophy of both jaws, treated with regenerative techniques in the upper sector only.

The implants applied in the maxilla present 3-5 m of exposure and are treated with autogenous bone and non-resorbable membrane fixed with pins applied in the same session of implant surgery. The mandible shows "knife blade" bone atrophy and the bone tissue osteotomized before applying the implants are used as a graft in the maxilla.

Four months after the first closure, the non-resorbable membrane is removed, and the surgeons are satisfied with the graft's success.

The authors state that the follow up at eight years is very positive and in agreement with similar articles and clinical cases; the correct hygiene management and evaluation of the overdenture are clinical factors not to be neglected (26).

Dasmah et al. present a prospective study of 15 clinical cases with a 5-year follow-up in which they compare the peri-implant marginal bone level changes. Implants are placed in block and particulate bone grafts in Onlay from the iliac bone and platelet-rich plasma (PRP) in anterior maxilla with bone atrophy. The authors' conclusions at five years showed no statistically significant differences between the two techniques. However, the authors reported greater marginal resorption in the first year of post-implantation loading than at five years (27).

Osterne et al. present a technique of bone regeneration by distraction in the aesthetic area of the jaw. The surgery foresees the realization of an osteotomy and the bone segment's distraction in a single step. The authors agree and satisfied with the outcome of this proposed surgical technique.

Rehabilitation treatment involves two surgical steps. During the first one, the implant is placed, and during the second one, the regeneration operation is performed. The authors agree that this second phase, and the consequent delay in the patient's final management, is a disadvantage of the proposed surgical technique.

Post osteotomy the bone segment is distracted in an apical direction according to the mobility of the surrounding soft tissues (principal and palate). If the tissue doesn't allow this movement, a bone distraction instrument is applied to the patient. The average bone augmentation reported was 4.9 mm on 25 implants, with a maximum of 8.4 mm; similar results to the users' opinion with the bone distraction techniques.

This surgical technique allows the successful reconstruction of vertical bone defects in maxillary anterior setae, guarantees good soft tissue quality, and the morbidity for the patient is, according to the authors, mild.

The authors agree on the need for further clinical studies (28).

Cordaro et al. performed a retrospective collection of 15 clinical cases of patients with moderate maxillary atrophy. The patients were treated with sinus graft for the posterior tract and Onlay block technique for the anterior tract. Bone tissue is always taken from a bilateral site (the mandibular ramus or symphysis).

The selected subjects had a residual jaw height of at least 8 mm, in association with only vertical defects in the posterior sector and only horizontal defects in the anterior aesthetic area.

The follow-up was on average 19 months after delivery of the implant-supported prosthesis.

The grafting technique used was horizontal and vertical onlays, which were then fixed in place with osteosynthesis devices (1.5 mm diameter screws).

The grafts were then covered with a membrane and the flap repositioned.

Eight out of 15 of the harvested subjects underwent both anterior and posterior grafting, while seven underwent anterior susceptibility only.

The authors confirm the excellent efficacy of the onlay technique in anterior horizontal and posterior vertical defects.

The authors suggest using bone grafting of extra-oral origin in two conditions: when the residual alveolar bone height of the jaw is less than 8mm or when the disparity between the two arches is such that corrective osteotomies are required (29).

Garcia-Denche et al. compare in their study the nasal floor elevation technique with the sinus floor elevation technique, two techniques usable to treat jaws with atrophy in the anterior and posterior region, respectively.

The study collected the follow-up of 14 patients with 78 implants, 37 in the nasal fossa and 41 in the maxillary sinus.

The implant success of the two techniques was compared. The authors state that there was no statistically significant difference in terms of surgical success.

The authors conclude that this technique is safe and effective for placing implants in atrophic premaxillae, with radiographic, clinical success comparable to those placed in the maxillary sinus (30).

Nissan et al. evaluate in their study how the age of the patient receiving the bone graft can influence the quality and quantity of newly formed bone.

The study thus collected data from 93 consecutive patients suffering from alveolar bone atrophy. The patients were classified as young, if under 40 years of age, and old if over 40 years of age.

Of the 122 grafts selected for this study, 58 were in the anterior maxilla, 32 in the posterior maxilla and 32 in the posterior mandible.

The bone tissue used was always cancellous bone-block, mineralised, freeze-dried.

The bone deficit measured by CT in the anterior maxilla was always at least 3 mm horizontally and 3 mm vertically.

Morphometric evaluation of the biopsy was performed in the anterior maxilla four months after surgical grafting.

The anterior maxilla showed a statistically significant different response in bone regeneration between young and old patients, 38.6% and 19.8%.

Thus, the authors conclude that the response from alveolar bone following anterior maxillary grafting is related to the patient's age. They finish declaring that a more extended period of consolidation and healing of the graft is advisable for older patients (31).

Tallarico et al. present a case report of bone atrophy in the anterior maxilla using a custom 3D printed titanium mesh.

The case presented a young patient with severe, localized bone atrophy. The lesion is localized at the level of the right superior central incisor. The lesion is treated with a bone implant placed in the same surgical session of the GBR (guided bone regeneration).

A graft of autologous bone tissue and inorganic bovine bone was made to fill the bone gap in a 1:1 ratio.

Autogenous bone tissue is harvested at the same implant site on a cortical bone harvesting drill. The titanium mesh is removed four months after surgery, and a platelet-rich fibrin (PRF) membrane is applied to accelerate healing.

The authors agree that GBR can give satisfactory results in bone defects in the anterior maxilla. The authors point out that this surgical technique's learning curve is very high, and that teamwork is essential for successfully applying the latest technologies available (32).

De Souza et al. present a retrospective study of marked maxillary bone atrophy treated with bone graft in the maxilla and autologous bone graft in the anterior maxilla.

The autologous bone graft is a cortico-spongy type taken from the anterior iliac crest. The graft is sectioned into smaller portions and stabilised in place using titanium osteosynthesis screws.

The survival rate of the implants and the satisfaction/confidence of the prosthetic patients were then evaluated.

Between 6 and 8 implants were placed in the ten patients and of the 76 implants placed only one failed four years after surgery.

Therefore, the authors conclude that the proposed study, although it includes a relatively limited population of patients, shows that autologous bone grafting of the iliac crest provides a good bone base for the survival of the implants. Patients report satisfactory masticatory function, aesthetic rehabilitation and perfect speech function (33).

Nissan et al. in their study evaluate the morphogenetic properties of an autologous spongy tissue bone graft in the anterior maxilla with bone atrophy.

They collected data from 40 patients, with 60 grafts and 83 implants in total. The patients' initial bone deficit was at least 3 mm in the horizontal direction and 3 mm in the vertical direction.

The average follow-up of this study was 48 months, with a survival rate of 98.8%.

The authors found statistically significant differences in histomorphometric examination between young and elderly (>40 years) subjects. The authors conclude that allograft of spongy bone is an osteoconductive procedure that provides excellent results in the atrophic anterior maxilla and that the response depends on the patient's age (34).

Pelegrine et al. evaluate the use of autologous bone marrow aspirate as an adjunct in xenograft bone regeneration techniques.

The authors collected data from 8 patients treated with xenograft, 4 of whom had bone marrow aspirate. The transplantation in both patients was covered by collagen membrane. Dental implant placement was then performed four months after the first surgery, and the bone harvested through the drill was examined. CT scans were also performed at three-time intervals: pre-operatively, 4 and 8 months after surgery.

The authors found that subjects who had received a bone marrow aspirate had a greater tendency towards mineralisation. The authors also conclude that the study presented is limited to a tiny sample of the population and that further studies would be needed to strengthen the conclusions (35).

Urban et al., present a series of clinical cases of patients with bone atrophy of the anterior maxillary sector treated with autologous bone and hydroxyapatite grafting using the guided bone regeneration (GBR) technique.

The protocol involves the preparation of a 1:1 mixture of autologous bone and inorganic hydroxyapatite of bovine origin.

Data were collected from six patients who required anterior bone regeneration for implantation. The bone graft mixture was always inserted between the bone gap and the titanium-reinforced membrane, all covered with a polytetrafluoroethylene membrane. The membrane is then removed nine months after surgery.

The authors then proceeded to apply the implants employing surgical guidance. The implants were inserted up to the correct crestal level. The remaining bone gap was filled with the same mixture of autologous and bovine bone in a ratio of 3:7 in order to restore vertical dimension and re-generate bone in the interproximal area.

Two months after implant placement, the authors performed soft tissue surgery to recover the physiological thickness of the gingival mucosa.

At six months after this surgery, the authors proceed with a modified apical repositioning soft tissue surgery to recover the depth of the vestibule.

Two months after this soft tissue surgery, the implants are exposed, and the healing stumps are applied.

The authors conclude the study by stating that intraoral bone and soft tissue regeneration techniques can allow the correct aesthetics and functionality of the anterior prosthesis to be achieved. The authors then point out how the mixture of autologous bone and inorganic bovine bone can help in the regeneration of bone in the peri-implant area and act as a support for the interdental papillae regeneration (36).

Nissan et al. present a study in which bone deficiency in the anterior maxilla is treated with an allograft of freeze-dried cancellous bone and subsequent implants placement.

There were 31 patients, all of whom had a combined horizontal and vertical defect of at least 3 mm as measured by CT.

The authors evaluate the bone regeneration on 46 allograft blocks in total, as 15 patients were grafted with two blocks and 16 with only one block. The blocks were stabilized with a 1.6 mm diameter by 10 mm long osteosynthesis screw.

A total of 63 implants were applied, 19 of which had a prosthetic crown applied at the surgery time.

Bone regeneration was assessed six months after surgery at the time of the second implant placement surgery.

The grafts were integrated and fused with the surrounding bone tissue.

No vertical bone loss was evaluated at the time of implant surgery.

The survival rate of the bone grafts and implants was measured, and the results were 95.6% and 98% respectively at the 59-month follow-up.

The authors conclude that in-block grafting of freeze-dried spongy bone tissue may be a viable surgical alternative. The authors suggest that the comparison of bone loss in the vertical and horizontal directions of the bone graft should be better evaluated. They conclude by stating that it might be good to compare single grafts with multiple bone block grafts (37).

De Freitas et al. present a randomized clinical trial evaluating bone regeneration in the anterior maxilla employing recombinant bone morphogenetic protein 2 (rhBMP-2) on a resorbable collagen sponge support.

They collected data from 24 patients treated with guided bone regeneration (GBR) using titanium mesh. Patients were treated with autologous spongy bone harvested in the retromolar region of the mandible or with rhBMP-2 at a concentration of 1.5 mg per ml.

Bone regeneration at the thick ridge level showed statistically significant differences in favor of rhBMP2. Measurements at the mid, apical and crestal levels did not show statistically significant differences.

At six months after regeneration surgery, the mesh was removed, and a total of 62 dental implants were placed with no statistically significant difference between the two groups.

Therefore, the authors conclude that bone morphogenetic protein may be an alternative for the treatment of anterior maxillary bone atrophy (38).

Monje et al. present a study comparing the volume of regenerated bone in an atrophic anterior maxilla treated with autologous bone grafting.

Data were collected from 19 patients treated with mandibular bone grafting in minor isolated defects, and bone grafting from the iliac crest in the case of more severe bone atrophy.

The blocks were anchored in the jawbone using 1.5 mm diameter osteosynthesis screws.

In both cases, the autologous bone was placed on a base with xenograft particles covered with a collagen membrane.

Bone thickness was evaluated employing a CT study and measured at 5,7 and 11 mm depth from the crestal margin five months after regeneration surgery.

The authors found increased bone regeneration with a statistically significant difference in the ileum wing graft (4.93 mm vs 3.23 mm in the mandibular ramus).

The authors conclude that this combination of autologous bone grafting and xenograft can be considered an excellent alternative in bone regeneration of the implant purpose's anterior maxilla (39).

Checchi et al. present a classification of complications during bone regeneration techniques in the anterior maxilla.

The authors agree with the literature that complications can be classified into partial and complete failures.

These techniques are not entirely predictable and do not always guarantee the expected result, especially in the atrophic maxilla.

Because of the unpredictability of these procedures, it is necessary to discuss the possibility of complications with the patient from the beginning of therapy, especially with those with high aesthetic needs and expectations.

Again, the authors state that regeneration techniques are not entirely predictable techniques and that they can provide different results from those hoped for by affecting the patient's aesthetic expectations.

The authors thus classify failures in class from I to IV.

Subjects with class I lesions present surgery with optimal aesthetic and functional results with soft tissue deficits that can be treated with mucogingival surgery.

Subjects with a class II lesion have surgery that did not provide the expected aesthetic result, not providing sufficient bone volume in the buccal direction. When treated with a second bone graft, subjects present good function but with unsatisfactory aesthetic results.

Subjects with a class III lesion show complete failure, requiring a second regeneration surgery. Following this procedure, the patients have satisfactory functional and aesthetic results.

Subjects with class IV are subjects with class III who have undergone a second surgery and negative results. The patients suffer from severe tissue deficits and severe and unacceptable aesthetic and functional impairment.

The authors conclude that it is essential to explain to patients the possible complications of any surgical procedure. It is even more critical in patients with anterior maxillary bone atrophy because of the high aesthetic and functional expectations (40).

Tirone and Salzano present a collection of 3 clinical cases of anterior maxillary bone atrophy treated with connective tissue grafting. The three cases present an initial bone volume sufficient for implant placement. The collected cases present loculated and severe bone atrophy following dental extraction, periodontal complications, and surgery to remove root cysts, respectively.

During the same impaling surgery, the subjects underwent connective tissue grafting from the palate in the first two cases and from the maxillary tuberosity area in the third.

The results collected by the authors show an excellent aesthetic result 2 and 4 years after surgery.

The authors conclude that connective tissue grafting can provide excellent aesthetic satisfaction for patients if the bone base is sufficient to apply implants (41).

Varol et al. present a retrospective study of 10 patients with severe maxillary anterior atrophy treated with multidisciplinary methodology.

The ten patients underwent corrective osteotomy via Le Fort I and autologous bone grafting from the ileum, soft tissue rehabilitation (labial sulcus plastic surgery) and subsequent implant rehabilitation.

The technique's average advancement was 9 mm in the horizontal direction and 8 mm in the vertical direction. The iliac bone graft was preloaded in the posterior region in 3 patients and the anterior region in 7.

Of the total 98 implants used, 80 were placed in the maxilla and 18 in the mandible, with a success rate of 93.75% at four years.

Marginal bone regrowth at four years after surgery was statistically significantly higher in subjects with eight implants than in those with six and ten implants.

The authors conclude the study by stating that the proposed multidisciplinary technique represents a valid alternative in subjects suffering from severe maxillary atrophy who must undergo implant rehabilitation (42).

Mazor et al. present a retrospective cohort study of 32 patients treated with implant surgery and simultaneous nasal floor elevation in case of maxillary anterior bone deficits.

Subjects were diagnosed with bone atrophy in a pre-operative CT study, and implant survival at follow-up was evaluated.

The authors collected data from 32 patients treated with 100 implants and simultaneous bone regenerative surgery.

The average nasal floor elevation was 3.4 mm and never more than 6 mm, as recommended in the literature.

The survival rate of the implants at 27 months was 100%, and no implant failures were diagnosed.

The authors conclude that the proposed surgical technique can be an application procedure in case of marked atrophy of the anterior maxillary sector. The authors agree that high implant survival may be related to the high stability of these implants. The surgery technique provides for a bicortical anchoring of the implants. The two anchorage points are respectively at the level of the alveolar ridge and at the level of the nasal cavity (43).

Angelo et al. evaluate in their study the stability of regenerated maxillary bone obtained using a minimally invasive Piezotome-enhanced subperiosteal tunnel-technique. The biomaterials used were a type of self-hardening calcium phosphate, in association or not with an autologous plasma derivative, the platelet-rich fibrin (PRF).

The authors collected data from 82 patients with horizontal bone atrophy in the maxillary anterior region. A total of 109 implants were then placed, and the results are compared with data on the stability of implants placed in the maxillary sinus.

Implant stability was significantly better in regenerated bone than in native bone with values two times higher. The authors conclude that regenerated bone has better biomechanical quality than native bone.

The authors conclude that the keys to good regeneration surgery are using an atraumatic technique, immobilisation of the grafted biomaterial and the possible use of autologous bio-active derivatives (44).

Bastos et al. present a case report of a 48-year-old patient with generalised maxillary atrophy undergoing bone regeneration surgery.

The autograft used is bone taken from the calvaria region and is used for simultaneous anterior and posterior regeneration.

The surgical procedure involves triturated autologous bone for sinus lift and onlay block technique for the regeneration of the anterior alveolar ridge.

The portion of bone taken was divided into 12 blocks and distributed between posterior sector five and seven anterior sectors.

At six months after grafting, eight implants were placed, and two bone biopsies were taken.

The 2-year follow-up offers satisfactory functional and aesthetic results without implant failure.

Therefore, the authors conclude that calvarial bone grafting can be a valid surgical alternative if correctly planned and offers biocompatibility, an optimal aesthetic and functional result for the patient (45).

Sjöström et al. evaluate in their study factors that may influence implant failure in the regenerated bone.

They collected data from 46 patients who had undergone onlay regeneration using autologous bone blocks taken from the anterior iliac crest. The implant surgery was performed six months after graft healing. Intraoperatively, implant stability was assessed employing resonance frequency analysis, and implant failure was recorded.

The failure is assessed in the pre-prosthetic phase up to a follow-up of 3 years after the rehabilitation application.

The authors found an average loss of 37% of the autograft volume during the initial healing phase of the bone graft, which is statistically correlated to the average bone density of the L2 and L4 lumbar vertebrae.

All other values analysed in the study did not correlate with bone resorption or implant placement (46).

Enriquez et al. present a clinical case of a patient with enteric maxillary bone atrophy treated with a multidisciplinary technique.

The patient presented bone atrophy secondary to edentulousness previously treated with removable partial dentures.

According to the Kushner technique, the patient underwent bone regenerative surgery with self-transplantation from the tibia to recover only the horizontal dimension of the maxilla.

Five months later, the prosthetic rehabilitation continued with three dental implants, 2 in the left jaw and one in the right.

The definitive fixed prosthesis applied involves replacing both lost dental elements and missing gum tissue (Misch classification type FP3).

The results collected by the authors reveal an optimal aesthetic and functional satisfaction of the patient (47).

Sentineri et al. present a case report for a trans-crestal nasal floor elevation technique.

The minimally invasive technique is performed at the same time as implant surgery.

The patient presented with generalized maxillary bone atrophy after long-term (30 years) use of removable total dentures.

The treatment involved bone regeneration of the posterior sector by sinus lift and of the anterior sector by nasal floor resurfacing.

The maxillary sinuses were prosthesised nine months from the graft healing with five implants.

In the same surgical session, the maxillary anterior sector underwent trans-crestal elevation of the nasal floor and simultaneous placement of 3 implants.

The elevation was performed progressively with a hydrodynamic pressure control system.

The authors then applied a collagen xenograft of porcine origin and dental implants.

The bicortical implants were placed with high torque.

At five months, the healing implants were applied, and implant rehabilitation proceeded.

The authors conclude that the surgical technique described can be a viable minimally invasive alternative for atrophic maxillary anterior augmentation with a bone deficit of no more than 6 mm. However, they always conclude that further in-depth studies are needed (48).

4.3 Wiley Library Mandible

Knight et al. present a clinical case of mandibular bone regeneration with autograft from an intr-oral region.

The patient with a mandibular prosthesis with poor tissue retention underwent implant surgery and bone regeneration.

The marginal part of the knife-edge mandible was osteotomized. The harvested tissue was used for horizontal bone regeneration of the residual anterior ridge.

The bone grafts were perfectly healed on CT examination at eight months. The ridge had an average increase in the thickness of 3.5 mm.

At eight months after surgery, the implants were inserted, and the definitive prosthesis was applied.

The authors conclude that this technique can reduce surgery's invasiveness by allowing the creation of a single surgical site. Valid alternative, according to the authors, to bone harvesting from the mandibular ramus (49).

Mordenfeld et al. present a study to evaluate the correct ratio of deproteinized bovine bone mixed with autogenous bone. Patients are treated with mixtures of different percentages of the product and the implants' survival two years after their insertion is evaluated.

Data from 13 patients with four mandible and ten maxillae suffering from bone atrophy were collected. 9:1 and 6:4 mixtures of bone substitute: autologous bone were applied in the patients' two jaws and compared.

The rate of implant survival was 94.4% in the case of the 9:1 mix and 100% in the case of the 6:4 mix.

The difference in the thickness of the regenerated alveolus was not statistically significant.

The graft reduction was statistically more significant in the 9:1 mixes (54.4% vs 37.5%).

The authors conclude that these mixtures are a valid option in the regeneration of alveolar bone atrophy in both the anterior and posterior sectors, and both the maxilla and mandible (50).

Zhang et al. present a study using a GBR technique with titanium mesh in the anterior maxilla with horizontal and vertical bone regeneration and simultaneous implant application.

Twelve patients and a total of 16 implants were evaluated.

A bovine mineral bone substitute was used in all patients. An average bone regeneration achieved was 3.61 mm vertically and 3.10 mm horizontally.

The authors conclude that this surgical technique may be up-and-coming for bone regeneration in the aesthetic field (51).

Mendoza-Azpur et al., in their study, evaluate the bone regeneration of atrophic alveoli by GBR technique in combination with or without autologous bone grafting of mandibular origin.

Data from 42 patients with 42 atrophic sites between the maxilla and mandible are collected.

All patients received particle xenograft as graft and were covered with a collagen membrane.

The two treatments differed in the addition of autologous bone and the use of GBR.

After 6-9 months, the implants were inserted, and after six months they were placed for a total of 65 implants.

Thirty-one implants were placed in subjects with autologous bone grafting and 34 in patients with GBR.

The graft was taken in most cases from the mandibular ramus (only 3 cases from the symphysis).

The regeneration site was located in 22 cases in the anterior maxilla, 21 in the anterior mandible; the remaining 22 cases in the posterior sectors.

The survival rate was 100%.

The authors conclude that both treatment options are proper techniques for the regeneration of atrophic bone structures, whether maxillary or mandibular. The authors point out that the only disadvantage of autologous bone grafting may be related to the harvesting site's morbidity (52).

Chaushu et al. present a collection of clinical cases of patients with bone atrophy of the mandibular anterior sector.

The patients were treated with cancellous bone autograft.

Data were collected from 14 patients with a horizontal-vertical combi-bone deficit of at least 3 mm.

At six months after surgery, a total of 26 implants were placed.

A total of 24 grafts were placed with an average bone gain of 5 mm horizontally and 2 mm vertically. The survival rates were 91.6% and 100% for blocks and implants, respectively.

The authors conclude that the use of spongy bone grafting in the regeneration of anterior mandibular atrophies is auspicious, although further studies are needed (53).

Atef et al. present an article comparing cortical grafting of atrophic mandibles using the only technique in the anterior and interpositive techniques in the posterior sector.

Twenty patients were treated 10 with one technique and 10 with the other. The grafts were harvested from the mandibular symphysis for the onlay technique, while for the interposition technique the osteotomy was performed at the level of the branch of the mandible and then reinserted into the site.

The residual spaces were filled in both surgical techniques with xenograft in bovine bone particles.

The patients were re-evaluated four months after surgery with CT.

Statistically significant differences were found at CT follow-up in the mean width of the regenerated bone.

The authors conclude that both surgical techniques, although in different areas, offer promising results for horizontal regeneration of the atrophic mandible (54).

Atef et al. present a comparative study to evaluate the best barrier to be associated with GBR techniques.

Thus, 20 patients treated with autologous graft mixed with bovine particulate graft in a 1:1 ratio are compared. Ten patients are treated with a collagen membrane and another 10 with titanium mesh.

The average bone volume gained was 4mm for collagen-treated patients and 3.7mm for those with metal mesh. However, the titanium mesh cases showed four soft tissue complications.

No significant differences were found between the two groups at six months.

The authors conclude that both the proposed techniques are satisfactory, but GBR with titanium mesh is more sensitive, complicated and prone to complications. The authors suggest the use of GBR with metal mesh only in case of horizontal oxygenations (55).

Wiltfang et al. present a retrospective cohort study comparing the use of vertical regeneration of the atrophic maxilla and mandible with an onlay technique.

The atrophies were defined as anterior and posterior, severe and combined in horizontal and vertical directions.

Two groups of 40 patients were compared. A thin layer of a demineralized bovine bone matrix was applied over the iliac bone block in one half.

In the subjects who received bone matrix, the atrophy was localized in the mandible in 8 cases, in the maxilla in 26 and combined in 6.

In subjects who did not receive bone matrix, the atrophy was localized in the mandible in 6 cases, in the maxilla in 30 and combined in 4.

The patients were compared radiographically at six months, 1 and 2 years after surgery.

The authors agree that the bovine bone matrix reduces long-term postoperative bone resorption from the radiographic evaluations. The authors suggest that this finding is important for younger patients and a better long-term prognosis of the graft (56).

Stellingsma et al. present a prospective study with clinical and radiographic evaluation of patients with marked mandibular atrophy treated with overdentures.

Three groups of 20 patients each underwent three different treatment plans: in group 1 trans mandibular implants were used, in group 2 implants applied after autologous bone grafting, and group 3 short dental implants.

In the patients treated with grafts, the graft was taken from the anterior iliac crest and applied using the interposition technique. Three months after surgery, four dental implants were placed in the regenerated anterior sector.

Follow-up was extended to 2, 5 and 10 years after surgery. Implant survival, complication rates and peri-implant bone loss were evaluated.

The authors found statistically higher implant failure in the group with trans mandibular application and bone grafting (76.3% and 88% respectively) than in the short dental implants (98.8%).

Despite these data, the retreatment rate of grafted patients was only 5%.

The authors concluded that the first treatment of choice for implant applications in atrophic mandibles should be short dental implants and secondly the use of bone regeneration (57).

Tang et al. evaluate in a retrospective study the long-term results of the ridge expansion technique in patients suffering from bone atrophy in maxilla and mandible.

The authors collected data from 168 patients who underwent a regenerative technique and subsequent implant surgery. According to the surgery performed, the subjects are divided into expansive techniques in combination with guided bone regeneration.

Dental implants are then inserted at six mediums after the first surgery, and the subjects are followed up clinically and radiographically.

At 2.8 years after the 226 implants (164 in anterior sector) were placed, none failed.

The two groups' success rates were 93.2 and 95.6% (without and with GBR respectively).

The authors conclude that alveolar ridge expansions are a valid technique alone or GBR for satisfactory bone regeneration (58).

Chiapasco et al. present a retrospective study of 72 patients with severe maxillary and mandibular bone atrophy due to edentulism, treated with autologous bone grafting from calvaria.

The data of 72 patients treated with autologous bone graft combined with bovine xenograft granules and collagen membrane are collected.

The subjects had a severe alveolar ridge defect with residual horizontal dimensions of less than 3 mm and vertical dimensions of less than 6 mm and a combined deficit.

4-9 months after the first surgery, a total of 330 implants are placed, and the follow-up extends from 3 to 19 years postoperatively.

Of these implants, 201 were located in the maxilla and 129 in the mandible.

The implants' average survival rate was 98.5%, and only 1 of the lost implants was located in the anterior sector of the mandible.

The authors concluded that bone tissue regenerated by calvaria transplantation is stable over time and associated with high implant survival rates. The aesthetic and functional results, depending on the evaluation of the patients, were very satisfactory.

The authors conclude that calvaria self-transplantation is a valid alternative in severe bone atrophy with stable and reliable long-term results (59).

Geng et al. evaluate sandwich osteotomy's effectiveness in a retrospective study of the sandwich osteotomy technique in an atrophic mandible for subsequent implant insertion.

Data are collected from patients with vertical bone atrophy of the mandible due to patient or total edentulism.

The implant survival rate for follow-up of 58 months on average is evaluated.

A total of 75 procedures were performed, and 220 implants applied.

The implant survival rates were 97.6% and 95.1% in patients with partial and complainant edentulism, respectively, with no correlation with patient age or disease status.

In patients with partial edentulism, the vertical dimension of the anterior sector of 5.9 mm was greater than that of the posterior sector alone.

The same results were obtained in complete edentulism with respective gains of 8.3 and 7.8 mm in the anterior and posterior areas.

The authors conclude that the regenerative sandwich technique can provide more significant bone gains in the anterior than in the posterior area.

The authors conclude that the sandwich osteotomy technique is a viable option with high yields and in cases of severe mandibular atrophy, with high and promising implant survival rates (60).

Merli et al. present a short-term control trial comparing the use of autologous bone and a mixture of autologous bone and bovine bone matrix (1:1) in end-grafting GBR.

30 subjects with extensive bone atrophy located in the maxilla and mandible of both anterior and posterior sectors are included in the study.

In both cases, the graft was covered with a collagen membrane, and a titanium osteosynthesis plate was used as a barrier.

The autologous graft is collected from intra-oral sites, in particular from the mandibular ramus region.

The authors evaluated post-operative pain and regenerated bone value in the vertical direction six months after surgery.

The authors conclude the study by stating that patients undergoing autologous bone grafting alone had a higher post-operative pain than the second group.

Subjects receiving the 1:1 mixture of autologous bone and bovine xenograft had on average a larger vertical dimension of regenerated bone at the CT scan six months post-surgery.

The authors found no other significant differences between the two groups according to the anatomic region (maxilla vs mandible or anterior vs posterior) (61).

Deeb et al. present a study evaluating the effect of biologically active agents in addition to particulate bone grafts for the treatment of bone atrophy.

Data from 43 patients who underwent 52 bone grafts were collected retrospectively.

Regions of bone atrophy were treated with freeze-dried allograft and bovine xenograft. Simultaneously, the biologically active bio-grafts were platelet derivatives such as PRP and platelet-derived growth factor (rhPDGF-BB) factors.

In 21 patients, the combination of the two graft materials and biologically active factors was administered.

A total of 10 anterior and 42 posterior sectors were collected, divided into 17 maxillae and 35 mandibles.

The mean gain in bone volume was 3.6 mm, and no statistically significant difference was noted between the two groups in the absence or addition of biologically active materials.

The authors found a greater horizontal bone dimension at the end of regeneration in the posterior sector than in the anterior sector.

The authors concluded that the addition of biologically active materials did not provide statistically significant results on the volume of regenerated bone, the only difference being the bone density of the grafted area, which was better in the group treated with biomaterials (62).

Chiapasco et al., present a study of long-term evaluation of fibula autografts and implant survival rates.

The authors collected data from 12 patients undergoing transplantation for edentulous maxilla and mandible affected by severe bone atrophy. A total of 75 implants were placed.

In total, the authors performed the surgery in 8 maxillas and four mandibles affected by severe generalized bone atrophy.

The authors report a very satisfactory implant survival rate of 95.8%. Despite this, a high percentage of marked peri-implant bone loss was reported in the follow-ups, more marked in the maxilla than in the mandible.

The authors conclude that autologous vascularized fibula bone transplantation should only be used in minimal cases with severe bone atrophy where any other type of transplantation would not be sufficient.

The authors also conclude that despite the high rate of implant stability, the bone volume gained is not stable over time, with higher bone resorption rates than native bone (63).

Mertens et al. compare in their study the bone resorption undergone by autologous bone grafts taken from the ileum or calvaria region.

The bone grafts were applied in the atrophic jaws and mandibles of 23 patients.

The application technique follows the onlay technique.

Of the 23 patients, 9 received the graft from the iliac crest.

The authors collected the data of 12 maxillae, seven mandibles and four patients were treated with combined maxilla and mandible treatment. Data were collected from 27 surgical procedures, 16 of which in patients with generalised edentulism and 11 with localised atrophy.

Of 99 implants evaluated, 49 were located in the anterior sector and 50 in the posterior sector.

During the follow-ups, the radiographic evaluation showed significantly worse bone resorption for the ileum than for the calvaria (24.26% vs 8.44%).

Nevertheless, implant stability was similar.

The authors found no difference between treated bone segments, whether maxilla or mandible, anterior or posterior.

The authors conclude that with the study's limitations, calvaria bone grafting has better stability over time than iliac bone grafting (64).

Miyamoto et al. evaluate in their study the qualitative and quantitative results of bone regeneration obtained employing GBR in patients with bone atrophy for implant placement.

The authors collected data from 41 patients for a total of 50 bone regeneration sites treated with autologous bone harvested intraorally or from bone tissue harvested from the wing of the ileum and titanium mesh.

Surgical sites were also harvested, and survival implanted evaluated.

A total of 19 anterior and ten posterior maxilla, two anterior and 19 posterior mandibles were treated. Bone defects were 59% horizontal in the maxilla and 71% combined horizontal-vertical in the mandible.

Among the complications reported, the authors reported soft tissue problems such as suture dehiscence and mesh exposure or bone tissue complications with partial or complete graft failure.

The authors proceeded to implant 47 sites of regeneration with a total of 87 implants.

Only 1 case of implant failure was reported.

The authors report an implant survival rate of 92.8% at 96 months after surgery.

The authors find significantly more bone resorption in horizontal-vertical complex defects.

The authors conclude that a higher number of complications were found in combined horizontal and vertical defects. In general, the surgical technique allows obtaining qualitatively and quantitatively optimal bone regeneration in each anatomical sector treated (65).

Mertens et al. evaluate in their study the use of calvaria autograft in the treatment of intraoral bone atrophy and implant end.

They collected data from 15 patients with a total of 15 maxillae, four mandibles affected by bone atrophy.

Bone regeneration of horizontal and vertical defects of the anterior sector was performed using the onlay technique. In the case of a combined bone defect in the posterior sector, the authors performed sinus lift surgery.

After three months, a total of 99 implants were placed, and the average follow-up was 28 months. The implant success and survival rates were 95.7 and 97.85%, respectively.

The authors conclude that calvaria bone grafting presents an excellent alternative to iliac bone tissue. The low rate of complication at the harvest site, the low degree of bone resorption of the graft and the good implant survival results are all factors favoring this type of bone graft (66).

Kumar et al. evaluate in their study the effectiveness of the ridge split technique and the changes in peri-implant hard tissue in the phases following implant placement.

They collected data in a prospective study of 10 patients with edentulism of 1-3 elements, a residual ridge thickness of at least 3 mm and a residual vertical distance of at least 8 mm from the main anatomical structures.

A total of 10 implants were thus placed using the surgical technique, 13 in the mandible and 7 in the maxilla, of which only 5 in the anterior sector (3 maxilla and two mandibles). The difference between pre- and post-operative buccolingual dimensions (horizontal dimension) was statistically significant.

The authors conclude that the surgical technique, although in the absence of bone grafting, is a valid alternative with a reduced overall rehabilitation duration and excellent results. However, the authors point out that it is impossible to regenerate previously lost vertical dimensions with this technique (67).

4.4 Wiley Libray Maxilla

Monje et al., in their study, present a clinical case of a patient suffering from severe localized bone atrophy due to edentulousness located in the left super lateral incisor.

The patient was treated with a surgical technique of GBR, and platelet enriched plasma combined with autologous bone grafting for three-dimensional regeneration of the defect.

The patient presented a significant horizontal defect with only residual palatal cortical and a horizontal defect of 14.5 mm on the CT study.

The surgical procedure involved using autologous bone from the mandibular ramus measuring 15 mm by 7,9 mm. The surgeons applied the grafts to both the palatal and vestibular surfaces and stabilized them by osteosynthesis screws. A particulate xenograft, collagen membrane and PRP were used to stimulate tissue healing.

The authors concluded that the surgery's functional and aesthetic results were optimal in the absence of bone resorption, possible inflammation or implant failure (68).

Kulkarni et al. present two clinical cases of bone atrophy in the jaw's aesthetic area treated with autologous bone grafts of mandibular origin.

The first case shows bone atrophy in the maxillary right lateral incisor and the canine's second case.

Both cases presented combined horizontal and vertical defects and were treated with a combined vestibular and palatal bone graft application.

The graft is collected at the level of the mandibular symphysis and maintained in place employing osteosynthesis screws.

Slight reductions in the grafted bone volume with values between 10 and 15% of the bone volume have been observed in the preoperative phase.

Five months after the first surgery, the dentists placed the dental implants.

Clinical and radiographic follow-ups at three years are excellent with successful implantation and stability of both bone and gingival tissue, with optimal aesthetic results (69).

Kolerman et al. evaluate in their study the long-term results of the technique of alveolar ridge expansion with osteotomy, dental implant placement and bone regeneration in a single surgical step.

The 41 patients collected had bone atrophy of the upper maxilla, with horizontal resorption of 2.5-5 mm.

A total of 35 procedures (116 total implants) were finally reported, 24 of them in the anterior sector, with a follow-up of 52.4 months on average.

At the vestibular cortex level, the authors performed perforations of the cortical plate, allotting mineralised cortical allograft, stabilised in place employing a collagen matrix.

The authors conclude that the few complications reported were localised in tiny residual alveolar ridges. Therefore, the planning of the surgical technique is the key to the correct evolution of the protocol.

They, therefore, conclude that the technique can be widely applied in cases of maxillary anterior and posterior bone atrophy where the residual bone ridge is not less than 2.5 mm thick (70).

Chappuis et al. evaluated bone resorption and implant survival rate in regenerated bones of both maxillae or mandibles in posterior and anterior aesthetics in their prospective study.

Data were collected from 52 bone regeneration sites treated with bone graft en bloc for horizontal regeneration. The block was stabilised employing osteosynthesis screws, covered with autologous bone particles mixed with a xenograft and covered with a collagen membrane.

All follow-ups were extended to 10 years post-surgery with an implant success rate of 98.1% and slight bone resorption (0.17 mm maxilla and 0.09 mm mandible).

The authors found a better survival rate in autografts harvested in the symphysis than in the mandibular retromolar region. No differences were found concerning the anatomical region (the maxillary or mandibular), even in the anterior or posterior part.

Similarly, users did not find any age-related differences in the patients, but there were gender-related correlations; females showed more resorption than males.

The authors conclude that the technique offers optimal results with success in 98.1% of cases and minimal bone resorption of 7.7% (71).

Mounir et al. report in their study, two different material barriers used in the GBR technique in patients with bone atrophy in the maxilla, both anterior and posterior sectors.

Sixteen patients were selected and divided into two groups. In both cases, a 1:1 mixture of autologous bone from the ileum and xenograft was used.

In one group, the mesh used was titanium, while in the second group, it was based on a specific "poly-ether-ether ketone".

The authors then examined the percentage of newly formed bone at one week and six months after surgery employing a CT scan study.

The results showed no statistically significant difference between test groups, and only 1 case of a minor soft tissue complication was found two weeks after surgery.

The authors conclude that both techniques can be used indiscriminately in patients with localized bone atrophy requiring GBR, whether in the anterior or posterior region (72).

El Zahwy et al. compare in their study 2 techniques of bone regeneration in the external sector of the anterior maxilla using spongy cortical bone taken at the mandibular symphysis level as autograft.

Patients with 1-3 edentulous elements and vertical bone deficiency with residual alveolar ridge inadequate for implant therapy were selected.

The authors collected data from 16 patients with a total of 40 implants divided into two groups: half onlay technique and half inlay technique in both cases with immediate application and stabilization employing implants.

CBCT controls were performed one week and six months after surgery.

Only 3 of the onlay-treated subjects had significant soft tissue complications leading to inlay loss.

When comparing vertical bone loss to CBXT control, the authors found significantly more significant bone gain in the sandwich inlay technique than in the control onlay technique.

The authors conclude that the proposed inlay technique may be a viable alternative in patients with vertical-only bone atrophy in the maxilla's aesthetic area (73).

Yuan et al. propose in their retrospective cohort study a new bone regeneration technique in the treatment of horizontal anterior bone atrophy at the end of implantation.

The authors collected 30 patients and subjected 15 to the "in-situ bone ring technique" and 15 to the surgical "tent-pole" technique.

In the first case, an autologous bone graft was harvested with a circular drill from the apical maxillary area and repositioned coronally at the atrophic site to be treated. A mixture of a bovine bone substitute and the patient's blood was then pre-prepared at both locations (donor and depot) and covered with a collagen membrane.

In the control cases, 1-2 titanium screws were placed at the bone deficits level, and the gap filled with bovine xenograft and finally covered by the collagen membrane.

The CT scan shows a statistically significant increase in horizontal bone volume in the subjects with autograft than in the control cases, even though the morbidity at both surgeries' surgical site is almost identical.

Therefore, the authors conclude that the proposed in-situ bone ring technique could be a viable alternative in cases of anterior horizontal bone atrophy (74).

Hosseini et al. evaluated the aesthetic result in subjects who had undergone implant surgery in the anterior maxilla to treat single edentulism.

The patients underwent hard and soft tissue grafting to regenerate atrophies of the maxilla's aesthetic area employing bone and connective tissue transplantation.

The authors reviewed 19 patients for a total of 33 implantations. In 10 patients, the surgeons also grafted connective tissue, while in 23 cases, they regenerated only bone tissue.

At the 5-year follow-up, the success rate was 93.9%, and the implant survival rate was 100%.

The gingival tissues' quality was statistically better in the ten connective tissue graft recipients than in the control cases. Satisfactory results were found for the maintenance of the horizontal dimension of the perioral (lip) tissues and the subjective assessment of mucosal coloration.

The authors conclude that connective tissue transplantation can offer better aesthetic results in the maxillary aesthetic area than cases undergoing bone regeneration alone (75).

Braidy and Appelbaum presented a clinical case with chronic and severe bone atrophy of the maxilla's anterior sector following an old trauma.

Depending on the pathology's severity, the surgeons plan a regenerative treatment in 2 phases: phase 1 vertical bone regeneration employing bone distraction; phase 2 horizontal bone regeneration employing onlay technique.

The users then apply a bidirectional bone distractor for 36 days, achieving regeneration of 1 mm in a vertical direction.

After a 3-month pause, they proceed to phase 2 with horizontal regeneration with ileum wing autograft.

At five months after the second surgery and after a CT study, they proceeded to implantation. The authors conclude that the bone distraction technique has multiple limitations and cannot be applied to all patients with vertical bone atrophy. They also conclude that planning is always an essential step to complete a bone regeneration with sufficient three-dimensional volume and optimal functionality and aesthetics for the patient (76).

Deluiz et al. evaluate in their study the complications associated with fresh-frozen bone allografts and the 1-year survival of regenerated bone graft implants.

The authors collected data from 58 patients with maxillary bone atrophy. The implant sites were 22 posterior, 19 anterior and 17 combined, respectively. 268 implants were examined in total.

In a decreasing number of cases: 7 mucosal perforations, six infections and five suture dehiscences occurred. Only seven patients had graft complications (4 partial and three total).

The failure rate was 5.97% in 12 of the 58 total patients (20.70% of the sample).

Significant correlations were found between infection, suture dehiscence, and graft loss; no correlation was found between the surgical anatomical area (anterior vs posterior).

The authors conclude that the best management of complications is an early diagnosis to avoid total graft loss (77).

5. Discussions

From the literature review we selected 26 articles dealing with mandibular bone atrophy (21-26, 40, 42, 46, 49, 50, 53, 54, 56-67, 71), 46 with the maxilla (26-48, 50-52, 56, 58, 59, 61-77) and 14 with atrophy in both bone segments (40, 42, 46, 50, 56, 58, 59, 61-67, 71).

We collected data from 1386 patients who underwent a bone regeneration technique in the anterior aesthetic sector of the maxilla or mandible. As already reported in the results collection, the bone atrophies could be more, or less, generalized (with edentulism of the whole dental arch) or more localized (the anterior sector only or even, in some cases, single edentulism).

Not all the articles examined included total implant surgery, 2235 in the regenerated sectors and were evaluated with clinical and radiographic follow-up.

In some studies, the rate of implant survival at follow-up was evaluated (37, 42, 43, 50, 52, 53, 59, 60, 63, 65, 66, 71, 75, 77). The results obtained always exceeded 90% (minimum survival value of 92.8% found by Miyamoto et al. (65)), and in some articles, the results were completely successful (100% in 43, 52, 53, 75).

In 12 cases, autografts of cortico-spongiosous bone taken from the ileum wing were used (21, 27, 33, 39, 42, 46, 56, 57, 64, 65, 72, 76).

In 4 cases, the autologous graft was collected at the calvaria level (45, 59, 64, 66) and applied in all cases except one (45 only in the maxilla) at the level of both atrophic arches. According to the data collected by the authors, it seems that this graft, if well planned, can be an excellent alternative to other harvesting sites, whether intra-oral or extra-oral.

In one article (64), the authors dwell on the fact that the calvaria graft is even more stable over time and resistant than other graft types.

Only one article of those collected (47) presents a case of employment of fibula with vascular bone graft for the treatment of upper jaw atrophy, and the authors recommend it only in particular and selected clinical circumstances.

In 14 of the selected articles, a jaw graft was used. The authors used the various harvesting sites available for the mandible, symphysis (22, 29, 54, 71, 73) or ramus (29, 49, 54, 1, 68, 71). In two articles, the mandibular collection site was not specified (32, 52), while one article presented an alternative grafting technique (26). In this proposed clinical case, the authors (26) use the remnants of the "knife blade" mandible alveolar ridges to undergo ostectomy as an initial step in the surgical procedure. The material collected was used for bone regeneration. In this circumstance, the bone harvesting site would inevitably undergo a reduction in its vertical dimension as a step in the surgical procedure. In this respect, the users suggest using the same "waste" material as a perfect material for the maxilla's aesthetic area.

In a few cases, the authors used an autograft of the maxillary bone (32, 36, 50, 76) in all instances mixed with bovine xenograft.

In all the articles examined, the authors drew attention to the importance of using collagen membranes as the last layer of protection for the regenerative material applied at the site of bone atrophy.

In 8 of the selected cases, bovine xenograft was used in addition to the autograft (32, 36, 50, 56, 59, 61, 62, 74). This material is used as a mixture with the graft or as a base to reduce the gaps between the graft and the underlying bone or even out the graft's outer surface. Therefore, one can consider how sometimes the volume of transplant material is the key to the success of the surgery and that xenografts can help in the case of reduced volumes of material.

Only one article (38) presents the use of recombined morphogenetic bone proteins, rhBMP-2, for osteoinductive purposes in bone regeneration. The authors also, in this case, do not give us

the volume of material used, but only the essential concentration of the drug/growth factor used (rhBMP-2 in ACS 1.5 mg/ml). And the authors conclude that the quality of bone regenerated in the presence of morphogenetic proteins is better than that of control cases. The authors' conclusions suggest that these proteins (whether autologous or of recombinant origin) play an essential role in bone healing processes and that this is even though their use is scarce in the literature (1 out of 57 articles reviewed).

If we focus on re-evaluating the surgical techniques used, alveolar bone distraction is one of the least used. We collected only four articles dealing with such surgery in the maxilla (28 and 76) and mandible (23 and 24) of the anterior sector. The authors agree that it is a relatively complex technique and can be used only in selected cases and with high patient compliance that may allow the correct management of the distraction device even if the regenerated bone quality is always optimal.

In the article proposed by Osterne (28), the bone distraction technique performed after implantation could be up-and-coming, but the scientific basis to support it is still lacking nowadays. It might be a good idea to propose an evaluation of peripheral bone distraction techniques (techniques involving the use of the Ilizarov system, for example) with intraoral techniques. In terms of achievable bone gain, patient satisfaction, and sheer feasibility of the procedure.

These results can be compared with the sandwich osteotomy technique (60), where applied in the mandible, it allows optimal results in the anterior sector compared to the posterior sector.

An up-and-coming surgical technique with excellent bone integration results is the elevation of the nasal floor in treating bone atrophy in the aesthetic sector of the anterior maxilla (30, 43, 48). Although the authors differ slightly in the surgical techniques used, they all agree on the excellent results obtained with these implants. The implants' superior primary stability applied

in bicortical fashion, and the technique's reduced invasiveness allow results comparable to maxillary sinus lift techniques for the posterior sector. In the first two articles, no bone grafts were used, while in the third case, porcine xenograft was used.

In another article (57), the authors compare three surgical techniques for treating anterior mandibular bone atrophy. The authors found statistically higher implant failure in the group with the trans-mandibular application and bone grafting (76.3% and 88% respectively) than in the short dental implants (98.8%). These results on the stability of bicortical implants in the mandible compared with the excellent results of the articles dealing with nasal floor elevation (30, 43, 48) leave one wondering about the biomechanics of the two anatomical bases. In the maxilla, we have an efficiency of 100% in 3 studies, while in the mandible, the implant success rate does not reach 80%. (30, 43, 48, 57).

Among the most used surgical techniques is the onlay mode, 11 articles in the maxilla (29, 33, 39, 45, 46, 56, 64, 66, 69, 73, 76) and 6 in the mandible (22, 46, 54, 56, 64, 66) the results obtained were always optimal regardless of the origin of the bone structure used, ileum, mandible or calvaria. In one article (39), better results were obtained when grafting from the ileum than from the mandible. In article 56, the authors point out that adding a layer of bovine xenograft may help reduce bone resorption over a more extended period of time in these bone graft cases. In article 73, the onlay technique is compared with the inlay technique in anterior butchery and, with the same graft used and location of the latter, inlay offers statistically better results and could be a valid alternative to standard onlay. In article 76, however, the clinical case's complexity could be the key to the results obtained. The onlay technique is used, as mentioned above, as a second phase after bone distraction for severe bone deficiency, and the results obtained are excellent.

Authors in 2 articles (25 and 67) presented the ridge split technique and compared the results obtained in mandible and maxilla and in both cases got promising results. In the first case, a PRF graft was used to stimulate healing of both hard and soft tissues.

Another highly used technique with excellent results in the maxilla is the GBR technique (32, 36, 38, 52, 51, 55, 58, 61, 65, 68, 72). Only in a few cases is it used in the mandible (50, 61, 65). Various bone materials were used, whether taken from the maxilla (32, 36) or mandible (52, 61, 68, 72). Only in one case, a morphogenetic bone protein base was used as a biomaterial (38).

In general, the material used in these surgeries is titanium-based and is always covered with a collagen membrane. Only in one article (72) is the use of a new polymer made of "polyether-ether ketone" compared to the titanium currently used compared to titanium (72 and 55). In one article (61), the authors reported pain at the site of autologous bone harvesting, and it would be appropriate to evaluate this parameter as a possible complication/event in a more general way. Morbidity and pain at the harvesting site had already been described at the level of the introduction as the main inconvenience in the case of autologous bone graft harvesting. In another article (65), the authors find significantly more bone resorption in horizontal-vertical complex defects. Reading such conclusions, we may suggest that sometimes surgeons decide to use more invasive GBR techniques in more complex cases, with bone atrophies with very marked three-dimensional deficiencies, which may be more challenging to approach clinically. For this reason, the results and conclusions obtained may be difficult to compare with techniques such as onlay in localised bone atrophies (73 to 74), for example.

In some articles, the optimal ratio between the autologous bone graft and bovine substitute is examined with different ratios: autologous maxilla and bovine 1:1, autologous maxilla and bovine 3:7 (36) in the maxilla, autologous maxilla and bovine 9: 1 vs 6:4 (50) both maxilla and

mandible, mandibular ramus and bovine bone matrix 1:1 (61) both maxilla and mandible, 1:1 mixture of autologous bone from the Iliac bone and xenograft (72) maxilla.

No statistically significant differences were found in (32, 36, 72) while in other cases, the users found some differences. For example, in one case, subjects receiving the 1:1 mixture of autologous bone and bovine xenograft had, on average, a larger vertical dimension of regenerated bone at the CT (61). In another article evaluating the implant survival rates between 2 mixtures (9:1 and 6:4) were compared. The results were 94.4 vs 100% for the implant survival rate; and 54.4% vs 37.5% in bone resorption (50).

Links between bone regeneration and age have been shown in a few articles (31-38).

According to some authors who have applied a cut-off point of 40 years (31), elderly patients have slower bone regeneration in the anterior jaw and a longer maturation time for grafting should be anticipated. Such differences in the quality of regenerated bone have also been noted by other authors (38), also in the maxilla, describing a better histomorphogenetic quality in young subjects.

Conclusions

According to the data collected from the articles examined and the discussions are drawn, we can state that in all the cases studied, regardless of the type of surgical technique performed and the type of biomaterial used, the results are consistently excellent and with a low risk of failure.

Following what was defined in the initial draft of our thesis, the objectives of the work were:

1: To identify the best bone grafting and surgical treatment for the treatment of anterior maxilla bone atrophy.

2: To identify the best bone grafting and surgical treatment for the treatment of anterior mandible bone atrophy.

We are going to list the conclusions of this work.

Adaptations can be made by the surgeon who is faced with a technical challenge in patients with low compliance, high severity three-dimensional defects and high aesthetic and functional expectations. It is then up to the surgeon to decide which of the proposed multimodal approaches to follow and how best to address the technical challenge.

Of all the biomaterials used, autologous bone grafting represents a "master" in surgical procedures, accompanied by the interposition of collagen membranes for retention purposes and better guidance in tissue growth.

It is up to the surgeon to decide whether to perform a small volume intra-oral tissue harvest in the first instance but easier to harvest or schedule a second surgery under general anesthesia to harvest bone from the anterior iliac crest.

On the other hand, we can conclude that bone harvesting at the calvaria and tibia site should be used for a reduced number of more complex and selected cases and perhaps not purely dental interest but more akin to maxillofacial surgery.

In the case of adding a xenograft to autologous bone tissue, the bovine biomaterial comes out on top.

It is still difficult to determine the correct mixture to be preferred, but an attraction ranging from 50:50 to 90:10, through 60:40 in favor of autologous tissue could quickly be suggested as a proper guideline.

Among the described surgical techniques, GBR with titanium mesh and autologous bone graft mixed with bovine xenograft and onlay techniques represent a large part of our case history.

For this reason, we can conclude that in case of severe three-dimensional bone defects of the anterior sector, be it maxillary or mandibular, the GBR technique with mesh allows an almost optimal recovery of the missing bone base.

On the other hand, if the surgeon is forced to deal with more localized bone atrophy, mainly of horizontal or vertex type and not combined, the onlay technique, regardless of the kind of cortical-spongiosum graft selected, represents a very valid surgical alternative, both in the maxilla and in the anterior mandible.

There is a small group of clinical cases with very severe maxillary or mandibular bone atrophies that can be a challenge for the surgeon, and bone distraction, according to Ilizarov's biomechanics, is a weapon that can help.

As seen in some articles, age should be taken into account when dealing with this type of patient with bone atrophy in the aesthetic sector. While it is true that each patient is a case in point, it should be borne in mind that patients in the middle age group of 40 years have a more poor response in terms of bone biology and fall into the category of elderly patients who need more appropriate treatment.

I would like to explore more deeply the use of tissue growth factors such as rhBMP-2 used in one of our examined articles to boost bone regeneration and improve regenerated bone quality. Growth factors could offer an excellent boost and support to all those patients who could present an altered bone turnover and regeneration due to age or metabolic problems in general.

Responsibility

As already widely described in this work, the intra-oral bone atrophy of the anterior sector of the maxilla and mandible has a functional, aesthetic and psychological impact that is certainly significant for the patient.

The patient's expectation is very high because of the impact that these lesions have at a private level (both functional and certainly aesthetic) and at a social level (primarily aesthetic and psychological in this case).

Considering the high availability of surgical techniques and biomaterials available today in the dental sector, it is, in my opinion, essential to promote the preparation of today's and tomorrow's surgeons to face these challenges.

In a society that is increasingly giving importance to the 'aesthetics' and 'appearance' of the person, it seems to me anachronistic to think that we are not able to deal with these bone lesions in the best possible way and give the patient a more dignified life.

It is undoubtedly true that the technical-synthetic preparation required to meet these challenges is superior to the basic preparation provided by a regular university academic program. Nevertheless, I believe it is important to study this sector in greater depth at postgraduate and specialist level in order to better understand, treat and, as far as possible, prevent these bone atrophies.

References

1. Iocca O, editor. Evidence-based implant dentistry. 1st ed. Cham, Switzerland: Springer International Publishing; 2016.
2. Cullum DR, DePorter D. Minimally invasive dental implant surgery. Cullum DR, Deporter D, editors. Chichester, England: Wiley-Blackwell; 2015.
3. Tolstunov L. Horizontal alveolar ridge augmentation in implant dentistry: A surgical manual. Dmd LTD, editor. Hoboken, NJ: Wiley-Blackwell; 2016.
4. Tolstunov L, editor. Vertical alveolar ridge augmentation in implant dentistry: A surgical manual. Hoboken, NJ: Wiley-Blackwell; 2016.
5. Froum SJ, editor. Dental implant complications: Etiology, prevention, and treatment. 2nd ed. Nashville, TN: John Wiley & Sons; 2015.
6. Toronto Osseointegration Conference Revisited (2008: Toronto, Ont.). Osseointegration and Dental Implants. Jokstad A, editor. Ames, IA: Iowa State University Press; 2009.
7. Lowe JS, Anderson PG. Stevens & Lowe's Human Histology. 4th ed. London, England: Mosby; 2014.

8. Tortora GJ. Principles of anatomy and physiology, 15e WileyPLUS card. 15th ed. Nashville, TN: John Wiley & Sons; 2016.
9. Nanci A. Ten cate's oral histology: Development, structure, and function. 9th ed. Nanci A, editor. Philadelphia, PA: Elsevier - Health Sciences Division; 1998.
10. Fehrenbach MJ, Herring SW. Illustrated anatomy of the head and neck. 5th ed. Philadelphia, PA: Saunders; 2016.
11. Rodríguez MD, González JMM. Donado cirugía bucal: patología y técnica. 4th ed. Barcelona, Spain: Elsevier Masson; 2013.
12. Hupp JR, Tucker MR, Edward Ellis III. Contemporary Oral and Maxillofacial Surgery. 7th ed. St. Louis, MO: Mosby; 2018.
13. Chiapasco M, Casentini P, Zaniboni M. Bone augmentation procedures in implant dentistry. Int J Oral Maxillofac Implants. 2009;24 Suppl:237-59.
14. Trisi P, Rao W. Bone classification: clinical-histomorphometric comparison: Human morophic bone classification. Clin Oral Implants Res. 1999;10(1):1-7.

15. Revised. Computed Tomography–Based Lekholm and Zarb Jawbone Quality Classification Asma'a A. Al-Ekrish;
16. Harpenau LA. Hall's Critical Decisions in Periodontology. 5th ed. Shelton, CT: PMPH- ; 2013.
17. De Santis G, Cordeiro PG, Chiarini L, editors. Atlas of mandibular and maxillary reconstruction with the fibula flap: A step-by-step approach. 1st ed. Cham, Switzerland: Springer Nature; 2019.
18. Schoenbaum TR, editor. Implants in the aesthetic zone: A guide for treatment of the partially edentulous patient. 1st ed. Cham, Switzerland: Springer International Publishing; 2018.
19. Greenberg AM, Schmelzeisen R, editors. Craniomaxillofacial reconstructive and corrective bone surgery. 2nd ed. New York, NY: Springer; 2019.
20. Erverdi N, Motro M. Alveolar distraction osteogenesis: The ArchWise appliance and technique. 2nd ed. Cham, Switzerland: Springer Nature; 2020.
21. Ghassemi A, Ghassemi M, Modabber A, Knobe M, Fritz U, Riediger D, et al. Functional long-term results after the harvest of vascularised iliac bone grafts

- bicortically with the anterior superior iliac spine included. *Br J Oral Maxillofac Surg.* 2013;51(4):e47-50.
22. Cohen A, Lavi A, Alterman M, Casap N. Nonfixated inlay graft for anterior localized mandibular defect. *Oral Surg Oral Med Oral Pathol Oral Radiol.* 2020;130(1):e1-4.
 23. Kumar KAJ, Masrom AK, Patil K, Kunusoth R, Begum F, Venkatesh V. Evaluation of vertical bone gain following alveolar distraction osteogenesis in the anterior edentulous mandible: A clinical study. *J Maxillofac Oral Surg.* 2014;13(4):539-45.
 24. Ergun G, Nagas IC, Yilmaz D, Ozturk M. Prosthetic rehabilitation of edentulous ridges following alveolar distraction osteogenesis: clinical report of three cases. *J Oral Implantol.* 2011;37 Spec No(sp1):183-91.
 25. Mahendra J, Parthiban P, Lakshmi R, Sreekumar K, Namasivayam A. A contemporary approach for treatment planning of horizontally resorbed alveolar ridge: Ridge split technique with simultaneous implant placement using platelet rich fibrin membrane application in mandibular anterior region. *Indian J Dent Res.* 2017;28(1):109.
 26. French D, Tallarico M. Eight-year clinical and radiologic results of maxillary and mandibular implant-retained bar overdentures carried out on oxidized (TiUnite™)

replace select implants placed in regenerated bone: a clinical case. *Quintessence Int.* 2014;45(2):135–40.

27. Dasmah A, Thor A, Ekestubbe A, Sennerby L, Rasmusson L. Marginal bone-level alterations at implants installed in block versus particulate onlay bone grafts mixed with platelet-rich plasma in atrophic maxilla. a prospective 5-year follow-up study of 15 patients: Bone level at implant installed in grafted bone. *Clin Implant Dent Relat Res.* 2013;15(1):7–14.
28. Osterne RLV, Nogueira RLM, Abreu RT, Cavalcante RB, Medeiros ÉA, Mello M de JR. A retrospective study of an alternative technique for implant repositioning in the maxillary esthetic region. *Clin Implant Dent Relat Res.* 2018;20(6):915–22.
29. Cordaro L, Boghi F, Mirisola di Torresanto V, Torsello F. Reconstruction of the moderately atrophic edentulous maxilla with mandibular bone grafts. *Clin Oral Implants Res.* 2013;24(11):1214–21.
30. Garcia-Denche JT, Abbushi A, Hernández G, Fernández-Tresguerres I, Lopez-Cabarcos E, Tamimi F. Nasal floor elevation for implant treatment in the atrophic premaxilla: A within-patient comparative study. *Clin Implant Dent Relat Res.* 2015;17 Suppl 2:e520-30.

31. Nissan J, Kolerman R, Chaushu L, Vered M, Naishlos S, Chaushu G. Age-related new bone formation following the use of cancellous bone-block allografts for reconstruction of atrophic alveolar ridges. *Clin Implant Dent Relat Res.* 2018;20(1):4–8.
32. Tallarico M, Park C-J, Lumbau AI, Annucci M, Baldoni E, Koshovari A, et al. Customized 3D-printed titanium mesh developed to regenerate a complex bone defect in the aesthetic zone: A case report approached with a fully digital workflow. *Materials (Basel).* 2020;13(17):3874.
33. de Souza CSV, Ortega-Lopes R, Barreno AC, de Moraes M, Albergaria-Barbosa JR, Nóia CF. Analysis of the survival of dental implants installed in reconstructed maxilla with autogenous iliac crest graft: 7- to 9-year follow-up. *J Oral Implantol.* 2019;45(6):427–36.
34. Nissan J, Marilena V, Gross O, Mardinger O, Chaushu G. Histomorphometric analysis following augmentation of the anterior atrophic maxilla with cancellous bone block allograft. *Int J Oral Maxillofac Implants.* 2012;27(1):84–9.
35. Pelegrine AA, Teixeira ML, Sperandio M, Almada TS, Kahnberg KE, Pasquali PJ, et al. Can bone marrow aspirate concentrate change the mineralization pattern of the

- anterior maxilla treated with xenografts? A preliminary study. *Contemp Clin Dent*. 2016;7(1):21–6.
36. Urban IA, Monje A, Wang H-L. Vertical ridge augmentation and soft tissue reconstruction of the anterior atrophic maxillae: A case series. *Int J Periodontics Restorative Dent*. 2015;35(5):613–23.
 37. Nissan J, Mardinger O, Calderon S, Romanos GE, Chaushu G. Cancellous bone block allografts for the augmentation of the anterior atrophic maxilla: Cancellous block allograft in the anterior atrophic maxilla. *Clin Implant Dent Relat Res*. 2011;13(2):104–11.
 38. de Freitas RM, Susin C, Spin-Neto R, Marcantonio C, Wikesjö UME, Pereira LAVD, et al. Horizontal ridge augmentation of the atrophic anterior maxilla using rhBMP-2/ACS or autogenous bone grafts: a proof-of-concept randomized clinical trial. *J Clin Periodontol*. 2013;40(10):968–75.
 39. Monje A, Monje F, Hernández-Alfaro F, Gonzalez-García R, Suárez-López del Amo F, Galindo-Moreno P, et al. Horizontal bone augmentation using autogenous block grafts and particulate xenograft in the severe atrophic maxillary anterior ridges: A cone-beam computerized tomography case series. *J Oral Implantol*. 2015;41 Spec No(S1):366–71.

40. Checchi V, Gasparro R, Pistilli R, Canullo L, Felice P. Clinical classification of bone augmentation procedure failures in the atrophic anterior maxillae: Esthetic consequences and treatment options. *Biomed Res Int.* 2019;2019:4386709.
41. Tirone F, Salzano S. Esthetic treatment of alveolar ridge atrophy in the anterior maxilla via connective tissue graft performed simultaneously with implant placement: A three-case series. *Quintessence Int.* 2018;49(10):801–7.
42. Varol A, Atali O, Sipahi A, Basa S. Implant rehabilitation for extremely atrophic maxillae (Cawood type VI) with Le Fort I downgrafting and autogenous iliac block grafts: A 4-year follow-up study. *Int J Oral Maxillofac Implants.* 2016;31(6):1415–22.
43. Mazor Z, Lorean A, Mijiritsky E, Levin L. Nasal floor elevation combined with dental implant placement: Nasal floor elevation combined with dental implant placement. *Clin Implant Dent Relat Res.* 2012;14(5):768–71.
44. Angelo T, Marcel W, Andreas K, Izabela S. Biomechanical stability of dental implants in augmented maxillary sites: Results of a randomized clinical study with four different biomaterials and PRF and a biological view on guided bone regeneration. *Biomed Res Int.* 2015;2015:850340.

45. Bastos AS, Spin-Neto R, Conte-Neto N, Galina K, Boeck-Neto RJ, Marcantonio C, et al. Calvarial autogenous bone graft for maxillary ridge and sinus reconstruction for rehabilitation with dental implants. *J Oral Implantol*. 2014;40(4):469–78.
46. Sjöström M, Sennerby L, Lundgren S. Bone graft healing in reconstruction of maxillary atrophy: Bone graft healing. *Clin Implant Dent Relat Res*. 2013;15(3):367–79.
47. Enríquez A, Sánchez E, Guizar JM, Del Campo CM, Fandiño LA. Esthetic restoration with artificial gingiva in an atrophied alveolar ridge: Clinical report. *Int J Periodontics Restorative Dent*. 2016;36(4):567–71.
48. Sentineri R, Lombardi T, Celauro A, Stacchi C. Nasal floor elevation with transcrestal hydrodynamic approach combined with dental implant placement: A case report. *Int J Periodontics Restorative Dent*. 2016;36(3):357–61.
49. Knight WM, Ashnagar S, Vattikunta L, Misch CM, Fallah-Abed P. Utilizing edentulous ridge as autogenous block graft for buccal contouring horizontal ridge augmentation. *Clinic Adv Periodontics* [Internet]. 2020;(cap.10138). Available from: <http://dx.doi.org/10.1002/cap.10138>

50. Mordenfeld A, Aludden H, Starch-Jensen T. Lateral ridge augmentation with two different ratios of deproteinized bovine bone and autogenous bone: A 2-year follow-up of a randomized and controlled trial. *Clin Implant Dent Relat Res.* 2017;19(5):884–94.
51. Zhang T, Zhang T, Cai X. The application of a newly designed L-shaped titanium mesh for GBR with simultaneous implant placement in the esthetic zone: A retrospective case series study. *Clin Implant Dent Relat Res.* 2019;21(5):862–72.
52. Mendoza-Azpur G, de la Fuente A, Chavez E, Valdivia E, Khoully I. Horizontal ridge augmentation with guided bone regeneration using particulate xenogenic bone substitutes with or without autogenous block grafts: A randomized controlled trial. *Clin Implant Dent Relat Res.* 2019;21(4):521–30.
53. Chaushu L, Chaushu G, Kolerman R, Vered M, Naishlos S, Nissan J. Anterior atrophic mandible restoration using cancellous bone block allograft. *Clin Implant Dent Relat Res.* 2019;21(5):903–9.
54. Atef M, Osman AH, Hakam M. Autogenous interpositional block graft vs onlay graft for horizontal ridge augmentation in the mandible. *Clin Implant Dent Relat Res.* 2019;21(4):678–85.

55. Atef M, Tarek A, Shaheen M, Alarawi RM, Askar N. Horizontal ridge augmentation using native collagen membrane vs titanium mesh in atrophic maxillary ridges: Randomized clinical trial. *Clin Implant Dent Relat Res.* 2020;22(2):156–66.
56. Wiltfang J, Jätschmann N, Hedderich J, Neukam FW, Schlegel KA, Gierloff M. Effect of deproteinized bovine bone matrix coverage on the resorption of iliac cortico-spongy bone grafts - a prospective study of two cohorts. *Clin Oral Implants Res.* 2014;25(2):e127-32.
57. Stollingsma K, Raghoobar GM, Visser A, Vissink A, Meijer HJA. The extremely resorbed mandible, 10-year results of a randomized controlled trial on 3 treatment strategies. *Clin Oral Implants Res.* 2014;25(8):926–32.
58. Tang Y-L, Yuan J, Song Y-L, Ma W, Chao X, Li D-H. Ridge expansion alone or in combination with guided bone regeneration to facilitate implant placement in narrow alveolar ridges: a retrospective study. *Clin Oral Implants Res.* 2015;26(2):204–11.
59. Chiapasco M, Tommasato G, Palombo D, Scarnò D, Zaniboni M, del Fabbro M. Dental implants placed in severely atrophic jaws reconstructed with autogenous calvarium, bovine bone mineral, and collagen membranes: A 3- to 19-year retrospective follow-up study. *Clin Oral Implants Res.* 2018;29(7):725–40.

60. Geng Y-M, Zhou M, Parvini P, Scarlat S, Naujokat H, Abraha SM, et al. Sandwich osteotomy in atrophic mandibles: A retrospective study with a 2- to 144-month follow-up. *Clin Oral Implants Res.* 2019;30(10):1027–37.
61. Merli M, Nieri M, Mariotti G, Merli M, Franchi L, Quiroga Souki B. The fence technique: Autogenous bone graft versus 50% deproteinized bovine bone matrix / 50% autogenous bone graft-A clinical double-blind randomized controlled trial. *Clin Oral Implants Res.* 2020;31(12):1223–31.
62. Deeb JG, Reichert A, Carrico CK, Laskin DM, Deeb GR. Effect of biologic materials on the outcomes of horizontal alveolar ridge augmentation: A retrospective study. *Clin Exp Dent Res.* 2021;7(2):147–55.
63. Chiapasco M, Romeo E, Coggiola A, Brusati R. Long-term outcome of dental implants placed in revascularized fibula free flaps used for the reconstruction of maxillo-mandibular defects due to extreme atrophy: Long-term outcome of dental implants placed in revascularized fibula free flaps. *Clin Oral Implants Res.* 2011;22(1):83–91.
64. Mertens C, Decker C, Seeberger R, Hoffmann J, Sander A, Freier K. Early bone resorption after vertical bone augmentation--a comparison of calvarial and iliac grafts. *Clin Oral Implants Res.* 2013;24(7):820–5.

65. Miyamoto I, Funaki K, Yamauchi K, Kodama T, Takahashi T. Alveolar ridge reconstruction with titanium mesh and autogenous particulate bone graft: computed tomography-based evaluations of augmented bone quality and quantity: Alveolar reconstruction with titanium mesh. *Clin Implant Dent Relat Res*. 2012;14(2):304–11.
66. Mertens C, Steveling HG, Seeberger R, Hoffmann J, Freier K. Reconstruction of severely atrophied alveolar ridges with calvarial onlay bone grafts and dental implants: Reconstruction with calvarial onlay bone grafts. *Clin Implant Dent Relat Res*. 2013;15(5):673–83.
67. Kumar I, Singh H, Arora SS, Singh A, Kumar N. Implant placement in conjunction with ridge split and expansion technique. *Oral Surg*. 2019;12(3):214–23.
68. Monje A, Monje F, Suarez F, González-García R, Villanueva-Alcojol L, Moreno C, et al. Vertical and horizontal ridge augmentation of a severely resorbed ridge in the anterior maxilla. *Clinic Adv Periodontics*. 2013;3(4):230–6.
69. Kulkarni SS, Thakur SL, Kamath SS. Reconstruction of extensive Bucco-palatal defects using twin block grafts: A clinical report of the sandwich technique in two cases. *Clinic Adv Periodontics*. 2016;6(4):182–9.

70. Kolerman R, Nissan J, Tal H. Combined osteotome-induced ridge expansion and guided bone regeneration simultaneous with implant placement: a biometric study: Combined osteotome and GBR-induced implant placement. *Clin Implant Dent Relat Res.* 2014;16(5):691–704.
71. Chappuis V, Cavusoglu Y, Buser D, von Arx T. Lateral ridge augmentation using autogenous block grafts and guided bone regeneration: A 10-year prospective case series study. *Clin Implant Dent Relat Res.* 2017;19(1):85–96.
72. Mounir M, Shalash M, Mounir S, Nassar Y, El Khatib O. Assessment of three dimensional bone augmentation of severely atrophied maxillary alveolar ridges using prebent titanium mesh vs customized poly-ether-ether-ketone (PEEK) mesh: A randomized clinical trial. *Clin Implant Dent Relat Res.* 2019;21(5):960–7.
73. El Zahwy M, Taha SAAK, Mounir R, Mounir M. Assessment of vertical ridge augmentation and marginal bone loss using autogenous onlay vs inlay grafting techniques with simultaneous implant placement in the anterior maxillary esthetic zone: A randomized clinical trial. *Clin Implant Dent Relat Res.* 2019;21(6):1140–7.
74. Yuan S, Mu Z, Huang Y, Bai S, Xu P, Chen T. Comparison of in-situ bone ring technique and tent-pole technique for horizontally deficient alveolar ridge in the anterior maxilla. *Clin Implant Dent Relat Res.* 2020;22(2):167–76.

75. Hosseini M, Worsaae N, Gotfredsen K. Tissue changes at implant sites in the anterior maxilla with and without connective tissue grafting: A five-year prospective study. *Clin Oral Implants Res.* 2020;31(1):18–28.
76. Braidy H, Appelbaum M. Alveolar distraction osteogenesis of the severely atrophic anterior maxilla: Surgical and prosthetic challenges. In: *Journal of Prosthodontics on Complex Restorations*. Hoboken, NJ, USA: John Wiley & Sons, Inc.; 2016. p. 167–74.
77. Deluiz D, Oliveira L, Fletcher P, Pires FR, Nunes MA, Tinoco EMB. Fresh-frozen bone allografts in maxillary alveolar augmentation: Analysis of complications, adverse outcomes, and implant survival. *J Periodontol.* 2016;87(11):1261–7.

Image1: Bone osteon or Haversian system (9), page 94.
Image2: Maxilla anatomy (3), page 9.
Image3: Mandible anatomy (3), page 13.
Image4: Lekholm and Zarb classification of bone atrophy (3), page 73.
Image5: Siebert classification of bone atrophy (3), page 73.
Image6: GBR in titanium mesh for anterior sector (32), pag 4
Image7: Flow chart of bibliographic research
Table1: Exclusion criteria
Image8: Flow chart of exclusion criteria

Anexo	Study model	Number of patients	Numbers of implants	Implant's survival rate %	Graft	Surgical procedure	difference	Maxillo	Mandible
21	retrospective	1			Iliac bone				yes
22	observational	4			mandibular symphysis	onlay			yes
23		10				osteogenic alveolar distraction			yes
24	case report	1				osteogenic alveolar distraction			yes
25	case report	1			PRF	ridge split technique			yes
26	case report	1			mandible alveolar ridge			yes	yes
27	prospective	15			Iliac bone, PRP	in blok		yes	
28		13	25			osteogenic alveolar distraction		yes	
29		15(7)			mandibular ramus or symphysis	onlay		yes	
30		14	37			nasal floor		yes	
31		93	58				age	yes	
32	case report	1			autologous maxillo and bovine 1:1	GBR		yes	
33	retrospective	10	76		Iliac bone	onlay		yes	
34		40	83				age	yes	
35		8			xenograft vs bone marron aspirate		bone marron better minaralization	yes	
36	case series	6			autologous maxillo and bovine 1:1, autologous maxillo and bovine 3:7	GBR		yes	
37		31	63	98	allograft of freeze-dried cancellous bone (1-2 books per patient)			yes	
38	randomised clinical tria	24	62		rhBMP-2 in ACS (1,5 mg/ml)	GBR	better bone quality in rhBMP-2 group	yes	

	Study model	Number of patients	Numbers of implants	Implant's survival rate %	Graft	Surgical procedure	difference	Maxillo	Mandible
39		19			mandibular bone or Iliac bone and xenograft	onlay	better results in ilieum graf	yes	
40						compilation evaluation		yes	yes
41		3			connective tissue (palate)			yes	
42	retrospective	10(7)	80+18	93.75	Iliac bone	Le Fort I , soft tissue rehabilitation (labial sulcus plastic surgery)		yes	yes
43	retrospective	32	100	100		nasal floor elevation		yes	
44		82	109		self-hardening calcium phosphate, in association or not with an autologous plasma derivative, platelet-rich fibrin.	Piezotome-enhanced subperiosteal tunnel-technique	rigenerate bone better than native	yes	
45	case report	1			calvaria	onlay		yes	
46		46			Iliac bone	onlay		yes	yes
47	case report	1	3		tibia			yes	
48	case report	1			porcine xenograt	trans-crestal nasal floor elevation	bone deficit <6mm	yes	
49	case report	1			mandible alveolar ridge		alternative to ramus		yes
50		13		94,4 vs 100	autologous maxillo and bovine 9:1 vs 6;4		54.4% vs 37.5% in bone resorption.	yes	yes
51		12	16			GBR		yes	
52		42 (22 vs 21)	31 vs 34	100	mandibular bone or nothing	GBR		yes	
53	case series	14	26	100	cancellous autograft				yes
54		10 vs 10			mandibular ramus or symphysis	onlay and intepositional			yes

	Study model	Number of patients	Numbers of implants	Implant's survival rate %	Graft	Surgical procedure	difference	Maxillo	Mandible
55		20			titanium and collagen	GBR	more compilation in titanium		
56		40			Iliac bone and bovine	onlay	bovine bone matrix reduces long-term postoperative bone resorption from the radiographic evaluation	yes	yes
57	prospective	20 vs 20 vs 20				grafts, the graft was taken from the anterior iliac crest and applied using the interposition technique.	tatistically higher implant failure in the group with transmandibular application and bone grafting (76.3% and 88% respectively) than in the short dental implants (98.8%)		yes
58	retrospective	168	164	93.2 and 95.6			expansive techniques in combination with guided bone regeneration (GBR).	yes	yes
59		72	330 (201-129)	98.5	calvaria and bovine xenograft			yes	yes
60		75	220	97.6 and 95.1		sandwich osteotomy	regenerative sandwich technique can provide more significant bone gains in the anterior than in the posterior area.		yes

	Study model	Number of patients	Numbers of implants	Implant's survival rate %	Graft	Surgical procedure	difference	Maxillo	Mandible
61	short term control trial	30 (15-15)			mandibular ramus and bovine bone matrix (1:1) i	GBR with titanium osteosynthesis plate	autologous bone grafting alone had a higher post-operative pain than the second group. Subjects receiving the 1:1 mixture of autologous bone and bovine xenograft had on average a larger vertical dimension of regenerated bone at the CT	yes	yes
62	retrospective	43			freeze-dried allograft and bovine xenograft. Simultaneously, the biologically active bio-grafts were platelet derivatives such as PRP and platelet-derived growth factor (rhPDGF-BB) factors.		The authors found a greater horizontal bone dimension at the end of regeneration in the posterior sector than in the anterior sector. The authors concluded that the addition of biologically active materials did not provide statistically significant results on the volume of regenerated bone,	yes	yes
63		12	75	95.8	fibula	vascularized flap	peri-implant bone loss was reported in the follow-ups, more marked in the maxilla than in the mandible.	yes	yes
64		23	99		Iliac or calvaria region.	onlay	radiographic evaluation showed significantly worse bone resorption for the Iliac bone than for the calvaria (24.26% vs 8.44%).	yes	yes
65		41	87	92.8%	Iliac bone	GBR	The authors find significantly more bone resorption in horizontal-vertical complex defects.	yes	yes
66		15	99	95.7 and 97.85	calvaria	onlay		yes	yes
67		10(5)			no	ridge split technique	The difference between pre and post-operative buccolingual dimensions (horizontal dimension) was statistically significant.	yes	yes

	Study model	Number of patients	Numbers of implants	Implant's survival rate %	Graft	Surgical procedure	difference	Maxillo	Mandible
68	case report	1			mandibular ramus and PRP; xenograft	GBR		yes	
69	case series	2			mandibular ramus or symphysis	onlay		yes	
70		41	116		alveolar ridge expansion with osteotomy	mineralised cortical allograft		yes	
71		52		98.1	mandibular ramus or symphysis mixed with a xenograft and covered with a collagen membrane		better in symphysis than in the mandibular retromolar region. Similarly, users did not find any age-related differences in the patients, but there were gender-related correlations; females showed more resorption than males.	yes	yes
72		16			1:1 mixture of autologous bone from the Iliac bone and xenograft	GBR, titanium vs "poly-ether-ether ketone"	no statistically significant difference	yes	
73		16 (8-8)	40		mandibular symphysis	onlay vs inlay	significantly more significant bone gain in the sandwich inlay technique than in the control onlay technique.	yes	
74	cohort	30 (15-15)			maxilla, bovine bone substitute and the patient's blood	in-situ bone ring technique vs tent-pole" technique.	increase in horizontal bone volume in the subjects with autograft than in the control cases, even though the morbidity at both surgeries' surgical site is almost identical.	yes	

	Study model	Number of patients	Numbers of implants	Implant's survival rate %	Graft	Surgical procedure	difference	Maxillo	Mandible
75		19	33 (10-23)	100	bone and connective tissue vs only bone	bone and connective tissue vs only bone	The gingival tissues' quality was statistically better in the ten connective tissue graft recipients than in the control cases. maintenance of the horizontal dimension of the perioral (lip) tissues and the subjective assessment of mucosal colouration	yes	
76	case report	1			Iliac bone	osteogenic alveolar distraction and onlay	bone distraction technique has multiple limitations and cannot be applied to all patients with vertical bone atrophy.	yes	
77		58 (19)	268	94,03			Significant correlations were found between infection, suture dehiscence, and graft loss; no correlation was found between the surgical anatomical area (anterior vs posterior).	yes	