

***TRABAJO DE FIN DE GRADO***

***Grado en Odontología***

**INVISALING SYSTEM®**

**PREDICTABILITY OF TREATMENT RESULTS**

**Madrid, curso 2020/2021**

Número identificativo

222

## **Resumen**

El sistema Invisalign® fue creado en respuesta a una creciente demanda de estética en los tratamientos de ortodoncia. Esta serie de alineadores transparentes extraíbles apenas se notan, incluso de cerca, y son más cómodos para los pacientes. Inicialmente, se describieron en el tratamiento de casos leves y moderados. Sin embargo, desde su comercialización, se han realizado muchas mejoras para ofrecer a los pacientes y a los clínicos una técnica más predecible, ampliando su alcance hacia la resolución de casos más complejos. Al tratarse de una técnica bastante novedosa y en constante evolución, los clínicos requieren protocolos y guías claras basadas en la evidencia para poder realizar el mejor juicio terapéutico.

El presente trabajo tiene como objetivo revisar la literatura actual disponible para buscar protocolos y guías claras sobre el uso clínico de Invisalign® y evaluar la predictibilidad de los resultados del tratamiento con esta técnica.

Para ello, se realizó una búsqueda electrónica en las bases de datos Pubmed, Medline complete y Cinahl con texto completo. Sólo se revisaron manualmente los artículos y libros fechados en los últimos 15 años. Se eligieron 38 artículos, que cumplían los criterios de inclusión y exclusión, después de la lectura para realizar este trabajo.

El sistema Invisalign® es capaz de resolver con precisión una amplia gama de maloclusiones dentales. Entre los diferentes tipos de movimientos dentales, la distalización molar y la inclinación bucolingual son los más predecibles, mientras que las rotaciones y los movimientos dentales verticales son los más difíciles. Todavía no existen protocolos claros basados en la evidencia para los dentistas. Se necesitan más investigaciones futuras con un fuerte nivel de evidencia.

## **Abstract**

The Invisalign® system has been created in response to a growing demand of aesthetics in orthodontic treatments. This series of removable transparent aligners are barely noticeable, even at close distance and more comfortable for patients. Initially, they were described in the treatment of mild to moderate cases. However, since its commercialization, many improvements have been made to provide patients and clinicians with a more predictable technique, extending its reach toward the resolution of more complex cases. As a fairly new technique, constantly evolving, clinicians require clear evidence-based protocols and guidelines in order to make the best therapeutical judgement.

The present work is aimed to review the current available literature to research clear protocols and guidelines on the clinical use of Invisalign® and evaluate the predictability of the treatment results with this technique.

To realize it, an electronic search was conducted on the databases: Pubmed, Medline complete and Cinahl with complete text. Only articles and books dated from the last 15 years were manually reviewed. 38 articles, meeting the inclusion and exclusion criteria, were chosen after lecture to produce this work.

The Invisalign® system is able to resolve a wide range of dental malocclusions with accuracy. Among the different types of tooth movements, molar distalization and buccolingual tipping are the most predictable ones whereas tooth rotations and vertical tooth movements are the most challenging ones. No clear evidence-based protocols are yet available to clinicians. More future researches with a strong level of evidence are required.

**INDEX :**

<b>INTRODUCTION</b> .....	<b>1</b>
<b>I. The Invisalign® system</b> .....	<b>3</b>
<b>A- Description and indications</b> .....	3
<b>B- Clinical process</b> .....	5
Patient records and scanning .....	5
Clincheck set-up creation .....	7
Fabrication of the aligners .....	8
<b>C- Technological evolution over the years</b> .....	10
.....	10
SmartTrack Material .....	10
SmartForce Features.....	11
SmartStage Technology .....	11
Clin Advisor .....	12
Evolution of Invisalign® generations over the years.....	12
<b>D- Advantages</b> .....	13
<b>E- Disadvantages and Limitations</b> .....	14
<b>OBJECTIVES</b> .....	<b>15</b>
<b>MATERIAL AND METHODS</b> .....	<b>16</b>
<b>DISCUSSION OF RESULTS :</b> .....	<b>17</b>
<b>A- Treatment duration and biomechanics</b> .....	22
<b>B- Treatment accuracy</b> .....	24
<b>C- Invisalign® and periodontal health</b> .....	25
<b>D- Invisalign® and Root Resorption</b> .....	26
<b>II. Predictability of tooth movements with Invisalign®</b> .....	<b>29</b>
<b>A- Intrusion</b> .....	29
<b>B- Extrusion</b> .....	30
<b>C- Rotation</b> .....	31
<b>D- Torque</b> .....	32
<b>E- Tipping</b> .....	34
<b>F- Molar distalization</b> .....	35
<b>G- Arch expansion</b> .....	36
<b>III. Treatment with Invisalign®: other aspects</b> .....	<b>43</b>
<b>A- Malocclusions treated with Invisalign®</b> .....	43
Crowding.....	43
Deep bite and Open bite.....	44
Space closure after extractions .....	46
<b>B- Stability of treatment outcomes</b> .....	48
<b>CONCLUSION</b> .....	<b>51</b>
<b>RESPONSIBILITY</b> .....	<b>51</b>
<b>ANNEXES</b> .....	<b>53</b>
<b>BIBLIOGRAPHY</b> .....	<b>54</b>



## **INTRODUCTION**

In the last decades, orthodontic treatments have evolved a lot to meet an increasing demand regarding the esthetics. In fact, there is a high concern of the population for physical appearance at all ages which has an important influence in one's personal and professional life. People are more and more concerned about having a pleasant smile that corresponds to a current standard of white aligned teeth therefore, there is a high demand for orthodontic treatments to correct malocclusions.

Conventionally, these malocclusions were treated with metallic braces however, this treatment option is widely considered unaesthetic. This is why more aesthetic treatment options have been developed such as ceramic tooth-colored, lingual or composite braces and clear aligners.

Clear aligners could be used as retainers or as an active orthodontic treatment. Essix and Trutain retainers are thermoformed appliances that extends into gingival undercuts used to treat minor malocclusions such as mild non-skeletal malocclusions. (1)

If we talk about the use of Clear aligners for active orthodontic treatment, we can consider Invisalign® as the promoter of the treatment with transparent aligners although in recent years new brands have appeared such as Sin park, Alineadent, Dr. Smile. As they are transparent plastic appliances, they represent a very good treatment option for patients that present mild to moderate alignment issues and are not willing to wear fixed appliances. (2)

In this work we are going to focus on the technique with Invisalign®.

The Invisalign® appliances were introduced by Zia Chishti and Keysley Wirth through Align Technologies in the late 1990s with a start of commercialization in 1999. Firstly directed to orthodontists, the practice was later made accessible to all dental practitioners who completed the formation provided by the company. The system consists in a series of individualized customed plastic transparent aligners covering the clinical crown and marginal gingiva of teeth. They are created using a three-dimensional (3D) digital technology. (2) This technique requires tremendous participation of the patient as, to be effective, each aligner of the series has to be worn 20 to 22 hours a day. (1)

This system has been shown to successfully treat certain malocclusions while others are more challenging. Over the years, many improvements have been made to increase the efficacy and predictability of the technique, allowing resolution of more complex cases. In any case, the decision to use Invisalign® aligners as treatment remains in the dentist's judgement.

Nowadays, dental practitioners are confronted, on one hand, to a lack of strong scientific evidence clearly reporting the indications and limitations of the technique and, on the other hand, to an increasing demand from patients. This work is aimed to review the literature available on this technique in order to identify the strengths and limitations of this technique and the predictability of treatment results. The objective being to research and provide clear updated guidelines on the use of this technique.

## **I. The Invisalign® system**

### **A- Description and indications**

The Invisalign® system presents itself as transparent aligners of less than 1mm thickness produced through CAD-CAM technology, each one producing tooth movement of 0.25 mm. To be effective, the aligners have to be worn 20 to 22 hours each day, being removed only for eating and oral hygiene. Every two weeks, the patient will change for the next aligner of the serie in order to continue treatment. (1)

Regarding the indications of the technique, many articles (1-4) agree that this technique is more suitable in the following situations:

- Mal aligned teeth (1-5 mm crowding or diastema)
- Deep overbite (Class II division 2 malocclusion)
- Expansion of narrow arches (4-6 mm) through tipping (dental origin)
- Distal tipping of molars
- Absolute intrusion of one or two teeth
- Severe crowding with lower incisor extraction
- Previously treated cases with mild relapse

In all these conditions, the Invisalign® treatment is indicated although the practitioner have to be careful on case and patient selection in order to obtain satisfying results.

On the other hand, although the Invisalign® system is in constant evolution, authors agree that the following pathologies are difficult to treat with this system, even sometimes contraindicated (1-5):

- Spacing or crowding > 5 mm
- Severe tooth rotation > 20°
- Severe tipping > 45°
- Open bite (anterior or posterior)
- Centric relation and centric occlusion discrepancies
- Skeletal antero-posterior problems > 2mm
- Tooth extrusion
- Multiple missing teeth in an arch
- Short clinical crowns
- Closure of space following bicuspid extraction

Moreover, in 2012, Proffit stated that it is complicated to treat ectopic canines and realize molar translation with this technique. (6) In another study, the authors explain that cases that require the extraction of premolars should not be treated with Invisalign® as it does not maintain the vertical position of teeth and produces an excessive tipping of teeth around the site of extraction. (4)

However, as the system is constantly improving, the company “Align Technology” assures that more complex tooth movements are now possible using Invisalign®. (7)

## **B- Clinical process**

Before starting the treatment planning, the clinician must choose carefully the patient and the case based on the previously explained recommendations in terms of diagnosis. (2) This includes the initial assessment and diagnosis of the patient. (4) Also, all treatment characteristics must be explained and accepted by the patient as his compliance is of tremendous importance.

Once this has been realized, the manufacturing process is divided in three phases: Patient records and scanning, followed by the creation of Clincheck set-up and finally, Fabrication of the aligners. (8)

### *Patient records and scanning*

In this first phase, the clinician will provide the Align Technology company in Santa Clara, California with recent radiographies (panoramic and/or lateral cephalometric X-Ray), intraoral and extraoral photographs, impressions of both arches and a centric occlusion bite registration, as well as the prescription or treatment plan. (2,4,8)

The impressions of both arches and the bite registration are commonly realized with Polyvinyl Siloxane (PVS) (1,2,4,8) as this material provide highly accurate impressions (negative reproduction of dental arches' hard and soft tissues) that remain stable up to 3 weeks. (2) The recommended protocol for impression taking with the PVS is the two-step one where we first use a heavy body material to create a loose-fitting custom tray before taking the definitive impression with light body material. (2) If the clinician possesses an intraoral scanner iTero, a digital impression of the arches can also be made instead.

Moreover, if the patient requires dental treatments that will modify the occlusal surface of the teeth, they must be realized prior to the impressions.

The records will be sent either digitally or by mail via UPS in an Invisalign® submission box. Digital submissions are preferred as the records will remain accessible by dentist and staff during all the treatment improving its efficiency (8).

Later, the impressions will be scanned and turned into three dimensional (3D) models. The company uses a sophisticated Computer Aided Tomography (CAT) scan with an amorphous silicon X-ray sensor where the impression is placed on a rotating platform (360°). (2,8) With this advanced technology, the impressions do not have to be poured before scanning as before.

Since 2011, the classic PVS impressions have been replaced by intraoral scanning with the Itero intraoral scanner. This system allows direct creation of a 3D model from the mouth of the patient. Apart from considerable gain of time, this procedure is also more comfortable for the patient and accurate than classic PVS impressions to obtain initial records. The mean duration of a complete intraoral scanner is 11 minutes and 58 seconds. (8)

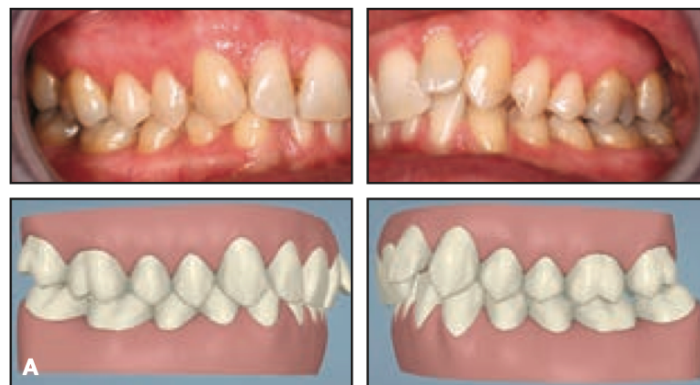

Figure 1: Initial record of a patient with intraoral Itero scanner (2)

### Clincheck set-up creation

The Clincheck is a 3D representation of the dentist's prescription which will be verified and can be modified until the clinician is satisfied. This step is the most important of the process as the clinician won't have the possibility to modify the treatment later.

It is composed of three steps: (2,8)

- The cutting process where the technician uses "Tooth shaper" to individualize the teeth into separate units on the 3D model. Virtual gums are also placed around the teeth limits to have a better simulation of the results. (2,4,8)
- The final set-up creation is the step in which the technician moves virtually the teeth individually to precisely match the prescription. (2)
- The staging process is used to determine the number of necessary intermediate stages between the initial situation and the expected final result. It will be determined by the path and the velocity of each tooth movement and matches the future number of aligners needed. (2) The number of aligners mainly depend on the complexity of the case.

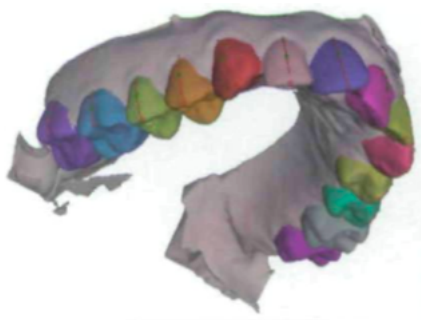

Figure 2: Image of Tooth shaper (8)

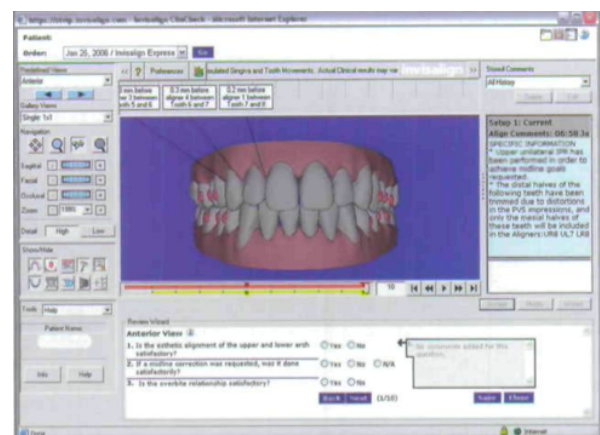


Figure 3: Image of Clincheck 2.0

Once the Clincheck has been created, the dentist will review it by considering factors such as the reality of tooth movement in each stage, the use and placement of attachments, the need of interproximal reduction (IPR), extraction, proclination, distalization or the number of aligners. If the dentist does not consider it satisfying, he can modify the treatment plan and the technician will create a new Clincheck to be verified again by the dentist. (1,2,4,8)

Finally, when the dentist is satisfied, he will accept the Clincheck and the fabrication of the aligners will start.

The Clincheck can be presented to the patient which will be useful to educate and motivate him throughout treatment. (8)

#### *Fabrication of the aligners*

Depending on the complexity of the case, an Invisalign® treatment requires 6 to 40 aligners in average for each arch. To produce them in an accurate, reproducible and cost-effective way, the Align company uses Stereo Lithography (SLA) reference models. SLA is a process that creates dental models of each intermediate step with laser technology. They are made of an Ultra-violet curable liquid resin polymer. (2,8)



Figure 4: SLA models for each arch and each stage (8)



In a second time, aligners will be vacuum formed over each SLA resin model using special plastic sheet. Also, each aligner will be laser engraved with the patient's initials, the case number, the arch (upper or lower) and the number of the aligner in the sequence. (2,4,8)

After its fabrication, the aligners will be trimmed, polished and disinfected before being prepared for shipment. (2,4)

Finally, the treatment will start when the dentist delivers the first aligner of the sequence. At this occasion, the clinician will verify the aligner's fit, place the attachments or realize IPR if necessary, provide to the patient all the necessary recommendations. Depending on the protocol chosen by the doctor, the aligner will be replaced every 15, 10 or 7 days by the following one of the sequence.

In the course of the treatment, if the clinician considers it necessary, he can ask for "mid-course correction" and new aligners will be fabricated. This situation can happen when the patient did not wear the aligners as much as necessary or when tooth movement does not match the prescription. (2)

At the end of the aligner sequence, the results will be evaluated by the dentist and, if he considers it opportune, he will start a process called "refinement" where new aligners are produced to finalize tooth movements. According to a study, orthodontists report that refinement or mid-course correction is necessary in 70 to 80% of the cases. (9,10)

To stabilize and maintain the treatment results, the dentist can choose between conventional retainers or the one offered by Invisalign® called "Vivera".

### C- Technological evolution over the years

Since its commercialization in 1999 as simple aligners without attachments in which the results were related to the practitioners' clinical experience, (5) the Invisalign® technique has evolved a lot since the company invested in research and development to provide a continuous evolution. New features such as the Smart Track material, the Smart Stage Technology, the Smart Force features and attachments, the Clin Advisor as well as the new generations of Invisalign® allowed this technique to become more performant and accurate over the years in order to be able to now treat a wide range of malocclusions. (5,11)

#### **Invisalign Technology**




Figure 5: The 3 innovations of Align Technology (11)

#### SmartTrack Material

Smart Track Material is an innovation as a medical grade polymer with additives that allow the production of thin, clear, flexible and strong products which also are biologically stable, inert and hypo-allergenic. (11) There are three different types of smart track materials: LD30 (0.75 mm) used for the aligners, EX40 (1.02 mm) for retainers and EX15 (< 0,75 mm) for templates.

Compared to the previous one (EX30), the Smart Track Material used for aligners, provide an improvement in the tracking and control of tooth movement releasing a more constant and

gentle force over the two weeks period. Moreover, this material is more elastic which reduces its likelihood to crack and confers a more precise aligner fit reducing the risk of distortion. This last improvement has increased the predictability of tooth movement up to 75%. (11) Finally, it enhances the comfort of the patient wearing aligners and reduces the treatment time up to 50% thanks to the better control of movements. (5, 11)

### SmartForce Features

The SmartForce concept was created in 2009 to overcome the impossibility of aligners alone to realize movements of tooth extrusion. (11) One of the feature consist in attachments that are placed on the buccal surface of the aligners to produce specific tooth movements such as extrusion, rotation, translation, mesial tooth movement, torque control and intrusion. Attachments are 3D geometrical shapes that enhance the interactions between the aligner and the tooth. (2). Before SmartForce, conventional attachments (rectangular, ellipsoid and beveled rectangular) were used. (11) For each type of movement there is a specific shape of optimized attachments which are presented in the Annex 1. (12)

Another feature of SmartForce are the power ridges: plastic elevations that allow the direct application of a force on a tooth that are mainly used for root torque and incisor's intrusion. (11)

### SmartStage Technology

This technology was released in 2015 in order to improve the treatment with aligners of cases requiring premolar extraction and space closure. This new technology allows firstly to modify and optimize the shape of the aligner as well as the tooth movement sequence.

This technology is the equivalent of an activation of the aligner. Combined with SmartForce attachments, it enhances the predictability of treatment results and reduces unwanted movements during space closure such as tipping or anterior extrusion. (11)

### Clin Advisor

It is a tool software available to practitioners aimed to increase the effectiveness of case selection among other things. In fact, it uses a system to rate the complexity of the case and attributes a level of “Easy”, “Moderate” or “Advanced”. A list of the potentially complex movements and expected treatment characteristics are also provided. Finally, the dentist can choose the objective of the treatment between Pre-Restorative, Esthetic (teeth alignment), Anterior Function improvement (canine guidance) and Optimal Setup (treatment of malocclusions). (2)

### Evolution of Invisalign® generations over the years

Over the last 10 years, many different versions of Invisalign® have been developed to improve the predictability and the range of malocclusions treated. We can find these different versions: (5)

- Invisalign® G3 (2010-2011) associated with optimized SmartForce attachments for rotation and power ridges for lingual root torque
- Invisalign® G4 (2011) aimed to treat anterior open bites with incisors extrusion (optimized attachments) and control mesio-distal root tip
- Invisalign® G4E (2013) corresponding to the SmartTrack material improving the control of tooth movements

- Invisalign® G5 (2014) designed to correct deep bite malocclusions
- Invisalign® G6 (2015) provide maximum anchorage in cases of first premolar extraction.
- Invisalign® G7 (2016) increases treatment predictability and 1-week aligners are newly designed.
- Invisalign® Teen (2017) is a new generation aimed to correct Class II malocclusion with mandibular advancement. This version overcomes the influence of growth on the treatment.
- Invisalign® G+ (2018) enhances the features of G6 and G7
- Invisalign® Go (2018) is a Chairside Digital Platform for dentists.
- Invisalign® First (2018) is designed for phase I treatment.

The benefits of all these innovations were quantified in a study realized by Invisalign® over more than 100.000 cases treated with the technique. The results have shown a significant increase in the predictability of tooth movements from 30% in canine extrusion to more than 500% in upper incisor torque movements (5)

#### **D- Advantages**

The main advantages of this technique are: (1,2,4)

Customized aesthetic treatment: As the aligners are thin and transparent, created from a precise PVS impression, their presence is barely noticed, even at close distance (2)

Removable: Although the aligners have to be worn every day for a minimum 20-22h, they can be removed by the patient for eating and to perform oral hygiene techniques as well as

cleaning the aligners if needed. This is a considerable advantage for the patient. In 2012, a study has shown that mastication was more efficient in patients treated with Invisalign® compared to fixed orthodontics. (13) Later, other studies (14,15) reported that patients also show a better periodontal health thanks to the possibility to remove the aligner in order to brush teeth and use floss.

Comfortable: The absence of metallic brackets and wires reduces the incidence of mouth irritations in those patients. (2) Studies have shown that Invisalign® patients report less pain, oral symptoms and negative effects on their quality of life during the first weeks of treatment compared to fixed orthodontics patients. (15,16)

In the articles reviewed, other advantages are mentioned such as lower allergic responses, lower abrasion on occlusal surfaces due to parafunctional habits or shorter appointments. (1,2) Moreover, the ability to present the expected final result to patients, thanks to the Clincheck, is an important advantage that facilitates the dentist-patient relationship.

### **E- Disadvantages and Limitations**

The two main disadvantages of the Invisalign® technique, according to authors, are:

Patient's compliance: As the appliances are removable, patient's compliance has the utmost importance for the treatment to be successful. It represents a disadvantage at the level of the clinician. (2)

Lack of operator control: In fact, once the aligners have been fabricated, no modifications to the treatment plan can be made unless the clinician requires the fabrication of new aligners (1,2,4)

The other limitations are more related to tooth movements. A study reported that, in treatment with Invisalign®, the intrusion of posterior teeth (0.25-0.5 mm) is often noticed and have to be corrected during the retention period, at the end of the treatment. (17)

Moreover, this technique is limited to tooth movements of pure dental origin. (2)

Finally, this technique requires fully erupted teeth for appropriate retention and all needed restorative work should be performed prior to PVS impressions for Invisalign®. (2)

## **OBJECTIVES**

The objectives of this work are:

1. Research the actual protocols and guidelines regarding orthodontic treatment with Invisalign®.
2. Determine which type of tooth movement are more predictable with the Invisalign® system.
3. Study which types of malocclusions can be treated with Invisalign®
4. Determine the stability of treatment outcomes over time.

## **MATERIAL AND METHODS**

To realize this work, an electronic search of articles was realized amongst the following databases: PubMed, Medline complete, Cinahl with full text, Dentistry and Oral sciences with the key words “Invisalign”, “Clear aligners”, “Predictability of treatment results”, “Treatment outcome” and “Accuracy”.

Following this search, the articles were reviewed manually and selected based on the following criteria:

Inclusion criteria	Exclusion criteria
<ul style="list-style-type: none"> <li>- Studies on patients over 15 years</li> <li>- Treatment with Invisalign®</li> <li>- Full text available</li> <li>- Dated of 15 years or less</li> <li>- Languages: English, Spanish or French</li> </ul>	<ul style="list-style-type: none"> <li>- Studies on animals and growing patients.</li> <li>- Only abstract or summary available</li> <li>- Patients treated with surgery</li> <li>- Dated of more than 15 years</li> <li>- Case descriptions</li> </ul>

Finally, this work was conducted based on 38 articles including one meta-analysis, 5 systematic reviews, 2 randomized clinical trial (RCT), 16 prospective studies, 12 retrospective studies, 1 pilot study and 1 case-series.



## **DISCUSSION OF RESULTS :**

The different articles reviewed for this work are summarized in the following table:

<b>AUTHORS, YEAR STUDY DESIGN</b>	<b>PARTICIPANTS</b>	<b>OUTCOME ASSESSED</b>	<b>MAIN RESULTS</b>
<b>Simon and al 2014 (7)</b>  Retrospective	30	Accuracy of molar distalization, premolar de-rotation and incisor torque	- Overall accuracy: 59% - Premolar de-rotation should be <15° with 1.5° staging maximum. - Mean accuracies: PM de-rotation: 40% Molar distalization > 1.5 mm : 87% Incisor torque: 42%
<b>Kravitz and al 2009 (9)</b>  Prospective	37	Accuracy of tooth movements	- Mean accuracy: 41% - Highest accuracy: lingual constriction (47.1%) - Lowest accuracy: Extrusion (29.6%) - Difficult rotation of canines, especially > 15°
<b>Houle and al 2017 (10)</b>  Retrospective	64	Accuracy of transverse changes	- Mean accuracy of expansion: Mx: 72.8% Mn: 87.7% - Clincheck overestimates bodily movement, higher tipping.
<b>Shalish and al 2012 (13)</b>  Prospective	68 21 Invisalign® 19 Lingual appliance 28 Buccal appliance	Patient's recovery after insertion	- Invisalign® group presents lower levels of oral symptoms and dysfunctions - Higher level of pain reported in the first days with aligners
<b>Kharkanechi and al (14) 2013</b>  Prospective	42 22 fixed appliances 20 aligners	Periodontal health over 1 year of active treatment	Treatment with fixed appliances are associated with reduced periodontal status and higher levels of periodontopathic bacteria compared with aligners.
<b>Lu and al 2018 (15)</b>  Meta-analysis	7 articles 368 patients	Comparison and assessment of periodontal status with Invisalign® and fixed appliances	The Invisalign® group presented significantly lower sulcus bleeding and plaque indexes at 1, 3 and 6 months.

<b>Miller and al (16)</b> <b>2007</b> Prospective	60 33 aligners 27 fixed appliances	Impacts of treatment during the first week	Lower levels of pain and negative effects on their quality of life with Invisalign®.
<b>Rossini and al (17)</b> <b>2015</b>  Systematic review	11 articles	Assessment of Invisalign® efficacy	- Mean intrusion: 0.72 mm - Extrusion is the least accurate movement (30%) - Aligners are able to level arches and control anterior intrusion
<b>Buschang and al (18)</b> <b>2014</b>  Prospective	27	Accuracy of occlusion at the end of the treatment	Final Clincheck does not reflect accurately patient's occlusion at the end of treatment
<b>Gu and al (19)</b> <b>2017</b>  Retrospective	96	Comparison between Invisalign® and fixed appliances	- 5.7 months shorter treatment time with Invisalign® - Both techniques can treat mild to moderate cases - Fixed appliances produce greater movements
<b>Galan-Lopez and al (20)</b> <b>2019</b>  Systematic review	15 articles	Assessment of Invisalign® accuracy and efficiency	-Tooth rotations and vertical displacement are challenging - IPR is recommended in canine rotation - In cases of crowding > 6mm, proclination and protrusion of incisors occur - Treatment results are less accurate than with fixed appliances.
<b>Barbagello and al (2008) (21)</b> Prospective	27 9 Invisalign® 9 light forces 9 heavy forces	Effects on premolar cementum	Aligners and light orthodontic forces have similar effects on root cementum.
<b>Drake and al (24)</b> <b>2012</b>  Prospective	50 15 weekly aligner change 37 biweekly aligner change	Assessment of orthodontic tooth movement (OTM)	- More OTM is observed during the first week (4.4 times more) - Mean accuracy: 55%
<b>Chisari and al (25)</b> <b>2014</b>  Prospective	30	Variables that influence tooth movement	- Mean accuracy: 57% - Tooth movement occurs mostly during the first week - Age and sex affect tooth movement

<b>Papadimitriou and al (26) 2018</b> Systematic review	22 articles	Assessment of Invisalign® clinical effectiveness	<ul style="list-style-type: none"> <li>- Invisalign® is a good alternative to fixed orthodontics in mild to moderate cases without extractions.</li> <li>- Predictable movements: tooth leveling, tipping and de-rotation (except cuspids and premolars)</li> <li>- Low accuracy movements: vertical movements, space closure after extraction and bodily movements in arch expansion.</li> </ul>
<b>Kravitz and al (27) 2008</b> Prospective	31	Canine rotation with IPR or attachments	<ul style="list-style-type: none"> <li>- Mean accuracy: 35.8%</li> <li>- Predictability of canine rotation is not significantly improved with IPR or attachments.</li> </ul>
<b>Levrini and al (28) 2015</b> Prospective	77 32 Invisalign® 35 Fixed appliances 10 Control group	Assessment of periodontal health with Invisalign®	<ul style="list-style-type: none"> <li>- Superior periodontal health in patients treated with Invisalign</li> <li>- Lower total mass of total biofilm in the Invisalign® group</li> </ul>
<b>Rossini and al 2015 (29)</b> Systematic review	5 articles	Assessment of periodontal health with Invisalign®	Significant improvement of periodontal health indexes in patients treated with Invisalign®
<b>Moshiri and al 2013 (30)</b> Case series	4 cases	Impact of oral hygiene in aligner therapy	Poor oral hygiene with aligners can lead to decalcifications or caries development.
<b>Gay and al (31) 2017</b> Prospective	71	Assessment of prevalence and severity of root resorption with Invisalign®	<ul style="list-style-type: none"> <li>- Invisalign® treatment could lead to root resorption</li> <li>- Similar incidence compared to light forces</li> <li>- Mean percentage &lt;10% of original length of the root</li> </ul>
<b>Aldeeri and al 2018 (32)</b> Systematic review	2 articles	Association of clear aligners and root resorption	There is a low risk of root resorption with clear aligners
<b>Eissa and al (33) 2018</b> Pilot study	33 11 Invisalign® 11 damon brackets 11 regular brackets	Assessment of root length	<ul style="list-style-type: none"> <li>- Significant root resorption in all groups</li> <li>- Less root resorption occurs with Invisalign®</li> </ul>
<b>Li and al (34) 2020</b> Retrospective	70 35 Invisalign® 35 Fixed appliances	Prevalence and severity of root resorption	The Invisalign® group presented significantly lower prevalence and severity of root resorption

<b>Grünheid and al 2017 (35)</b> Retrospective	30 Non extraction cases	Accuracy of tooth movements with Invisalign®	- Non clinically significant discrepancies between predictions and outcomes except for Mx 2 <sup>nd</sup> molar - Arch expansion and rotation of rounded teeth are incomplete
<b>Charalampakis and al (36) 2018</b> Retrospective	20	Accuracy of tooth movements with Invisalign®	- Horizontal movements of incisors are accurate - Least accurate movements are canine rotation and intrusion of incisors.
<b>Haouili and al 2020 (37)</b> Prospective	38	Accuracy of tooth movements with Invisalign®	- Overall accuracy: 50% - Mean accuracies: Buccolingual tip: 56% Rotation: 46% Intrusion: 45% Extrusion: 46% - Mesial rotation is more predictable than distal rotation
<b>Krieger and al 2012 (38)</b> Retrospective	50	Accuracy of Invisalign® on anterior teeth	- Invisalign® can correct moderate to severe anterior crowding - Outcomes are consistent with predictions except for overbite - Vertical tooth movements are challenging with Invisalign®
<b>Kassas and al 2013 (39)</b> Retrospective	31	Accuracy of Invisalign® treatment	- Significant increase of MGS scores for alignment and buccolingual inclination categories - MGS scores for occlusal contacts and occlusal relationships decreased during treatment.
<b>Castroflorio and al (40) 2013</b> Prospective	6	Accuracy of torque control on upper incisors	For a torque correction of 10°, results obtained with Invisalign® are predictable
<b>Grünheid and al 2016 (41)</b> Retrospective	60 30 Invisalign® 30 fixed appliances	Assessment of buccolingual tipping of mandibular canines	Invisalign® is able to increase intercanine width without increasing canine tipping compared to braces.

<b>Pavoni and al 2011 (42)</b> Prospective	40 20 Invisalign® 20 self-ligating brackets	Assessment of dentoalveolar effects	- Same treatment time for both techniques in class I mild crowding - Invisalign® can tip crowns easily but not roots
<b>Ravera and al 2016 (43)</b> Retrospective	20	Accuracy of molar distalization	- 1 <sup>st</sup> Mx molar: distalization of 2.25mm - 2 <sup>nd</sup> Mx molar: distalization of 2.52 mm - Facial height remains unchanged
<b>Solano-Mendoza and al (44) 2017</b> Prospective	116	Accuracy of expansion with Invisalign®	Expansion planned with Clincheck is not predictable
<b>Zhou and al 2020 (45)</b> Prospective	20	Accuracy of arch expansion with Invisalign®	- Significant discrepancies between expansion predictions and results - Predictability of expansion decreases from anterior to posterior region - Mean accuracy of 1 <sup>st</sup> Mx molar bodily movement: 36.35%
<b>Khosravi and al 2016 (46)</b> Retrospective	120 68 normal overbite 40 deep bite 12 open bite	Treatment of overbite with Invisalign®	- Normal overbite is maintained - Deep bite and Open bite are improved of 1.5 mm in average through changes in the position of incisors
<b>Li and al (20) 2015</b> RCT	152 76 Invisalign® 76 fixed appliances	Treatment outcomes in class I with extraction	- Longer treatment time for Invisalign® - Worse performance of Invisalign® in occlusal contacts and buccolingual inclination - Both types of treatment were equally successful
<b>Kuncio and al 2007 (47)</b> Retrospective	22 11 Invisalign® 11 fixed appliances	Stability of treatment outcomes post retention	- More relapses with Invisalign® compared to fixed appliances 3 years after. - Worsening of total and mandibular alignment in both groups - Worsening of maxillary alignment for Invisalign®

<b>Preston (48) 2017</b>  RCT	44 22 Invisalign® 22 braces	Stability of occlusal changes post retention	Similar settling of results in both groups after 6 months of retention
---	-----------------------------------	--	--

### **A- Treatment duration and biomechanics**

In the marketing approach by the Align Technology company, the Invisalign® treatment is presented as shorter in comparison with treatment with conventional fixed orthodontics.

Some studies have been conducted on the subject in order to verify this information.

On one hand, a study conducted on 300 patients compared treatment time between Invisalign® patients and patients treated with fixed orthodontics. They demonstrated that, in the case of light to moderate malocclusions without extractions, the treatment with aligners is 5.5 months shorter in average compared with the other group. (18) This result was confirmed later by a study conducted later where they found a significant reduction of treatment duration of 5.7 months in average with aligners. (19)

However, this last study also showed that, in cases with extractions, the treatment with Invisalign® was longer than the conventional one. (19) In addition, a recent randomized clinical trial evaluated the treatment of class I malocclusion with extraction and aligners or fixed orthodontics. The result was an average treatment duration of 31.5 months for Invisalign® against 22 months for conventional treatment. (20)

Based on these informations, we can conclude that in cases without extractions the treatment with aligners is in fact shorter. However, the complexity of the case has a large influence on the treatment duration and cases requiring extractions might be treated more

efficiently with conventional orthodontics than Invisalign®. It also has to be noted that there is a delay of up to 2 months between the virtual treatment planning and the application of the first aligner with this technique which increases total treatment duration. (4)

Another interesting aspect of the Invisalign® treatment evaluated in the literature is the biomechanics of the system and the change of aligners.

There are very few studies about the amount of forces delivered by the aligners. Only one study published in 2008, conducted on 8 patients evaluated the forces delivered by the aligners on the first maxillary premolar for a vestibular movement of 0.5 mm. They measured an average intensity of 1.12 N with a maximum of 5.12 N at the placement of the aligner in mouth. (21) Another study demonstrated that the forces delivered by the aligners are mainly located at the occlusal level. (22)

According to Bouchez, the aligners deliver light intermittent forces with a maximum intensity at placement that decreases rapidly. He also mentioned that the forces are exclusively applied on the teeth that require movement while the others are used as anchorage which reduces dental and periodontal pain for the patient. (23)

In addition, more recent studies showed that there are 4.4 times more tooth movement during the first week with the aligner. (24,25). This finding, added to the recent development of aligners that could be changed weekly instead of every two weeks by Align Technology, led the authors to consider the influence of the rhythm of aligner change on the treatment.

A randomized clinical trial, conducted by Bollen and al., demonstrated that with a biweekly aligner change patients are more likely to complete treatment compared to weekly change.

(26)

Furthermore, authors suggest that a change rate of two weeks is the more appropriate in most cases as it allows rest periods for the tooth to recover from the forces applied by the aligner (24) which also stabilizes the tooth movement (25). Therefore, a weekly change should be individualized based on considerations such as the case complexity.

### **B- Treatment accuracy**

Several studies have been conducted over the years to assess the accuracy of the treatment with Invisalign®.

In 2008, Kravitz and al. assessed the displacement of canines with aligners. They reported an accuracy of 35.8%. (27) Drake and al found that 55% of the movement prescribed were obtained. (24). Later, Chisari and al (25) and Simon and al (7) revealed mean accuracies of 57% and 59.3% respectively. Most recently, Houle and al (10) obtained an accuracy of 72.8% in the maxilla and 87.7% in the mandible regarding transverse expansion.

It has to be noted that these different studies were focused on different types of movements and different types of tooth and they do not all account for the different improvement of the technique during the past years. Moreover, the most recent studies revealed no clinically significant difference between the predicted results and the ones obtained (10).



As presented in these studies, the accuracy of the treatment with Invisalign® depends on the type of movement considered as well as the type of tooth considered therefore, we will assess these results more precisely later in this work.

### **C- Invisalign® and periodontal health**

In the literature, several authors investigated the relationship between the treatment with Invisalign® and the periodontal health of the patients.

In 2013, a one-year study demonstrated that patients treated with Invisalign® presented an increased periodontal status and a reduced amount of periodontopathic bacteria compared to patients treated with fixed appliances. (14)

In 2015, Levini and al compared the periodontal health of three groups (control group, Invisalign® and fixed appliances). The results showed that the Invisalign® patients revealed a significantly better periodontal health including plaque and bleeding point indexes and probing depth as well as an absence of periodontal bacteria. (28)

The same year, Rossini and al conducted a systematic review of 5 articles to evaluate the periodontal health of patients treated with aligners. Although only 5 articles were included in this review, their conclusion confirmed earlier results where aligners patients presented improved periodontal indices in comparison with fixed appliances patients. (29)

More recently, a meta-analysis of 7 articles including 368 patients in total, demonstrated a significant reduced plaque index and sulcus bleeding index at 1,3 and 6 months of treatment in the Invisalign® group. (15)

The literature widely agrees on the fact that aligners provide an improved periodontal health to patients compared with conventional treatment thus making it the treatment of choice for patients with periodontal problems. (3)

However, aligners can constitute a favorable environment for bacterial accumulation leading to gingival inflammation or tooth demineralization if proper hygiene is not maintained. (36)

One article suggests that the aligners should be cleaned with a toothbrush and soaked in warm water with dissolving tablets for 5 minutes (2)

#### **D- Invisalign® and Root Resorption**

Several of the reviewed studies analyzed the relationship between Invisalign® and the alveolar root resorption.

In 2017, one study demonstrated that the appearance of root resorption with Invisalign® was similar to the ones observed in patients treated with light forces fixed orthodontics with an average of less than 10% of the original length of the root. These results were later confirmed by a systematic review of 2 articles. (32)

Two other studies revealed that the prevalence and severity of alveolar root resorption was significantly lower in the Invisalign® group (56.3%) compared to fixed appliances (82.11%).

(33,34)

We can conclude that the treatment with aligners is less subject to the appearance of root resorption, probably explained by the removable character of the appliance.

Since its development, the Invisalign® system has become a very popular treatment option among clinicians and patients. Clear advantages of this technique are the higher aesthetics and comfort compared with fixed orthodontics. In addition, as clear aligners are removable, they allow patients to have a better oral hygiene leading to higher periodontal health status. However, being removable is also a limitation from the clinician point of view since patient's compliance is required for a successful treatment.

The marketing strategy of the Align company promotes the idea that treatment of malocclusions with Invisalign® is shorter than conventional fixed orthodontics. Based on the studies reviewed, we can say that indeed, treatment with clear aligners is 5.7 months shorter in simple malocclusions (i.e crowding) treated without extractions (19). However, in class I malocclusions treated with premolar extraction, treatment time has been reported to be significantly longer with Invisalign® than braces (20,26). Therefore, this statement cannot be generalized.

Treatment duration is directly linked to the complexity of the case treated and its requirements (i.e degree or amount of tooth movements, extractions). If we consider cases of mild to moderate severity without extractions, treatment with clear aligners is shorter.

The most recent study considered in this work reported an average predictability of 50% for treatment with Invisalign® (37), significant increase from the 41% reported in 2009 (9). However, it has to be considered that the Clincheck does not provide a precise prediction of the tooth position at the end of treatment. In fact, the Clincheck only provides a « graphic depiction of force systems » and some tooth movements are subject to over engineering. This means that the percentages of accuracy reported, based on the clincheck predictions are not equal to the percentage of clinical efficacy of the treatment. (37) In fact, most discrepancies are not clinically significant thus they do not indicate unsatisfactory treatment results on a clinical level. (35)

## II. Predictability of tooth movements with Invisalign®

### A- Intrusion

The intrusion is the action of partially introducing the tooth into the bone.

Regarding intrusion, the first pertinent article was published in 2009 by Kravitz and al where they conducted a prospective study to evaluate the efficacy of the Invisalign® system. (9) Their study included 37 patients and analyzed anterior teeth movements. Their results indicated that the precision of anterior teeth's intrusion was 41.3% with the highest predictability for mandibular central incisors (46,6%) and the lowest for maxillary lateral incisors (32.5%). They also reported that aligners are able to produce an average true intrusion of 0.72 mm per arch.

In 2017, Grünheid and al revealed that the intrusion of mandibular incisors was one of the movements presenting the highest discrepancy between expected and obtained tooth position: the anterior teeth appeared in a more occlusal position than expected. However, they did not calculate the percentage of accuracy. (35) In 2018, Charalampakis and al came to the same conclusion. (36)

In 2020, Haouili and al published the results of a prospective study on 38 patients aimed to provide actualized information on the accuracy of Invisalign®. Their study demonstrated the highest accuracy in the intrusion of mandibular first premolar (63.1%) and the lowest for intrusion of maxillary (33.4%) and mandibular (33.9%) central incisors. They also obtained a relatively high predictability in the intrusion of mandibular (51.3%) and maxillary (53.3%) canine, mandibular second premolar (56.1%) and mandibular second molar (51.3%). (37)

Based on this literature, we can conclude that tooth intrusion is a challenging movement to produce with Invisalign®, especially on incisors. However, a relatively accurate intrusion can be obtained on mandibular posterior teeth.

## **B- Extrusion**

Extrusion is the displacement of a tooth in a coronal direction along its long axis.

In 2009, Kravitz and al reported that tooth extrusion with Invisalign® was the least accurate movement with an average predictability of 29.6%, lowest for maxillary (18%) and mandibular (25%) incisors considering an average extrusion of 0.56 mm. (9)

In 2012, Krieger and al concluded in their study that tooth movements in the vertical plane with Invisalign® (which includes both intrusion and extrusion) are the most difficult ones to achieve as they presented the largest deviations. (38) A year later, the study published by Kassas and al reported similar results (39)

In 2020, Haouili and al obtained a mean accuracy of 45.9% for tooth extrusion, the highest accuracy being the extrusion of maxillary central incisor (56.4%) followed by maxillary lateral incisors (53.7%) and mandibular second premolar (52.5%). The least predictable tooth extrusions were the mandibular second molar (37.1%) followed by the maxillary first molar (37.6%) and second premolar (38.3%). (37)

These results show an improvement of the performances of Invisalign® over the last years regarding tooth extrusion.

### **C- Rotation**

Tooth rotation is defined as the intra-alveolar movement of a tooth in a mesial or distal direction around its long axis.

In the literature, Kravitz and al analyzed the effects of interventions such as the use of attachments or IPR for canine rotation with Invisalign®. Their prospective study included 31 patients divided in 3 groups: one group used attachments, another was subject to IPR and the last one did not receive any intervention. Considering the three groups, a mean accuracy of 35.8% was obtained with a higher accuracy (43.1%) in the group with interproximal reduction (IPR) and the lowest accuracy (30.3%) in the group that did not receive any intervention. (27)

In their study of 2009, Kravitz and al described a highest predictability for the rotation of maxillary central incisors (55%) and mandibular lateral incisors (52%). The lowest predictability was described for the rotation of mandibular (29%) and maxillary (32%) canines. They also indicated that the predictability of canine rotation was significantly decreased for movements greater than 15°. (9)

In 2014, Simon and al conducted a retrospective study on 30 patients where they analyzed premolar de-rotation. They demonstrated a mean accuracy around 40% for this movement with a reduced accuracy for overall de-rotations greater than 15° (23.6%). Their results also prove that a prescription below 1.5° of rotation per aligner (staging) increases the predictability of the rotation: 41.8% against 23.2% for a staging > 1.5°. (7)

Later, two retrospective studies revealed that the rotation of canines and premolars with Invisalign® was one of the least predictable movements. (35,36)

In 2020, the prospective study of Haouili and al evaluated the rotations of all teeth with Invisalign®, considering the direction of the movement (mesial or distal) as well. Their results showed a mean accuracy of 45.5% with the lowest accuracy for mandibular second molars (33.6%). The average predictability of canine and premolar rotation was 46%. They also demonstrated that mesial rotation (52%) was significantly more predictable than distal rotation (37%). (37)

The results of these different studies suggest that tooth rotation with aligners are challenging movements, especially for cylindrical teeth such as canine or premolars.

Furthermore, rotations with Invisalign® should be limited below 15° and a staging < 1.5°.

#### **D- Torque**

Torque is defined as a bucco-lingual movement of the tooth around its center point. The crown and the root of the tooth move in opposite directions.

In 2009, Kravitz and al reported that the lingual torque produced by Invisalign® is significantly more accurate (53%) than the buccal torque (38%), especially for maxillary incisors. (9)

In 2013, Kassas and al conducted a retrospective study on 31 patients where they evaluated that an average torque of 8° could be corrected with Invisalign®. The incisal torque had a



predictability of 67%, the anterior one 62% and the posterior torque 42%. They also reported an increased score of the torque with Invisalign® based on the Model Grading System (MGS) of the American Board of Orthodontics. (39)

That same year, a prospective study conducted on 6 patients demonstrated a mean variation of 10.4° of torque with Invisalign®. (40)

In 2014, Simon and al evaluated the production of upper central incisor torque with Invisalign® using either horizontal ellipsoid attachment or Power ridges with a mean accuracy of 42%. They found no statistical difference between both groups which presented a mean accuracy of 49.1% and 51.5% respectively. (7)

In 2017, Grünheid and al analyzed the discrepancies between the expected and achieved torque movements with Invisalign® in 30 patients. Although they did not calculate percentages, the highest discrepancies were seen in the maxillary second molar ( $-2.13 \pm 4.19^\circ$ ) and central incisor ( $1.75 \pm 2.86^\circ$ ). Other significant discrepancies in torque movement were observed in maxillary second premolar ( $-1.18 \pm 3.27$ ) and first molar ( $-1.45 \pm 3.37$ ) as well as mandibular canine ( $-1.60 \pm 2.04$ ) and second molar ( $-1.09 \pm 2.13$ ). However statistically significant, only the torque discrepancy in maxillary second molar (above 2°) has been demonstrated as clinically significant. (35) In addition, they reported that the discrepancy found in the torque of maxillary central incisor was consistent with the observation made by other authors on a higher tipping of those teeth with Invisalign® compared to bodily movement. (24, 41)

These results suggest that Invisalign® system cannot perform torque movements above 10° and the least accurate torque movements appear on the maxillary central incisor and second molar, the last one being clinically significant.

### **E- Tipping**

Tipping is defined as a modification of the long axis of the tooth in the mesiodistal or buccolingual direction.

In 2009, Kravitz and al reported a mean predictability of 40.5% for anterior mesiodistal tipping with Invisalign®. The highest accuracy was for mandibular (49%) and maxillary (43.1%) lateral incisors and the lowest one for mandibular canines (26.9%) followed by maxillary canine (35%) and central incisors (39%). Their results also stated that buccolingual tipping of anterior teeth had a mean predictability of 44.7% and lingual tipping was more accurate (53%) than buccal tipping (38%). (9)

In 2011, Pavoni and al concluded that the Invisalign® system has the ability to tip the crown without moving the root of the tooth. (42) In 2013, Kassas and al showed a significant amelioration of the MGS score of buccolingual tipping, particularly in the posterior sector. (39)

In 2017, Grünheid and al evaluated in their study the discrepancies between expected and achieved tipping. Although they did not establish percentages, the only statistically significant discrepancies are in the tipping of the mandibular second molar ( $1.07 \pm 3.06^\circ$ ) and

the maxillary first molar ( $-1.06 \pm 1.40^\circ$ ). Mandibular second molars appear more distally tipped whereas maxillary first molars are more mesially tipped. (35)

In 2020, Haouili and al also studied the movement of tipping with Invisalign® in both mesiodistal and buccolingual directions. Of all the movements evaluated in their study, buccolingual tipping was the most predictable one with a mean accuracy of 56% and more precisely the buccal tipping of the lateral maxillary incisor (70%). The lowest accuracy was shown by the buccal tipping of the second molar (35% in average). Comparing the results of the tipping between the arches, we can see that both arches present similar results in the buccal (57.6%), distal (53.4%) and lingual (54.8%) tipping however in the mesial tipping, the maxillary arch presents a slightly better accuracy (52.7%) than the mandibular one (48.8%). (37)

Based on the literature we can affirm that the tipping movement realized with Invisalign® is one of the most predictable.

#### **F- Molar distalization**

Molar distalization is the distal bodily movement of a molar.

In 2014, Simon and al reported that molar distalization was the most predictable movement performed with Invisalign® (87% of mean accuracy). They also evaluated the influence of attachments on this movement and found no statistical difference between the group of patients with attachments (88.4%) and the control group (86.9%) for an average movement of 2.7 mm ( $> 1.5$  mm) and a staging of 0.2 mm. (7)

In 2016, Ravera and al implemented a multicentered retrospective study on 20 adult patients for the cephalometric evaluation of class II malocclusions treated with Invisalign®. Their results have shown that it is possible to realize a distal displacement of the first and second maxillary molars of 2.25 mm and 2.52 mm respectively without significant tipping or vertical movement. In addition, the treatment of class II malocclusions with Invisalign® did not modify the facial height of the patient. (43)

These articles suggest that molar distalization can be performed with a high accuracy using Invisalign® for prescribed movements greater than 1.5 mm.

### **G- Arch expansion**

Arch expansion is a method used to increase the space in the arch, allowing to solve crowding in many cases.

Some studies have analyzed arch expansion produced in patients using Invisalign®.

In 2009, Kravitz and al reported an average predictability of 40.5% for expansion in an anteroposterior direction. In their analysis of 37 patients, the highest accuracy of expansion was recorded in the mandibular (50.8%) and maxillary (49%) lateral incisors followed by the maxillary central incisor (48.5%). The lowest accuracy was recorded for the mandibular central incisor (27.4%) and canine (29%). (9)

Few years later, Pavoni and al studied the transversal changes with Invisalign® in 40 patients divided in two equal groups: one treated with Invisalign® and the other one with self-

ligating brackets. The Invisalign® group has shown a significant increase at the fossa points in intermolar (0.5 mm) and second interpremolar (0.45 mm) widths. However, no significant increase in intercanine width was reported. It should also be noted that, in this group, corrections were achieved through IPR without significant increase of the arch width or length. (42)

In 2017, Houle and al (10) conducted a retrospective study to evaluate the predictability of transverse changes with Invisalign® on 64 adult patients. They measured maxillary and mandibular arch widths at the gingival margin and cusp tips of canines, premolars and first molars at the end of the treatment (outcomes). These measurements were compared with the final Clincheck predictions. For the maxilla, all measurements presented a statistically significant discrepancy between the Clincheck and treatment outcomes. The most predictable change was seen at the cusp tip of the canine (88.9%) and the least accurate one at the lingual gingival margin of the first molar (52.9%).

Regarding the lower arch, the measurements at the cusp tip did not show any significant discrepancy with an accuracy surrounding 100% in all teeth. However, all measurements at the gingival margin revealed a significant difference between the Clincheck and the outcome with an accuracy from 61.0% at the canine to 88.4% at the first premolar.

Overall, the transversal changes in the maxilla presented a predictability of 72.8%, higher at cusp tip (82.9%) than gingival margin (62.7%). The changes in the mandible revealed an overall predictability of 87.7%, worse at gingival margin (76.4%) than cup tip (98.9%). They also noted that, in the maxilla, the predictability of transverse changes was reduced in the posterior region compared to the anterior one. In addition, the molars show more tipping

than bodily movement during transversal changes with Invisalign®. These parameters should be taken into account while doing the Clincheck. (10)

The results obtained by Solano-Mendoza and al. also confirmed those results as they obtained significant discrepancies between in most outcome measurements compared to the final Clincheck. Their conclusion was that planned expansion with Invisalign® is not a predictable displacement. It should be noted that their prospective study was conducted using Ex 30' aligners which have been more recently replaced by the SmartForce material. (44)

That same year, Grünheid and al reported that maxillary posterior teeth presented a more lingual position with higher buccal crown torque than expected which suggests that the expansion of the maxillary arch could not be achieved completely through bodily movement. (35)

More recently, Zhou and al analyzed the expansion of the upper arch with Invisalign® on 20 Chinese adult patients. They compared the outcomes measured with those predicted at the level of the crowns of canine, both premolars and the first molar. They also assessed the amount of bodily expansion produced during expansion at the level of the first molar. Their results have shown a significant difference between the expected and achieved expansion in all the teeth considered. The mean accuracies reported are 79.5% at the canine, 76.1% at the first premolar, 73.3% at the second premolar and 68.3% at the first molar. (45)

The skeletal changes of the maxilla were assessed with Cone Beam Computed Tomography (CBCT) and it resulted that there were no significant changes in the basal bone width

whereas the buccal (0.87 mm) and lingual (0.75 mm) alveolar bone widths expanded significantly. (45)

At the level of the maxillary first molar, the authors assessed a bigger expansion at the level of the crown ( $1.06 \pm 0.51$  mm) compared to the root ( $0.29 \pm 0.36$  mm) with a significant  $2.07^\circ$  increase in the buccolingual inclination. In addition, they reported that the mean accuracy of this tooth's bodily movement was 36.35%. (45)

Based on the results presented, it seems that arch expansion is a displacement that can be realized with a high predictability using Invisalign®. However, the accuracy of the expansion decreases from anterior to posterior in the upper arch causing buccal tipping of the maxillary first molar rather than bodily movement. This must be taken into account by the clinician when planning the treatment with the Clincheck.

In summary, if we consider the different types of tooth movements performed with Invisalign®, it appears that the most accurate ones are molar distalization and buccolingual tipping.

Molar distalization with Invisalign® presents a mean predictability of 87% for a total displacement above 1.5 mm and a staging of 0.2 mm. This movement was realized without significant tipping or vertical tooth movement nor a modification of the anterior facial height in class II patients. (7, 43) However, in these studies, class II elastics were not used and there was no anterior teeth movement during the molar distalization to provide maximal

desmodontal anchorage. The influence of these factors on the predictability of molar distalization require further studies. (7)

With regard to buccolingual tipping, this result is not surprising if we consider that the primary flexion of the material occurs in a bucco-lingual direction and the buccal and lingual tooth surfaces provide the greater surface areas allowing the aligners to push the teeth more efficiently. In addition, an improvement in the accuracy of Invisalign® has been noted since 2009 (40.5% in 2009 against 56% in 2020) and can be attributed to the use of Power ridges and the SmartTrack material, more flexible. (9,37)

However, the aligners struggle in producing buccal tipping of the second molars. This result has been explained by a poor grip of the aligners around this short crown added to a reduced amount of forces applied in this area.

On the contrary, the least accurate tooth movements reported are tooth rotation and vertical displacements.

In fact, rotations of cylindrical teeth (i.e. canine and premolars) are especially challenging for Invisalign®. The use of IPR and attachments, however, increases the accuracy of this movement with aligners. (9) As the rotations present a low degree of accuracy and control, they should be limited below 15° using a staging of 1.5° maximum per aligner. Furthermore, the fact that mesial rotation (52%) is significantly more predictable than distal rotation (37%) should be taken into consideration by the clinicians. (7, 36, 37) An improvement of the accuracy of rotations in the last years (35.8% in 2009 - 45.5% in 2020) is however encouraging.



In the latest findings about vertical displacements, the use of attachments optimized for extrusion has improved the accuracy of lower incisors extrusion (37) which was previously described as the least accurate movement. (9) On the contrary, the G5 enhancements did not improve the accuracy of mandibular incisor intrusion, remaining a challenging movement for aligners. Kravitz and al reported that a true intrusion of 0.72 mm per arch could be achieved with this technique. (9, 35, 36, 37)

In order to obtain satisfying results for vertical tooth movements with Invisalign® the authors recommend either the planning of vertical overcorrection during the clin check, the use of additional supportive measures such as attachments or elastics or refinement at the end of the treatment. (38)

In the production of torque movements, the clear aligners are able to realize a torque movement below 10° (mean accuracy of 42%), especially accurate on maxillary central incisors with either attachments or power ridges. However, this movement have been described to be realized mainly through incisor tipping. (35, 39, 40)

In addition, the discrepancy (over 2°) of torque produced on the maxillary second molar, compared with predictions, is clinically significant. (35)

Arch expansion with Invisalign® presents a predictability decreasing from anterior (79.75%) to posterior (24.41%). These results could be explained by the differences of cortical bone thickness and root anatomy, the higher occlusal load as well as a higher resistance from the cheeks in the posterior region. (10, 45)

Moreover, the molars have shown an accuracy of bodily movement of 36.35% indicating that more tipping movement ( $2.07^\circ$ ) is produced by aligners to obtain arch expansion. In order to limit this undesired tipping and improve the accuracy of bodily movement, the authors recommend clinicians to preset an appropriate negative crown torque during Clincheck. To do so, clinicians should pay attention to the initial position of molars, especially their buccal inclination to prevent negative effects on the occlusion. (10, 45)

These studies also reported a negative correlation between the efficiency of bodily expansion and the total amount of expansion or the initial torque of the tooth.

On a clinical level, these findings suggest that, in order to avoid gingival recessions, arch expansion with aligners should be limited to 2-3 mm per quadrant with a reduced staging in cases requiring large expansions. (45)

### III. **Treatment with Invisalign®: other aspects**

#### A- **Malocclusions treated with Invisalign®**

##### Crowding

Krieger and al (38) conducted a retrospective study on 50 patients with frontal crowding treated with Invisalign®. They classified the cases using the Little's index of irregularity: the deviations from ideal position of the mesiodistal contact points from canine to canine in both arches (13 to 23 and 33 to 43) are measured in mm and summed. The result of this calculation categorizes the case into one of the following categories: perfect alignment (0 mm), minimal (1-3 mm), moderate (4-6 mm), severe (7-9 mm) or very severe ( $\geq 10$  mm) irregularity.

At the initial stage, the patients presented in majority moderate irregularities in the maxilla (52%) and moderate to severe irregularities in the mandible (34 % in both categories). At the end of the treatment, all patients revealed a perfect alignment (16% in the maxilla; 54% in the mandible) or minimal irregularity (80% in the maxilla – 46% in the mandible) except 2 patients (4%) that presented moderate irregularity in the maxilla. The mean irregularity measured after treatment is 1.57 mm ( $\pm 0.98$ ) in the maxilla and 0.82 mm ( $\pm 0.50$ ).

In the maxilla, the treatment with aligners was most commonly (48%) associated with IPR whereas, in the mandible, treatment was associated with IPR and protrusion of the incisors (40%). In addition, they demonstrated an equivalence between the outcomes achieved and the ones predicted revealing no clinical or significant discrepancy.

On the other hand, their results have shown a significant difference in terms of overbite with an average discrepancy of  $-0.71 \pm 0.87$  mm which lead them to conclude that Invisalign® have difficulties in producing tooth movements in the vertical plane. (38)

In another study, they reported a significant increase of the MGS score of tooth alignment with Invisalign®. (39)

These results indicate that anterior crowding, even severe can be treated successfully using aligners. However, the changes in overbite are harder to achieve accurately.

#### Deep bite and Open bite

In their systematic review on the efficacy of clear aligners, Rossini and al (17) suggested that the Invisalign® system could only be used to treat mild deep bites based on the analysis of an article reporting the difficulty of the system to properly intrude teeth (9). In addition, they concluded that the aligners are not recommended for cases of open bites as the extrusion is a difficult movement to produce accurately. (9)

More recently, authors suggested that clear aligners are more effective in bite closure compared to bite opening. (37)

In 2017, Khosravi and al (46) conducted a retrospective study on the management of overbite with Invisalign®. Their study included 120 patients divided in three groups: normal overbite (68 cases), deep bite (40 cases) and open bite (12 cases).

In the group of patients with normal overbite, their result have shown that the aligners maintained the overbite with minimal changes to the anterior and posterior vertical dimensions. The median change in overbite for this group was – 0.3 mm with minor proclination of the maxillary and mandibular incisors. Furthermore, there was a 0.7 mm increase in anterior facial height. (46)

In the group of patients with deep bite, the aligners achieved a reduction of the overbite with a median opening of 1.5 mm. This result was produced by intrusion of the maxillary incisors and protrusion of the mandibular ones. In addition, they observed an average extrusion of 0.5 mm in the first and second mandibular molars. (46)

In the group of patients with open bite, there was median 1.5 mm increase of the overbite mainly achieved by extrusion of the maxillary and mandibular incisors without significant modification of the posterior vertical dimension. (46)

In conclusion, their results indicate that Invisalign® was able to properly treat overbite, moderate cases of open bite and deep bite cases although the aligners did not completely resolve very severe cases. In addition, they pointed out that the cases considered in the study were not treated using the G5 technology which is aimed for deep bite treatment with Invisalign®. (46)

Space closure after extractions

Several studies have stated that clear aligners are not able to accurately produce vertical displacement of anterior teeth (especially extrusion) nor control root movement as it produces more tipping of the tooth. Based on these results, they suggested that Invisalign® was not to recommend in cases requiring space closure after extraction. (9, 38, 42)

However, Li and al (20) conducted a randomized control trial (RCT) on a total of 152 patients treated for class I malocclusions with premolar extractions. These patients were blindly and randomly divided into two groups of 76 patients treated with either Invisalign® or fixed orthodontics. They used categories and scores from the Objective Grading System (OGS) of the American board of Orthodontics (ABO) as a unit of measurement. The Invisalign® group has shown a significant improvement of the total OGS score between pre-treatment (T1: 54.97) and post-treatment (T2: 24.49). From the eight categories of the OGS, this group only had non-significant improvements in occlusal contacts and occlusal relations between T1 and T2. The clear aligners were able to significantly improve the OGS scores in interproximal contacts, overjet, marginal ridges, buccolingual inclinations, root angulation and alignment in the cases studied. (20)

From this RCT, the authors concluded that the Invisalign® system is able to successfully treat cases of class I malocclusions with extractions. The aligners can produce satisfying arch alignment by tooth de-rotation, arch leveling and appropriate root angulation. However, occlusal contacts are not significantly improved with this technique therefore, to obtain better results, they advocate the use of interarch elastics when ending the treatment.

Therefore, if we consider the malocclusions that can be successfully treated with Invisalign®, few studies bring insight and recommendations on the matter. Most authors agree on the fact that clear aligners are effective in tooth alignment thus treating crowding, even in severe cases. (38,39)

With regard to the correction of overbite, older studies suggested that Invisalign® was not fit to treat successfully these malocclusions. (17) However, more recent studies have proven otherwise. In fact, Invisalign® is able to correct moderate cases of open bite (median overbite increase of 1.5 mm) and moderate cases of overbite (median opening of 1.5 mm). For normal overbite cases, the aligners maintained the overbite while increasing the anterior facial height effectively (0.7 mm). (46)

The Invisalign® system has also been proven capable to produce satisfying space closure after premolar extraction in class I malocclusions. (20)

Some studies have been conducted with the aim to compare the treatment results obtained with Invisalign® and fixed orthodontics. (20, 42) The results show that, although clear aligners are able to successfully treat malocclusions, fixed appliances usually produce higher results in term of predictability and amount of tooth movements. The differences between both groups are however not always significant. Fixed orthodontics are mainly superior in terms of occlusal contacts and transversal movements. (20) Both Invisalign® and braces can displace teeth to a clinically acceptable position (47)

## **B- Stability of treatment outcomes**

In the literature reviewed, there is only one retrospective study that evaluated the stability of post-treatment outcomes with Invisalign®. It was conducted by Kuncio and al on 11 patients treated with Invisalign® compared with 11 patients treated with fixed orthodontics. Their objective was to evaluate and compare the stability of orthodontic treatment results after 3 years, including 1 year of retention in total (6 months of full-time retention followed by 6 months of nightly retention only) using OGS scores. (47)

The Invisalign® group only showed a significant decrease in the categories: maxillary anterior alignment, mandibular anterior alignment as well as total alignment between the end of the treatment (T1) and 3 years post-treatment (T2). On the other hand, although statistically non-significant, there was an improvement in the categories: occlusal contacts, interproximal contacts, overjet, occlusal relations and marginal ridges. Furthermore, they reported a non-significant worsening of the total OGS score in this group from – 39.45 at T1 to – 40.18 at T2. (47)

The results of this study suggest that treatment with clear aligners might lead to relapse, especially in the alignment of anterior teeth.

More recently, a randomized clinical trial was conducted on 44 subjects presenting class I malocclusions from which 22 treated with Invisalign®. They evaluated the changes in occlusion during and after 6 months of retention. They concluded that patients' posterior occlusion worsened with treatment and that the main occlusal improvement was obtained during the first month of retention although it remained lower than pre-treatment values



after 6 months of retention. In addition, no significant change was detected in marginal ridges and buccolingual inclination during the retention period. (48)

In summary, on the matter of the matter of stability of post-treatment outcomes, only one study was identified (47) indicating that after 3 years of retention, there were more relapses in patients treated with Invisalign® compared to fixed orthodontics. They explained that this difference was probably due to the characteristics of the new bone formed with either technique. (47) In fact, in order to stabilize a tooth movement, the tooth needs a rest period to recover from the exerted forces. (20) With clear aligners, new forces are applied every two weeks compared to an activation every 4-6 weeks for braces. This rate of biweekly changes, most commonly used amongst clinicians, might produce damage to bone and teeth by reducing time for repair process following undermining resorption which happens even under ideal forces. For these reasons, the authors postulated that the activation of orthodontic appliances should be spaced of no less that 3 weeks and that the 2 weeks interval used in Invisalign® treatment is too short which leads to poor bone formation and more relapses.

More recently, the Align company recently indicated that a weekly change of aligners could be made. However, for the same reasons, authors do not recommend a wide use of this weekly change but mainly as an individualized technique based on specific case's characteristics. (20)

Throughout this work, it should be noted that the comparison of the results obtained in the studies considered present some limitations. In fact, there is a large heterogeneity in the protocols, the presence of control groups and the sample size is often small. Few studies presenting a high level of evidence were identified therefore, these studies mostly present insight on the movements produced by Invisalign® and the system's limitations. All studies however evaluated adult patients who did not undergo any refinement or finishing phase.

According to authors, there are many variables that can influence dental movements: sex, age, tooth length, quality of the bone, systemic factors and the location of the center of resistance (24,25). The compliance is also an important factor that affects treatment success in this case. However, in most studies, these variables are not taken into consideration except for age and sex.

Moreover, very few of the studies evaluated the treatment outcomes of the clear aligners using the latest improvements developed by Align Technology company. Further investigation, including rigorous RCT with appropriate methodology and sample size are necessary to confirm the results presented in this work and evaluate the usefulness of the latest improvements of the technique. This future knowledge will help define clear treatment protocols with Invisalign®.

## **CONCLUSION**

1. There are different protocols regarding the malocclusions that can be treated with Invisalign® System, although according to the literature it is an effective technique with successful results for the treatment of all types of malocclusions. However, clinicians must have their own judgement and experience in order to make a decision.
2. Invisalign® aligners can produce all types of tooth movements with a variable predictability. The most predictable movement are molar distalization (> 1.5 mm) and buccolingual tipping (56% average accuracy). The least predictable ones are vertical movements and rotation of teeth with cylindric roots.
3. Invisalign® is able to successfully treat a wide range of purely dental malocclusions with an efficacy close to the one of fixed orthodontics.
4. The outcomes of treatment with Invisalign® present more relapses over time compared with fixed orthodontics.










## **RESPONSIBILITY**

This work was aimed to review the different outcomes and efficiency of the Invisalign® system in the production of tooth movements. Doing so, it includes itself in an economic and social sustainability. In fact, on a social level, this system improves patient's quality of life by providing them an aesthetic and removable alternative to conventional orthodontics. On an

economic level, this work evaluates the efficiency of this technique, related to eventual future higher costs of treatment for the patient in case of needed corrections.

## ANNEXES

Annex 1: Table presenting an overview of SmartForce attachments (12)

Feature		Movement	Available on	Visual
Buccal Power Ridge		Lingual root torque	Upper and lower incisors	
Buccal Power Ridge + Lingual Power Ridge		Lingual root torque and retraction	Upper incisors	
Optimized Rotation Attachment		Rotation	Upper and lower canines and premolars	
Optimized Extrusion Attachment		Extrusion	Upper and lower incisors and canines	
Multi tooth anterior extrusion		Extrusion	Upper incisors	
Optimized Root Control Attachment		Tipping	<ul style="list-style-type: none"> <li>Upper central and lateral incisors</li> <li>Upper and lower canines and premolars</li> </ul>	
Optimized Multi-plane Movement features		Extrusion ± crown tipping ± rotation	Upper lateral incisors	
Deep Bite Attachments		During anterior intrusion, Deep Bite Attachments are used for anchorage/retention or activated for premolar extrusion	Upper and lower premolars	
Pressure Areas		Anterior intrusion	Incisors and lower canines	
Precision Bite Ramps (are not SmartForce® features per se, but can be prescribed by the Provider, and are placed depending on compatibility with other features).		Disocclude the posterior teeth	Upper incisors	
Multi-Tooth Unit	Optimized Retraction Attachment	Canine retraction	Upper and lower canines	 <small>Note: variation in type of attachment, or variation of attachment placement can occur for short crowns.</small>
	Optimized Anchorage Attachment	Posterior anchorage	Upper and lower second premolars and molars	

## **BIBLIOGRAPHY**

1. Kumar K, Bhardwaj S, Garg V. Invisalign: A Transparent braces. *J Adv Med Dent Sci Res*. 2020;8(1):184–6.
2. Sahoo KC. Invisalign - Emperor's New Cloth. *Indian J Dent Sci* 2011;3
3. Aljabaa A. Clear aligner therapy—Narrative review. *J Int Oral Heal* 2020;12(7):1.
4. Muggiano F, Quaranta A. The Aesthetic Alternative in Orthodontics With Sequential Aligners: The Invisalign System. *WebmedCentral Orthod* [Internet]. 2013;4(10):1–6. Available from: [http://www.webmedcentral.com/article\\_view/4434%5Cn](http://www.webmedcentral.com/article_view/4434%5Cn)
5. Chazalon J-F. Invisalign®—15 years later, has it become a real alternative to fixed appliances? . *J Dentofac Anomalies Orthod* 2016;19(4):407.
6. Proffit W, Fields H, Sarver D. *Contemporary orthodontics*. 5th ed. Elsevier Mosby; 2012.
7. Simon M, Keilig L, Schwarze J, Jung BA, Bourauel C. Forces and moments generated by removable thermoplastic aligners: incisor torque, premolar derotation, and molar distalization. *Am J Orthod Dentofacial Orthop* 2014;145:728–36
8. Sterental R. The Technology Behind the Invisalign® System. 2006;46–50.
9. Kravitz ND, Kusnoto B, BeGole E, Obrez A, Agran B. How well does Invisalign® work? A prospective clinical study evaluating the efficacy of tooth movement with Invisalign®. *Am J Orthod Dentofacial Orthop* 2009;135:27–35.
10. Houle JP, Piedade L, Todescan R, Pinheiro FHSL. The predictability of transverse changes with Invisalign. *Angle Orthod* 2017;87(1):19–24.
11. Chan M, Chen C, Chang C, Lin J, Chang C, Roberts W. Introduction to Invisalign® Smart Technology : Attachments Design , and Recall-Checks. *J Digit Orthod* 2019;54(1):80–95.
12. Kotuby J. SmartForce Features and Optimized Attachments. *Dsod* [Internet]. 2018;2. Available from: <https://wp.dsodontist.com/2018/10/12/smartforce-features-smartforce-features-and-optimized-attachments/>
13. Shalish M, Cooper-Kazaz R, Ivgi I, Canetti L, Tsur B, Bachar E, *et al*. Adult patients' adjustability to orthodontic appliances. Part I: a comparison between Labial, Lingual, and Invisalign®. *Eur J Orthod* 2012;34:724-730.
14. Karkhanechi M, Chow D, Sipkin J, Sherman D, Boylan RJ, Norman RG, *et al*. Periodontal status of adult patients treated with fixed buccal appliances and removable aligners over one year of active orthodontic therapy. *Angle Orthod* 2013;83:146-151.

15. Lu H, Tang H, Zhou T, Kang N. Assessment of the periodontal health status in patients undergoing orthodontic treatment with fixed appliances and Invisalign system. *Med (United States)*. 2018;97(13).
16. Miller KB, McGorray SP, Womack R, Quintero JC, Perelmuter M, Gibson J, *et al*. A comparison of treatment impacts between Invisalign® aligner and fixed appliance therapy during the first week of treatment. *Am J Orthod Dentofacial Orthop* 2007;131:302 e301-309.
17. Rossini G, Parrini S, Castroflorio T, Deregibus A, Debernardi CL. Efficacy of clear aligners in controlling orthodontic tooth movement: a systematic review. *Angle Orthod* 2015;85:881-9.
18. Buschang PH, Shaw SG, Ross M, Crosby D, Campbell PM. Comparative time efficiency of aligner therapy and conventional edgewise braces. *Angle Orthod* 2014;84(3):391–6.
19. Gu J, Tang JS, Skulski B, Fields HW Jr, Beck FM, Firestone AR, *et al*. Evaluation of Invisalign treatment effectiveness and efficiency compared with conventional fixed appliances using the Peer assessment rating index. *Am J Orthod Dentofacial Orthop* 2017;151:259-66.
20. Galan-Lopez L, Barcia-Gonzalez J, Plasencia E. A systematic review of the accuracy and efficiency of dental movements with invisalign®. *Korean J Orthod* 2019;49(3):140–9.
21. Barbagallo LJ, Jones AS, Petocz P, Darendeliler MA. Physical properties of root cementum: Part 10. Comparison of the effects of invisible removable thermoplastic appliances with light and heavy orthodontic forces on premolar cementum. A microcomputed-tomography study. *Am J Orthod Dentofac Orthop* 2008;133(2):218–27.
22. Brezniak N. The clear plastic appliance: a biomechanical point of view. *Angle Orthod* 2008;78(2):381-2.
23. Bouchez R. *Les traitements orthodontiques invisalign®*. Paris: Quintessence international; 2009.
24. Drake CT, McGorray SP, Dolce C, Nair M, Wheeler TT. Orthodontic Tooth Movement with Clear Aligners. *ISRN Dent*. 2012;2012:1–7.
25. Chisari JR, McGorray SP, Nair M, Wheeler TT. Variables affecting orthodontic tooth movement with clear aligners. *Am J Orthod Dentofac Orthop* 2014;145(4 SUPPL.):S82–91.
26. Papadimitriou A, Mousoulea S, Gkantidis N, Kloukos D. Clinical effectiveness of Invisalign® orthodontic treatment: a systematic review. *Prog Orthod* 2018;19(1).

27. Kravitz ND, Kusnoto B, Agran B, Viana G. Influence of attachments and interproximal reduction on the accuracy of canine rotation with Invisalign. A prospective clinical study. *Angle Orthod* 2008;78:682-7.
28. Levrini L, Mangano A, Montanari P, Margherini S, Caprioglio A, Abbate GM. Periodontal health status in patients treated with the Invisalign® system and fixed orthodontic appliances: A 3 months clinical and microbiological evaluation. *Eur J Dent* 2015;9:404-10.
29. Rossini G, Parrini S, Castroflorio T, Deregibus A, Debernardi CL. Periodontal health during clear aligners treatment: A systematic review. *Eur J Orthod* 2015;37:539-43.
30. Moshiri M, Eckhart JE, Mcshane P, German DS. Consequences of poor oral hygiene during Clear Aligner Therapy. 2013;47:494–8.
31. Gay G, Ravera S, Castroflorio T, Garino F, Rossini G, Parrini S, et al. Root resorption during orthodontic treatment with Invisalign®: a radiometric study. *Prog Orthod* 2017;18(1):0–5.
32. Aldeeri A, Alhammad L, Alduham A, Ghassan W, Shafshak S, Fatani E. Association of orthodontic clear aligners with root resorption using three-dimension measurements: A systematic review. *J Contemp Dent Pract* 2018;19:1558-64
33. Eissa O, Carlyle T, El-Bialy T. Evaluation of root length following treatment with clear aligners and two different fixed orthodontic appliances: A pilot study. *J Orthod Sci* 2018;7:11.
34. Li Y, Deng S, Mei L, Li Z, Zhang X, Yang C, et al. Prevalence and severity of apical root resorption during orthodontic treatment with clear aligners and fixed appliances: a cone beam computed tomography study. *Prog Orthod* 2020;21(1):1–9.
35. Grünheid T, Loh C, Larson BE. How accurate is Invisalign in non-extraction cases? Are predicted tooth positions achieved? *Angle Orthod* 2017;87:809-15.
36. Charalampakis O, Iliadi A, Ueno H, Oliver DR, Kim KB. Accuracy of clear aligners: a retrospective study of patients who needed refinement. *Am J Orthod Dentofac Orthop* 2018;154:47-54.
37. Haouili N, Kravitz ND, Vaid NR, Ferguson DJ, Makki L. Has Invisalign improved? A prospective follow-up study on the efficacy of tooth movement with Invisalign. *Am J Orthod Dentofac Orthop* 2020;158(3):420–5.
38. Krieger E, Seiferth J, Marinello I, Jung BA, Wriedt S, Jacobs C, et al. Invisalign® treatment in the anterior region Were the predicted tooth movements achieved? *J Orofac Orthop* 2012;73(5):365–76.



39. Kassas W, Al-Jewair T, Preston CB, Tabbaa S. Assessment of invisalign treatment outcomes using the ABO model grading system. *J World Fed Orthod* 2013;2(2):e61–4.
40. Castroflorio T, Garino F, Lazzaro A, Debernardi C. Upper-incisor root control with Invisalign® appliances. *J Clin Orthod*. 2013;47(6):346-51.
41. Grünheid T, Gaalaas S, Hamdan H, Larson BE. Effect of clear aligner therapy on the buccolingual inclination of mandibular canines and the intercanine distance. *Angle Orthod*. 2016;86:10–16.
42. Pavoni C, Lione R, Lagana G, Cozza P. Self-ligating versus Invisalign®: analysis of dentoalveolar effects. *Ann Stomatol (Roma)* 2011; 2(1-2):23-7.
43. Ravera S, Castroflorio T, Garino F, Daher S, Cugliari G, Deregibus A. Maxillary molar distalization with aligners in adult patients: a multicenter retrospective study. *Prog Orthod* 2016;17:12.
44. Solano-Mendoza B, Sonnemberg B, Solano-Reina E, Iglesias-Linares A. How effective is the Invisalign® system in expansion movement with Ex30' aligners? *Clin Oral Investig*. 2017;21(5):1475–84.
45. Zhou N, Guo J. Efficiency of upper arch expansion with the Invisalign system. *Angle Orthod*. 2020;90(1):23–30.
46. Khosravi R, Cohanim B, Hujoel P, Daher S, Neal M, Liu W, et al. Management of overbite with the Invisalign appliance. *Am J Orthod Dentofac Orthop* 2017;151(4):691-699.e2.
47. Kuncio D, Maganzini A, Shelton C, Freeman K. Invisalign and traditional orthodontic treatment postretention outcomes compared using the american board of orthodontics objective grading system. *Angle Orthod*. 2007;77(5):864–9.
48. Preston KA. Treatment and Post-treatment Posterior Occlusal Changes in Invisalign® and Traditional Braces: A Randomized Controlled. 2017. Texas A & M University

## Review Article

### **Invisalign: A Transparent Braces**

Kislaya Kumar<sup>1</sup>, Shivani Bhardwaj<sup>2</sup>, Vishal Garg<sup>3</sup>

<sup>1</sup>Intern, Teerthanker Mahaveer Dental College and Research Centre, Uttar Pradesh, India

<sup>2</sup>Associate Dental Surgeon, Delhi, India

<sup>3</sup>Intern, Maulana azad Institute Of Dental Science, Delhi, India

#### **ABSTRACT:**

In current scenario not only adults have Influence of appearance in their professional and personal lives but also children have influence of the same. Appearance does count at any age. The face and the teeth have also come to play a part in his presentation to the outside world. To enhance this desire, attention has been given to correct malformations of teeth. In earlier times this was done by crude methods. And then evolved the concept of braces; fixed on the labial surfaces. Esthetic requirements repels adult patient from accepting traditional metallic look orthodontic appliance. Tooth colored brackets and wires gained popularity for a few decades but gradually declined owing to its own disadvantages. Orthodontists have given a new dimension by shifting from the labial to the lingual so as to give rise to the concept of Invisible braces or Lingual Orthodontics.

**Key words:** Clear Aligner, Esthetic Brackets, Invisalign, Lingual Orthodontics.

Received: 20 February 2018

Revised: 22 March 2018

Accepted: 24 March 2018

**Corresponding Author:** Dr. Kislaya Kumar, Intern, Teerthanker Mahaveer Dental College and Research Centre, Uttar Pradesh, India

**This article may be cited as:** Kumar K, Bhardwaj S, Garg V. Invisalign: A Transparent Braces. J Adv Med Dent Scie Res 2018;6(7):144-147.

#### **INTRODUCTION**

Now a days, not only adults have Influence of appearance in their professional and personal lives but also children have influence of the same. The maloccluded patients when think about the correction of their malaligned teeth, the first thing that come to their mind are braces and wires. However, according to the demands and needs of the patients, dentistry has been revolutionised. Dentists are concerned about the aesthetics and it is the major concerns among patients who take orthodontic treatment. To tackle the increasing aesthetic insist for an alternative to conventional braces, researchers have developed several solutions, such as composite braces, ceramic, lingual orthodontics and clear aligners. Clear aligners are the new age Aesthetic Orthodontic treatment. The demand of invisalign is increasing now a days due to its esthetic demand for those patients who are indisposed of wearing usual orthodontic appliances. Invisaligners are thin transparent removable unobserved plastic aligners for successful moving of teeth into their required position. In the late 1990s, Invisalign was introduced by Align Technology Inc. Impression are taken to allow the

construction of accurate cast which can be scanned to produce a virtual 3D model. This 3-D model can then be manipulated by the dentist and malocclusion is nearly treated using proprietary software. Then it can be used to produce a series of clear plastic aligners that steadily correct the malocclusion. The patient is instructed to wear such aligner for approximately 20 hours per day and is supposed to change approximately every two weeks. Each aligner will shift the teeth around 0.25 to 0.3mm.<sup>1</sup> In current years, the figure of teenager patients looking for orthodontic treatment has increased, so the aesthetics of the orthodontic appliance has become a topic of interest. The orthodontic patient today demands a beautiful smile at the end of treatment, but is equally concerned with appearance during the treatment. To meet this need for an attractive bracket, the manufacturers also started doing work by first decreasing the size and profile of metal brackets, they further introduce a tooth coloured ceramic brackets and 'Invisible' or 'lingual' brackets. Due to increasing esthetic demands of adolescent patients and clinical simplification in customising lingual

## Invisalign- Emperor's New Cloth

### Abstract

The long-awaited paradigm shift in orthodontics has arrived with the introduction of the Invisalign system. Adult patients seeking orthodontic treatment are increasingly motivated by esthetic considerations. The majority of these patients rejects wearing labial fixed appliances and are looking instead to more esthetic treatment options, including lingual orthodontics and Invisalign appliances. Since Align Technology introduced the Invisalign appliance in 1999 in an extensive public campaign, the appliance has gained tremendous attention from adult patients and dental professionals. The transparency of the Invisalign appliance enhances its esthetic appeal for those adult patients who are averse to wearing conventional labial fixed orthodontic appliances. Although guidelines about the types of malocclusions that this technique can treat exist, few clinical studies have assessed the effectiveness of the appliance and few recent studies have outlined some of the limitations associated with this technique that clinicians should recognize early before choosing treatment options.

### Key Words

Esthetic Appliances, Stereo Lithography, Clincheck

### Introduction:

Influence of appearance in personal and professional lives have led to a considerable interest among the adult population seeking orthodontic treatment in the last few years. Many esthetic appliance have come into market like ceramic brackets (and lingual appliance to cater the esthetic demands of adult population). One of the recent advancement being Clear Aligners. Clear plastic tooth moving appliance are excellent options for those adults who are reluctant to wear fixed appliance and whose chief complaint centers around mild to moderate alignment problems<sup>1</sup>.

### History:

Zia Chishti and Kelsey Wirth were graduate students in Stanford University's MBA program. Zia Chishti had finished adult treatment with traditional braces, and wore a clear plastic retainer. He noticed that if he did not wear his retainer for a few days, his teeth shifted slightly-but the plastic retainer soon moved his teeth back the desired position.

Together they started Align Technologies in April 1997 and with the help of a handful of forward thinking orthodontists, they applied 3-D computer imaging graphics and created the Invisalign method. This appliance was the first orthodontic treatment method to be

based solely on three-dimensional (3D) digital technology. Align Technologies received FDA clearance to market Invisalign in August 1998, and began commercial operations in July 1999.

### Over view (Fig-2):

- PVS impression, waxbite, radiographs, photos.
- CT scan of the impression to produce virtual model.
- Treat II software used to simulate the teeth movement.
- Clincheck allows Orthodontist to reviews, modify, and approve the treatment plan. Stereo lithography treatment cast build precise models of teeth at each stage Individualized, custom-created clear aligners are made from these models.

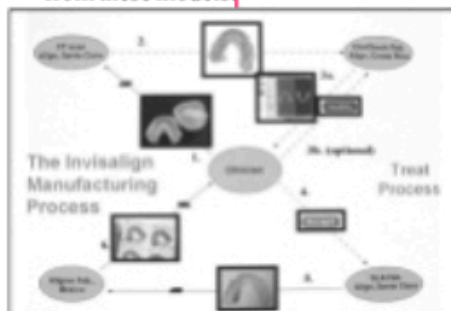

Fig-2- Over View Invisalign Technique

<sup>1</sup> N. Raghunath

<sup>2</sup> Shivalinga.B.M.

<sup>3</sup> Kanhu Charan Sahoo

<sup>1</sup> Associate Professor, Dept. Of Orthodontics and DentofacialOrthopaedics J.S.S.Dental College and Hospital, Mysore, Karnataka, India.

<sup>2</sup> Professor and In-Charge of P.G. Studies Dept. Of Orthodontics and DentofacialOrthopaedics J.S.S. Dental College and Hospital, Mysore, Karnataka

<sup>3</sup> Post Graduate Student Dept. Of Orthodontics and DentofacialOrthopaedics J.S.S. Dental College and Hospital, Mysore, Karnataka

### Address For Correspondence:

Kanhu Charan Sahoo  
Post Graduate Student  
Dept. Of Orthodontics and DentofacialOrthopaedics  
J.S.S. Dental College and Hospital, Mysore, Karnataka  
Mob no: +91 9986673171  
E-Mail: drkanhu@gmail.com

Date of Submission : 10/02/2011

Date of Acceptance : 18/02/2011

### Diagnosis and Treatment Planning (Selection criteria) 2:

- Fully erupted permanent teeth,
- Growth has minimal or no effect on treatment (i.e., late adolescents and adults). ©Mild spacing (1-3 mm), moderate spacing (4-6 mm),
- Mild crowding (1-3 mm), moderate crowding (4-6 mm),
- Narrow arches that are dental in origin (4-6 mm),
- Treated cases with relapse

### Orthodontic movements which can be produced effectively:<sup>4,5,9&10</sup>

- Space closure
- Tooth movement following Interproximal reduction
- Dental (not skeletal) expansion,
- Flaring
- Distalization
- Space closure following the extraction of a lower incisor

### Certain malocclusion more difficult to treat<sup>3,5:</sup>

- Crowding and spacing over 5mm.
- Skeletal antero-posterior discrepancies
- Centric relation and centric occlusion discrepancies.
- Severely rotated teeth (more than 20 degrees).
- Open bites (anterior and posterior).
- Extrusion of teeth



# Journal of International Oral Health

Official Publication of International Society of Preventive and Community Dentistry

## REVIEW ARTICLE

Year : 2020 | Volume : 12 | Issue : 7 | Page : 1--4

## Clear aligner therapy—Narrative review

**Aljazi H Aljabaa**

Division of Orthodontics, Department of Pediatric Dentistry and Orthodontics, College of Dentistry, King Saud University, Riyadh, Saudi Arabia

### Correspondence Address:

Aljazi H Aljabaa

Assistant Professor, Division of Orthodontics, Department of Pediatric Dentistry and Orthodontics, College of Dentistry, King Saud University, Saudi Arabia, 8357 al buhayrat-ar rahmaniyah, Riyadh 12343-3664.  
Saudi Arabia

## Abstract

Clear aligners are gaining more popularity, as most patients, especially adults, dislike the appearance of fixed appliances. In 1997, Align Technology® (Santa Clara, CA) released the Invisalign® system. The company used both computer-aided design (CAD) and computer-aided manufacturing (CAM) to produce its orthodontic appliances. This technology, which allows for multiple tooth movements from a single impression, introduced the clear aligner as it is now known. At the beginning, the Invisalign® system was used to treat simple tooth movement. However, as it developed, the manufacturer began using attachments and intermaxillary elastics to obtain different movements, so Invisalign® became a viable alternative to fixed appliances. Different aligner systems similar to Invisalign®, such as ClearCorrect, etc., became available on the market, and they use the same principle to obtain the desired results. This review investigated the indications and contraindications of clear aligner therapy (CAT), including its efficiency and limitations; patient comfort and acceptance; and periodontal health, root resorption, and stability. In conclusion, CAT has been improved over the last 18 years and is still being improved. The treatment results depend on the clinician's own experience, case selection, and patient adherence. The clinician should be clear about the advantages and disadvantages of CAT, and the patient should be made aware that he/she should wear the appliance for 22–23h/day and only remove it while eating. The limitations of this study are lack of comparison between available CAT systems, the types and mechanics of movement produced by different types of attachments, and the cost.

### How to cite this article:

Aljabaa AH. Clear aligner therapy—Narrative review. *J Int Oral Health* 2020;12:1-4

### How to cite this URL:

Aljabaa AH. Clear aligner therapy—Narrative review. *J Int Oral Health* [serial online] 2020 [cited 2021 Feb 20 ];12:1-4

Available from: <https://www.jioh.org/text.asp?2020/12/7/1/276086>

## Full Text

### Introduction

# The Aesthetic Alternative in Orthodontics With Sequential Aligners: The Invisalign System

**Author(s):** Muggiano F, Quaranta A

## Abstract

---

The Invisalign treatment consists of a series of nearly invisible and removable aligners that are replaced every two weeks by a new set. Each aligner is individually manufactured for each patient. In addition, a virtual 3D treatment program (software ClinCheck®) shows the series of movements that teeth will follow during the course of treatment: it allows the patient to know in advance what will be the final result.

In this article are taken into account characteristics, indications, contraindications, disadvantages and advantages, among which the fact of being customized (dental impressions are taken that will serve to make the aligners), removable (for eating, drinking, brushing teeth), effective (the alignment of teeth begins immediately), comfortable (do not irritate gums or mouth) and transparent. Invisalign can transform the smile without interfering with the daily life of patients.

## Introduction

---

The Invisalign (Align Technology, Inc.) was introduced in 1999 based on the principles of Kesling (1945), Mr. Nahum (1964) and other authors such as Ponitz (1971) and McNamara. The whole process of realization of the Invisalign aligners is a marvel of modern technology. This system uses the CAD-CAM technology in combination with laboratory techniques to fabricate a series of positioners (aligners) in polyurethane. These aligners are personalized, aesthetic and removable, capable of producing tooth movement (in increments of about 0.25-0.3 mm) from beginning to end of treatment. For each patient, the orthodontist submits a set of polyvinyl siloxane impressions, a centric occlusion bite registration, a panoramic radiograph, a lateral cephalometric radiograph, and photographs to Align Technology. At this point, the system scans the plaster models, develops a 3D presentation, separates the teeth (allowing them to be moved individually) and places virtual gum, thus simulating the results.

Tooth movements are staged in order to avoid

interproximal and occlusal interferences; the number of stages required is related to the amount and complexity of the necessary movement. These data are then sent to the orthodontist: when he has approved the proposed treatment plan, the aligners will be manufactured in order to reproduce, on the patient, the observed movement on the monitor. Each aligner is laser-engraved with the patient's initials, case number, aligner number and arch (upper and lower). They are then disinfected, packaged and shipped to the orthodontist.

## Discussion

---

**What is Invisalign:** the Invisalign appliance includes a series of aligners that consist of a transparent, thin (less than 1 mm) plastic material manufactured with CAD-CAM technology. Each aligner is able to move the teeth a maximum of 0.25-0.3 mm in a period of two weeks and it must be worn in a specific sequence.

It is suitable for mild nonskeletal malocclusions in adult and adolescent patients, in the permanent dentition, with an acceptable level of compliance.

### Illustration 1. Invisalign Aligners.

**1. Compliance:** since these devices are removable, patient motivation is important to achieve the desired results: to be effective, in fact, these devices must be worn 22 hours a day (must be removed during meals, when drinking hot drinks that could spot or cause deformation, sugary drinks and during the oral hygiene at home).

**2. Clinician's involvement:** despite the diagnostic preparation is similar to that used for therapy with conventional fixed orthodontic appliances, clinician plays a more limited role during treatment with the Invisalign appliances. After preparation, which includes an initial assessment, diagnosis, treatment planning and records (impressions, bite registration, radiographs, photographs), clinician displays the virtual treatment to evaluate the final position of the teeth given by the system: at this point he may require changes but, once the aligners have been produced, they can no longer be altered during the treatment. If the results are unsatisfactory, clinician may use

# Invisalign®—15 years later, has it become a real alternative to fixed appliances?

J.-F. Chazalon

*Specialist certified in DFO, private practice*

## ABSTRACT

*After 15 years of existence in France, Invisalign® has become a credible alternative to treatment with attachments. This article aims to review the latest developments made by Invisalign® and the results achieved at the clinical level. In our review, which includes clinical case photographs, we explore the possibilities of the system, including expected results, limitations, and associated precautions.*

## KEY WORDS

*Invisalign®, ClinCheck Aligners, evaluation tooth movements, unwanted movements*

## INTRODUCTION

One of the constants of the evolution of orthodontic devices is the search for an esthetic device which, in patient language, translates to an “unseen device.”

This request for discretion occurred initially with the appearance of ceramic brackets and then lingual orthodontic devices. Another track emerged 15 years ago when thermoformed splints or aligners were used, dental displacement was no longer being performed by brackets and arches but by the successive change facilitated by transparent thermoformed splints or aligners.

If the esthetic criteria and the notion of comfort<sup>5,6,7</sup> have been major arguments in the use of aligners to the detriment of the limitations of the technique, the evolution

of materials and the contribution of digital technologies have revived the use of this type of « plastic » orthodontics, particularly with Invisalign being developed by Align Technology (Santa Clara, California) in 1999 and from 2001 in France.

In the study on Invisalign, we find two distinct parts that are key to system and the control of which is crucial to the success of our treatments:

- The treatment tool, the alignment splint, and aligners are responsible for dental displacement
- The tool to be decided on is the ClinCheck, a proprietary software application that visualizes the stages of treatment until the final result and this

Adresse de correspondance :

Jean-François Chazalon  
30, avenue Jean Jaurès – 30900 Nîmes – France  
E-mail: dr.chazalon@orange.fr

*Article received: 04-02-2016.*

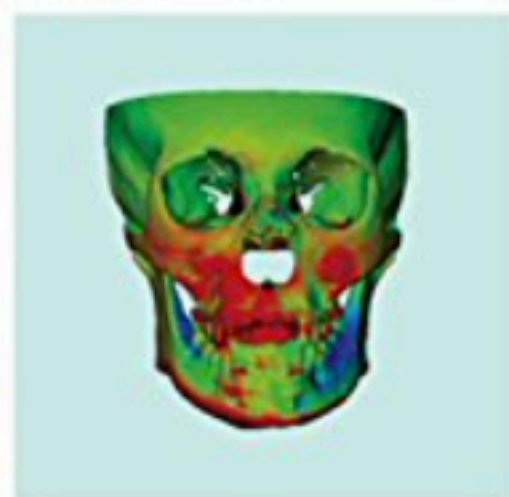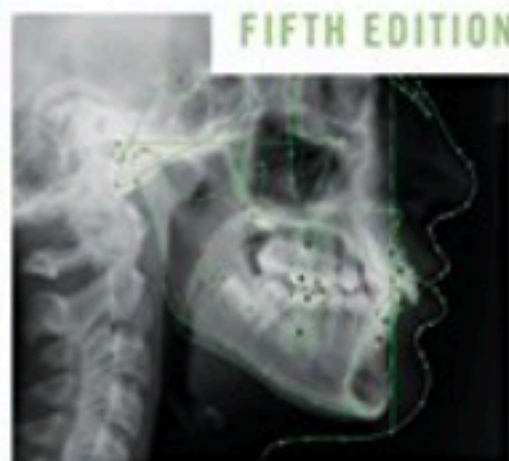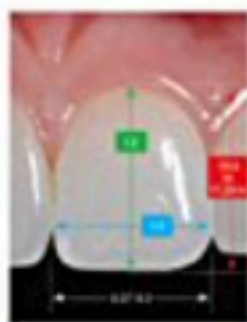
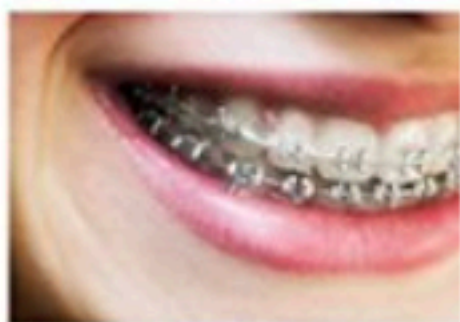*Accepted for publication: 10-06-2016.*

This is an Open Access article distributed under the terms of the Creative Commons Attribution License (<http://creativecommons.org/licenses/by/4.0>), which permits unrestricted use, distribution, and reproduction in any medium, provided the original work is properly cited.



# CONTEMPORARY ORTHODONTICS

WILLIAM R. PROFFIT • HENRY W. FIELDS • DAVID M. SARVER



ELSEVIER

RESEARCH ARTICLE

Open Access

# Treatment outcome and efficacy of an aligner technique – regarding incisor torque, premolar derotation and molar distalization

Mareike Simon<sup>1,2\*</sup>, Ludger Keilig<sup>1</sup>, Jörg Schwarze<sup>3</sup>, Britta A Jung<sup>2</sup> and Christoph Bourauel<sup>1</sup>

## Abstract

**Background:** The aim of this study was to investigate the efficacy of orthodontic treatment using the Invisalign® system. Particularly, we analyzed the influence of auxiliaries (Attachment/Power Ridge) as well as the staging (movement per aligner) on treatment efficacy.

**Methods:** We reviewed the tooth movements of 30 consecutive patients who required orthodontic treatment with Invisalign®. In all patients, one of the following tooth movements was performed: (1) Incisor Torque >10°, (2) Premolar derotation >10° (3) Molar distalization >1.5 mm. The groups (1)-(3) were subdivided: in the first subgroup (a) the movements were supported with the use of an attachment, while in the subgroup (b) no auxiliaries were used (except incisor torque, in which Power Ridges were used). All tooth movements were performed in a split-mouth design. To analyze the clinical efficacy, pre-treatment and final plaster cast models were laser-scanned and the achieved tooth movement was determined by way of a surface/surface matching algorithm. The results were compared with the amount of tooth movement predicted by ClinCheck®.

**Results:** The overall mean efficacy was 59% (SD = 0.2). The mean accuracy for upper incisor torque was 42% (SD = 0.2). Premolar derotation showed the lowest accuracy with approximately 40% (SD = 0.3). Distalization of an upper molar was the most effective movement, with efficacy approximately 87% (SD = 0.2).

**Conclusion:** Incisor torque, premolar derotation and molar distalization can be performed using Invisalign® aligners. The staging (movement/aligner) and the total amount of planned movement have a significant impact on treatment efficacy.

## Background

In 1999, the Invisalign® system was introduced to the orthodontic market as a system of treating mild malocclusions, such as minor crowding and space closure [1]. In the following years, the system developed: different attachment designs and auxiliaries such as Precision Cuts and Power Ridges were designed to enable additional treatment of difficult malocclusions. According to the manufacturer, Invisalign® can effectively perform major tooth movements, such as bicuspid derotation up to 50 degrees and root movements of upper central

incisors up to 4 mm [2]. In reference to the literature, however, there is no consensus about the exact indications of this system's treatment [3]. This may be because little is known about orthodontic therapy with removable thermoplastic appliances (RTAs). Prior publications on Invisalign® mainly cover technical aspects, materials studies and case reports [4,5]. Only a few studies have concentrated on the efficacy of the treatment: Kravitz et al. [6] evaluated the accuracy of anterior tooth movement using the Invisalign® system and reported a mean accuracy of 41%. The most effective movement was lingual constriction (47.1%), and the least accurate movement was extrusion (29.6%).

To date, no published data could be found concerning the efficacy of tooth movements such as molar distalization and incisor torque with removable thermoplastic

\* Correspondence: mareike.simon@uniklinik-freiburg.de

<sup>1</sup>Oral Technology Medical Faculty, Dental School, University of Bonn, Welschnonnenstr, 17 53111 Bonn, Germany

<sup>2</sup>Department of Orthodontics, University Medical Center, Hugstetter. Str. 55, 79106 Freiburg, Germany

Full list of author information is available at the end of the article



## The Technology Behind the Invisalign® System

By Rene Sterental, DDS

In August 2005, Align Technology, Inc., in collaboration with ADHA, began a series of articles in *Access* designed to educate the dental hygiene community on the Invisalign technique. In the first article, Lou Shuman, DMD, CAGS, vice president of Strategic Relations for Align, introduced the Invisalign technique. In the second, Robert Boyd, DDS, MEd, professor and chairman of Orthodontics at the University of the Pacific, outlined the advantages of Invisalign from a periodontal perspective.

This third and final article in the series explores in detail the technology behind the technique. This innovative technology makes it possible for a dentist to take a series of clinical records and provide the patient with an individually customized orthodontic treatment plan that uses an esthetically pleasing, minimally invasive orthodontic appliance.

Patients seeking information on orthodontic treatments are excited to learn how technology helps them achieve their goals, and in their role as both educator and diagnostician, dental hygienists are in a unique position to help the patient better understand how the technology works to benefit patients. Additionally, hygienists play a very important role in engaging patients in the treatment process, ensuring compliance from day one, monitoring progress, and providing clinical support throughout the Invisalign treatment. Understanding the technology behind the Invisalign technique allows them to fulfill their role with better understanding and to engage more effectively with both the dentist and their patients.

### Interacting with Invisalign: VIP & ClinCheck® Software Tools

With the Invisalign system, practices can take full advantage of the Internet age. Dentists and team members interact with Align Technology through a Web-based interface called Virtual Invisalign Practice® (VIP). Currently in its

**With the Invisalign system, practices can take full advantage of the Internet age.**

Name	Status
Ahd, Daf	Waiting For Submission (Submit)
Aliso, Doctor	Waiting For Submission (Submit)
Andradafaf, Fafafafafafaf	Case Evaluation Response Ready (View Response)
Asdf, Asdf A	Case Evaluation Response Ready (View Response)
Asper, William T	Case Evaluation Response Ready (View Response)
D, Ds	Case Evaluation Response Ready (View Response)
Delner, Charles W	Case Evaluation Response Ready (View Response)
Den, Berner E	Case Evaluation Response Ready (View Response)
Ddd, Dkkk	Case Evaluation Response Ready (View Response)
Dasfidi, Malasdi	Case Evaluation Response Ready (View Response)
Elmster, Laha	Waiting For Submission (Submit)
Estrella, Chrystander P	Case Evaluation Response Ready (View Response)
Fafife, Fmoaxa	Case Evaluation Response Ready (View Response)

Figure 1. Virtual Invisalign Practice—VIP 2.0

second generation, VIP 2.0 provides quick, intuitive access to complete patient and case status (Figure 1). Through VIP, the office manages general operations such as direct patient login, record submission for a case, case review and acceptance, dentist profile updates and patient file information on current and past orders. It also can access marketing resources, news updates, promotions, clinical support and more. The program constitutes a fundamental way of interacting and managing everything related to Invisalign in the dental practice.

ClinCheck® is Align's proprietary software program that allows the dentist and clinical team members to review and modify the virtual treatment plan Align creates based on the dentist's initial treatment prescription. This gives the dentist and team members the flexibility to customize their interaction with the Invisalign treatment to meet their practice requirements. The ClinCheck software also gives dentists and team members a tool to educate the patient on the scope of the treatment and its goals and challenges. In the software program, the treatment plan is presented visually, the patient is able to participate in the process, and their input can be used to fine-tune the treatment plan accordingly.



# How well does Invisalign work? A prospective clinical study evaluating the efficacy of tooth movement with Invisalign

Neal D. Kravitz,<sup>a</sup> Budi Kusnoto,<sup>b</sup> Ellen BeGole,<sup>c</sup> Ales Obrez,<sup>d</sup> and Brent Agran<sup>e</sup>

South Riding, Va, White Plains, Md, and Chicago, Ill

**Introduction:** The purpose of this prospective clinical study was to evaluate the efficacy of tooth movement with removable polyurethane aligners (Invisalign, Align Technology, Santa Clara, Calif). **Methods:** The study sample included 37 patients treated with Anterior Invisalign. Four hundred one anterior teeth (198 maxillary and 203 mandibular) were measured on the virtual Treat models. The virtual model of the predicted tooth position was superimposed over the virtual model of the achieved tooth position, created from the posttreatment impression, and the 2 models were superimposed over their stationary posterior teeth by using ToothMeasure, Invisalign's proprietary superimposition software. The amount of tooth movement predicted was compared with the amount achieved after treatment. The types of movements studied were expansion, constriction, intrusion, extrusion, mesiodistal tip, labiolingual tip, and rotation. **Results:** The mean accuracy of tooth movement with Invisalign was 41%. The most accurate movement was lingual constriction (47.1%), and the least accurate movement was extrusion (29.6%)— specifically, extrusion of the maxillary (18.3%) and mandibular (24.5%) central incisors, followed by mesiodistal tipping of the mandibular canines (26.9%). The accuracy of canine rotation was significantly lower than that of all other teeth, with the exception of the maxillary lateral incisors. At rotational movements greater than 15°, the accuracy of rotation for the maxillary canines fell significantly. Lingual crown tip was significantly more accurate than labial crown tip, particularly for the maxillary incisors. There was no statistical difference in accuracy between maxillary and mandibular teeth of the same tooth type for any movements studied. **Conclusions:** We still have much to learn regarding the biomechanics and efficacy of the Invisalign system. A better understanding of Invisalign's ability to move teeth might help the clinician select suitable patients for treatment, guide the proper sequencing of movement, and reduce the need for case refinement. (*Am J Orthod Dentofacial Orthop* 2009; 135:27-35)

In 1998, Align Technology (Santa Clara, Calif) introduced Invisalign, a series of removable polyurethane aligners, as an esthetic alternative to fixed labial braces. The Invisalign system uses CAD/CAM stereolithographic technology to forecast treatment and fabricate many custom-made aligners from a single impression.<sup>1</sup> Each aligner is programmed to move a tooth or a small group of teeth 0.25 to 0.33 mm every 14 days.<sup>2</sup> This unique method of tooth movement has involved more adults with orthodontic therapy. In the

past decade, Invisalign has been used to treat over 300,000 people worldwide,<sup>3,4</sup> most of them above 19 years of age.<sup>5</sup>

As Invisalign continues to grow in consumer demand and professional use, questions regarding the efficacy of this system remain. How well do removable aligners move teeth? Align Technology reports that 20% to 30% of patients treated with Invisalign might require either mid-course correction or refinement impressions to help achieve the pretreatment goals.<sup>2</sup> However, many orthodontists report that 70% to 80% of their patients require midcourse correction, case refinement, or conversion to fixed appliances before the end of treatment.<sup>6,7</sup>

There are few substantive controlled clinical trials pertaining to Invisalign. Lagravère and Flores-Mir<sup>8</sup> conducted a systematic review of the literature about the Invisalign system and found that it did not offer scientific evidence regarding the indication, efficacy, limitations, or treatment effects of Invisalign. To date, published data have primarily included case reports, commentaries, material studies, surveys, descriptive

From the School of Dentistry, University of Illinois, Chicago.

<sup>a</sup>Private practice, South Riding, Va, and White Plains, Md.

<sup>b</sup>Assistant professor and clinical chair, Department of Orthodontics.

<sup>c</sup>Associate professor, Department of Orthodontics.

<sup>d</sup>Associate professor, Department of Restorative Dentistry.

<sup>e</sup>Postgraduate student.

Reprint requests to: Neal D. Kravitz, University of Illinois, Department of Orthodontics, 801 S Paulina St, MC 841, Chicago, IL 60612; e-mail, [nealkravitz@gmail.com](mailto:nealkravitz@gmail.com).

Submitted, March 2007; revised and accepted, May 2007.

0889-5406/\$36.00

Copyright © 2009 by the American Association of Orthodontists.

doi:10.1016/j.ajodo.2007.05.018





## The predictability of transverse changes with Invisalign

Jean-Philippe Houle<sup>a</sup>; Luis Piedade<sup>b</sup>; Reynaldo Todescan Jr<sup>c</sup>; Fabio H. S. L. Pinheiro<sup>b</sup>

### ABSTRACT

**Objectives:** To investigate the predictability of arch expansion using Invisalign.

**Materials and Methods:** Sixty-four adult white patients were selected to be part of this retrospective study. Pre- and posttreatment digital models created from an iTero scan were obtained from a single orthodontist practitioner. Digital models from Clincheck were also obtained from Align Technology. Linear values of upper and lower arch widths were measured for canines, premolars, and first molars at two different points: lingual gingival margins and cusp tips. A paired *t*-test was used to compare expansion planned on Clincheck with the posttreatment measurements. Variance ratio tests were used to determine if a larger change planned was associated with larger error.

**Results:** For every maxillary measurement, there was a statistically significant difference between Clincheck and final outcome ( $P < .05$ ), with prediction worsening toward the posterior region of the arch. For the lower arch measurements at the gingival margin, there was a statistically significant difference between the Clincheck planned expansion and the final outcome ( $P < .05$ ). Points measured at the cusp tips of the lower arch teeth showed nonstatistically significant differences between Clincheck prediction and the final outcome ( $P > .05$ ). Variance ratios for upper and lower arches were significant ( $P < .05$ ).

**Conclusions:** The mean accuracy of expansion planned with Invisalign for the maxilla was 72.8%. The lower arch presented an overall accuracy of 87.7%. Clincheck overestimates expansion by body movement; more tipping is observed. Overcorrection of expansion in the posterior region of the maxillary arch seems appropriate. (*Angle Orthod.* 2017;87:19–24)

**KEY WORDS:** Invisalign; Predictability

### INTRODUCTION

Invisalign involves a series of plastic aligners that move the teeth. The aligners are removable and are made of 0.75-mm-thick polyurethane.<sup>1,2</sup> Patients are to wear an aligner for a period of 1–2 weeks and then change to the next one. Each aligner is programmed to

produce a precise movement on a tooth of about 0.15–0.25 mm.<sup>3</sup> The stereolithographic technology is used to fabricate custom aligners from an impression or an intraoral digital image scanned in the dental office. Patient compliance is mandatory to achieve good results with Invisalign. It is important for patients to wear their aligners 22 hours a day or more.<sup>4</sup>

Arch expansion is possible with Invisalign and may be required as a perceived need to improve the esthetics of the smile by broadening the dental arches<sup>5</sup> or as a mechanism to create space for resolution of crowding.<sup>6,7</sup> It can also be used as a way of correcting dentoalveolar posterior crossbites.<sup>8</sup>

In their 2001 publication on treatment of complex malocclusion using Invisalign, Boyd and Vlaskalic<sup>3</sup> reported that buccal expansion can be achieved to alleviate crowding or to modify the arch form. The range of expansion would be 2–4 mm. In an article by Ali et al.<sup>2</sup> in 2012, it was stated that dentoalveolar expansion is possible with Invisalign and can be an alternative to interproximal reduction. According to the same authors, expansion of the dental arches should

<sup>a</sup> Graduate Orthodontic Resident, Department of Preventive Dental Science, Division of Orthodontics, School of Dentistry, University of Manitoba, Winnipeg, Manitoba, Canada.

<sup>b</sup> Assistant Professor, Department of Preventive Dental Science, Division of Orthodontics, School of Dentistry, University of Manitoba, Winnipeg, Manitoba, Canada.

<sup>c</sup> Assistant Professor, Department of Restorative Dentistry, School of Dentistry, University of Manitoba, Winnipeg, Manitoba, Canada.

Corresponding author: Dr Fabio H. L. Pinheiro, Department of Preventive Dentistry, School of Dentistry, University of Manitoba, 790 Bannatyne Avenue, Winnipeg, Manitoba, R3E 0W2, Canada (e-mail: fabio.pinheiro@umanitoba.ca)

Accepted: April 2016. Submitted: December 2015.

Published Online: June 15, 2016

© 2017 by The EH Angle Education and Research Foundation, Inc.

# Introduction to Invisalign® Smart Technology: Attachments Design, and Recall-Checks

## Abstract

Modern clear aligners are engineered to expand the boundaries for the utilization of removable appliances to treat a wide variety of malocclusions. Innovation is continually evolving to provide orthodontists with greater control of tooth movement to achieve desired outcomes. Three current technologies are SmartTrack, SmartForce, and SmartStage. Attachment design is an important aspect of ClinCheck. There are 5 questions that provide guide lines for choosing attachments. Two examples are presented to demonstrate the design of dental attachments to facilitate tooth movement. Invisalign G6 is a method for treating patients with extractions, particularly first premolars. It provides vertical and second order (root parallelism) control for predictable outcomes with maximum or moderate anchorage. Efficient management of space closure is an important aspect for aligner therapy because enamel stripping and extractions are common approaches for managing crowding and protrusion. At every appointment it is important to check aligner adaptation (fit), attachment positions, and anchorage preparation. This article reviews clinical procedures for numerous applications and also addresses clinical problems. (*J Digital Orthod* 2019;54:80-95)

### Key words:

*Invisalign clear aligners, ClinCheck software, SmartForce features, SmartTrack material, SmartStage, Attachment design, Invisalign G6, Aligner fit, TADs, CII elastics*

## Introduction

Over the past 15 years Align Technology has invested heavily in clear aligner research and development (R&D) to expand the clinical scope and predictability for management of a broad range of malocclusions in a global market of about 5 million patients. Innovations include SmartTrack, SmartForce, and SmartStage (Fig. 1). From interdental spacing to challenging Class III corrections, treatment options are available for treating a large range of malocclusions.

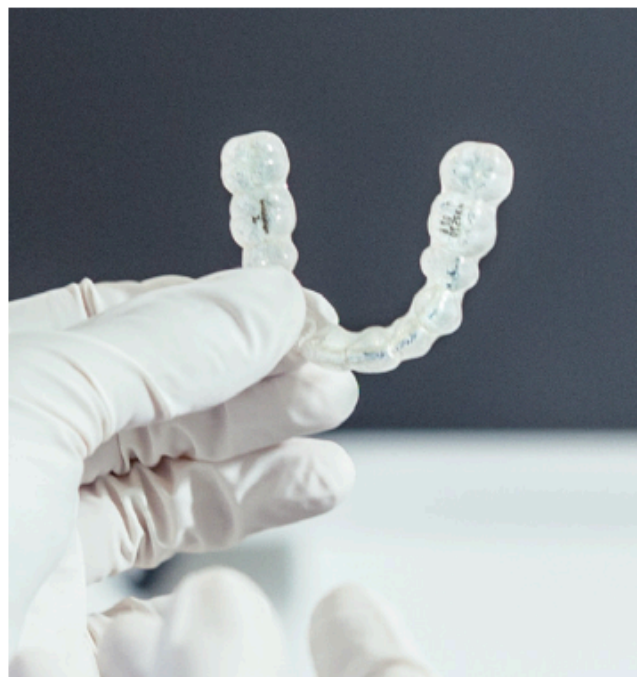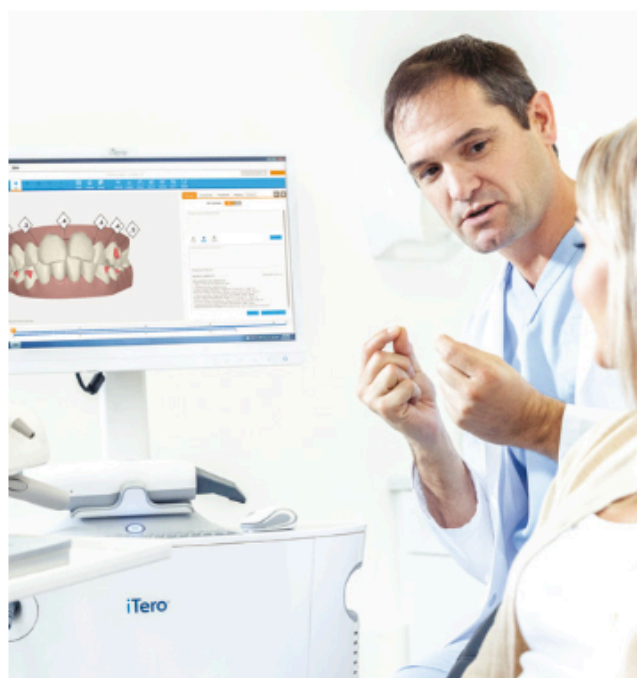
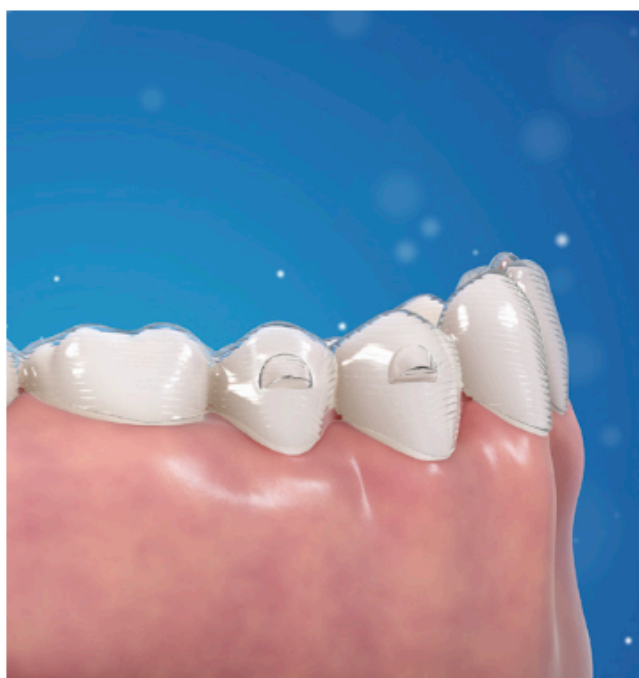## SmartTrack

SmartTrack is a materials innovation that evolved from 8 years of R&D investigating over 260 candidate materials with both biomechanics and materials science expertise.<sup>1</sup> Modern aligner materials are composed of polyurethane derived from methylene diphenyl diisocyanate and 1,6-hexanediol. This is a medical grade polymer with supplemental additives to adjust material properties to produce a product that is clear, strong, thin and flexible. In addition it is hypo-allergic, inert and biologically stable.<sup>2</sup> There are



# SmartForce features and **Attachments**.

Designed to help you treat with confidence.



## Adult patients' adjustability to orthodontic appliances. Part I: a comparison between Labial, Lingual, and Invisalign™

Miri Shalish<sup>\*,†</sup>, Rena Cooper-Kazaz<sup>\*\*,†</sup>, Inbal Ivgi<sup>\*</sup>, Laura Canetti<sup>\*\*\*</sup>, Boaz Tsur<sup>\*</sup>, Eytan Bachar<sup>\*\*\*</sup> and Stella Chaushu<sup>\*</sup>

<sup>\*</sup>Department of Orthodontics, Hebrew University-Hadassah School of Dental Medicine, Jerusalem, <sup>\*\*</sup>Department of Psychiatry, Hadassah University Medical Center, Jerusalem and <sup>\*\*\*</sup>Department of Psychology, Hebrew University of Jerusalem, Israel

<sup>†</sup>These authors contributed equally to this work.

Correspondence to: Miri Shalish, Department of Orthodontics, Hebrew University-Hadassah School of, Dental Medicine, PO Box 12000, Jerusalem 91120, Israel. E-mail: mshalish@hadassah.org.il

**SUMMARY** This prospective study examined the adult patient's perception of recovery after insertion of three types of orthodontic appliances: Buccal, Lingual and Invisalign.

The sample consisted of sixty-eight adult patients (45 females and 23 males) who comprised three groups: 28 Buccal, 19 Lingual, and 21 Invisalign patients. After appliance insertion, patients completed a Health-Related Quality of Life questionnaire daily for the first week and again on day 14, in order to assess patients' perception of pain and analgesic consumption. In addition, four areas of dysfunction were assessed: oral dysfunction, eating disturbances, general activity parameters, and oral symptoms.

Lingual appliance was associated with more severe pain and analgesic consumption, the greatest oral and general dysfunction, and the most difficult and longest recovery. The Invisalign patients complained of relatively high levels of pain in the first days after insertion; however this group was characterized by the lowest level of oral symptoms and by a similar level of general activity disturbances and oral dysfunction compared to the Buccal appliance.

Many Lingual and some Buccal patients did not reach a full recovery from their eating difficulties by the end of the study period.

The present study provides information to adult patients and clinicians assisting them in choosing the most appropriate treatment modality in relation to Health-Related Quality of Life parameters.

### Introduction

Current advances in orthodontics have broadened the possibilities of invisible orthodontic appliances offered to adult patients. For some patients, aesthetic considerations during treatment are as important as other factors, such as comfort, pain, cost, or length of treatment.

Traditional labial appliances (Buccal) remain the main orthodontic appliance used. The introduction of the lingual appliance (Lingual) provided a significant aesthetic advantage to patients (Fujita, 1978), but functional difficulties and a prolonged adaptation reduced its use until recent years (Sinclair *et al.*, 1986; Creekmore, 1989). In 1997, the Invisalign™ appliance was introduced. This appliance is aesthetically superior to the labial appliance and allows for its removal for eating and cleaning (Wong, 2002). The main disadvantages of the invisible techniques (Lingual and Invisalign™) are a higher cost and technical limitations. The mean accuracy of tooth movement in Invisalign™ is 41 per cent. The most accurate movement is associated with lingual constriction (47.1 per cent), and the least accurate movement is extrusion (29.6 per cent; Kravitz *et al.*, 2009). In addition, Invisalign™ patients demonstrated

significantly better periodontal indices than did those with fixed lingual appliances, which indicates a lower periodontal risk throughout treatment (Miethke and Brauner, 2007).

In recent years, adult orthodontic treatments™ have become increasingly popular, and many prefer the Lingual or Invisalign™ techniques. Several studies reported that women under 40 preferred Lingual over Buccal for both aesthetic and professional reasons (Hohoff *et al.*, 2003; Fritz *et al.*, 2004). A similar study found a predominance of 20–30 year old females who selected Invisalign™ over Buccal or Lingual. Their choices were due to aesthetic (compared with Buccal) and functional (compared with Lingual) considerations (Nedwed and Miethke, 2005; Miethka *et al.*, 2003).

Several studies have assessed patient adaptation to various appliances. In a comparison between Buccal and Lingual, no differences in adaptation time were noted, and both appliances needed a month to adjust. Lingual patients reported greater speech disturbances and an irritation of the tongue (Caniklioglu and Oztürk, 2005). Other studies reported no differences in the consumption of analgesics but greater cheeks and lip discomfort in the Buccal patients



## Periodontal status of adult patients treated with fixed buccal appliances and removable aligners over one year of active orthodontic therapy

Marzieh Karkhanechi<sup>a</sup>; Denise Chow<sup>b</sup>; Jennifer Sipkin<sup>c</sup>; David Sherman<sup>d</sup>; Robert J. Boylan<sup>e</sup>; Robert G. Norman<sup>f</sup>; Ronald G. Craig<sup>g</sup>; George J. Cisneros<sup>h</sup>

### ABSTRACT

**Objective:** To compare the periodontal status of adults treated with fixed buccal orthodontic appliances vs removable orthodontic aligners over 1 year of active therapy.

**Materials and Methods:** The study population consisted of 42 subjects; 22 treated with fixed buccal orthodontic appliances and 20 treated with removable aligners. Clinical indices recorded included: plaque index (PI), gingival index (GI), bleeding on probing (BOP), and probing pocket depth (PPD). Plaque samples were assessed for hydrolysis of N-benzoyl-DL-arginine-naphthylamide (BANA test). Indices and BANA scores were recorded before treatment and at 6 weeks, 6 months, and 12 months after initiation of orthodontic therapy.

**Results:** After 6 weeks, only mean PPD was greater in the fixed buccal orthodontic appliance group. However, after 6 months, the fixed buccal orthodontic appliance group had significantly greater mean PI, PPD, and GI scores and was 5.739 times more likely to have a higher BANA score. After 12 months, the fixed buccal orthodontic appliance group continued to have greater mean PI, GI, and PPD, while a trend was noted for higher BANA scores and BOP.

**Conclusions:** These results suggest treatment with fixed buccal orthodontic appliances is associated with decreased periodontal status and increased levels of periodontopathic bacteria when compared to treatment with removable aligners over the 12-month study duration. (*Angle Orthod.* 2013;83:146–151.)

**KEY WORDS:** Fixed orthodontic appliances; Orthodontic aligners; Gingival inflammation

### INTRODUCTION

The introduction of esthetic orthodontic treatment options has prompted an increasing number of adults to request orthodontic therapy. In contrast to the adolescent patient, in whom caries is the primary dental concern, the adult patient may also present with, or be at risk for, periodontal diseases.<sup>1</sup> Data from NHANES III suggest 14% of the US population over 20 years of age have moderate to severe periodontitis.<sup>2</sup> Depending upon the criteria used to define periodontal disease status and severity, some epidemiologic studies have reported an even greater prevalence of periodontal diseases.<sup>3</sup> Therefore, as more adults enter orthodontic therapy, the practitioner must consider the effects that orthodontic treatment, including appliance type, may have on periodontal health.

The entire periodontium, including osseous and soft tissue components, remodels with orthodontic tooth movement.<sup>4</sup> However, the presence of periodontal inflammation may inhibit remodeling and compromise the outcome of treatment through the loss of periodontal

<sup>a</sup> Private practice, Rancho Cuocomanga, Calif.

<sup>b</sup> Private practice, Nashua, NH.

<sup>c</sup> Private practice, Merrick, NY.

<sup>d</sup> Private practice, Great Neck, NY.

<sup>e</sup> Associate Professor, Department of Basic Sciences and Craniofacial Biology, New York University College of Dentistry, New York, NY.

<sup>f</sup> Associate Professor, Department of Epidemiology and Health Promotion, New York University College of Dentistry, New York, NY.

<sup>g</sup> Associate Professor, Department of Basic Sciences and Craniofacial Biology, Department of Periodontology and Implant Dentistry, New York University, College of Dentistry, New York, NY.

<sup>h</sup> Professor, Department of Orthodontics, New York University College of Dentistry, New York, NY.

Corresponding author: Dr Ronald Craig, Associate Professor, Department of Basic Sciences and Craniofacial Biology, New York University, College of Dentistry, 345 East 24th Street, New York, NY 10010 (e-mail: rgc1@nyu.edu).

Accepted: May 2012. Submitted: March 2012.

Published Online: June 22, 2012

© 2013 by The EH Angle Education and Research Foundation, Inc.

# Assessment of the periodontal health status in patients undergoing orthodontic treatment with fixed appliances and Invisalign system

## A meta-analysis

Haili Lu, MD, Haifang Tang, MD, Tian Zhou, MD, Na Kang, MD, PhD\*

### Abstract

**Background:** At present, many scholars have studied the periodontal health status of patients undergoing orthodontic treatment with fixed appliances and invisalign. However, those results are inconsistent. Therefore, we conducted this meta-analysis, and then provide reference for clinical treatment.

**Methods:** Most databases, such as the Cochrane Library, EMBASE, PubMed, Medline, Chinese Biomedical Literature Database, CNKI, and Wan Fang Data were retrieved for related articles from the establishment of the database to October 2017. Meanwhile, we also searched the references of the related literatures manually, in order to increase the included literatures. Two researchers screened the related literatures according to the inclusion criteria and exclusion criteria. Stata 12.0 software was used for data analysis, and results are estimated by odds ratio (OR) and 95% confidence interval (CI).

**Results:** Finally, 7 articles, including 368 patients, were included into our meta-analysis. Meta-analysis results showed that there was no statistically significant difference of gingival index (GI) and sulcus probing depth (SPD) status between the invisalign group and the control group, including at 1, 3, and 6 months (all  $P > .05$ ). When compared with the control group, the invisalign group presented a lower plaque index (PLI) and sulcus bleeding index (SBI) status at 1 month (OR = -0.53, 95% CI: -0.89 to -0.18; OR = -0.44, 95% CI: -0.70 to -0.19, respectively), 3 months (OR = -0.69, 95% CI: -1.12 to -0.27; OR = -0.49, 95% CI: -0.93 to -0.05, respectively), and 6 months (OR = -0.91, 95% CI: -1.47 to -0.35; OR = -0.40, 95% CI: -0.63 to -0.07, respectively). Subgroup analysis showed that the SPD status was lower in the invisalign group at 6 months when measured the teeth using Ramfjord index (OR = -0.74, 95% CI: -1.35 to -0.12). However, there was no statistically significant difference between the 2 groups when using other measure methods (OR = 0.12, 95% CI: -0.26 to 0.17).

**Conclusion:** Our meta-analysis suggests that comparing with the traditional fixed appliances, patients treated with invisalign have a better periodontal health. However, more studies are needed to confirm this conclusion in the future.

**Abbreviations:** 95% CI = 95% confidence interval, GI = gingival index, NOS = Newcastle-Ottawa Scale, OR = odds ratio, PLI = plaque index, RCT = randomized controlled trial, SBI = sulcus bleeding index, SPD = sulcus probing depth.

**Keywords:** fixed appliances, invisalign, meta-analysis., orthodontic, periodontal health status

## 1. Introduction

At present, with the development of medical technology and the improvement of people's living standard, people pay more and more attention to the appearance of their periodontal health

Editor: Giovanni Tarantino.

Funding: This study was supported by the Affiliated Stomatological Hospital of Guangxi Medical University.

The authors have no conflicts of interest to disclose.

Department of Orthodontics, the Affiliated Stomatological Hospital of Guangxi Medical University, Nanning, Guangxi, China.

\* Correspondence: Na Kang, Department of Orthodontics, the Affiliated Stomatological Hospital of Guangxi Medical University, Nanning, Guangxi 530021, China (e-mail: drnkangna@163.com).

Copyright © 2018 the Author(s). Published by Wolters Kluwer Health, Inc. This is an open access article distributed under the Creative Commons Attribution-NoDerivatives License 4.0, which allows for redistribution, commercial and non-commercial, as long as it is passed along unchanged and in whole, with credit to the author.

Medicine (2018) 97:13(e0248)

Received: 24 October 2017 / Received in final form: 1 March 2018 / Accepted: 6 March 2018

<http://dx.doi.org/10.1097/MD.00000000000010248>

status. Up to now, fixed orthodontic treatment is still the best choice for the various types of malocclusions.<sup>[1]</sup> Traditional metal stents are often recommended for patients with severe occlusion or corrective problems. Although the efficacy of the traditional braces has been recognized all over the world, it still has some disadvantages. For example, wearing a traditional braces will make people feel uncomfortable, and it is difficult to conventional cleaning. Patients must carefully brush each bracket and floss around the wires to remove all traces of plaque, in order to reduce the risk of demineralization during this treatment.<sup>[2]</sup> In addition, Yáñez-Vico et al<sup>[3]</sup> found that regular adjustments can be uncomfortable and inconvenient, which will seriously hampers proper oral hygiene, creates numerous plaque retention sites and then potentially leading to develop white spot lesions, caries, and periodontitis. Some previous studies have found that treating with fixed orthodontic appliances will stimulate the growth of a subgingival plaque, thus leading to some adverse effects, and then increase the discomfort of those patient.<sup>[4-6]</sup> Therefore, using an alternative removable orthodontic appliances may allow those patients to maintain an adequate oral hygiene, and then reduce the risk for negative dental and periodontal complications.<sup>[6-8]</sup>

The Invisalign system (Align Technology, Santa Clara, CA), a new generation of removable, clear semi elastic polyurethane



# A comparison of treatment impacts between Invisalign aligner and fixed appliance therapy during the first week of treatment

Kevin B. Miller,<sup>a</sup> Susan P. McGorray,<sup>b</sup> Randy Womack,<sup>c</sup> Juan Carlos Quintero,<sup>d</sup> Mark Perelmutter,<sup>e</sup> Jerome Gibson,<sup>f</sup> Teresa A. Dolan,<sup>g</sup> and Timothy T. Wheeler<sup>h</sup>

Rock Hill, SC, Gainesville and Miami, Fla, Glendale, Ariz, Louisville, Ky, and San Antonio, Tex

**Introduction:** The aim of this study was to evaluate the differences in quality of life impacts between subjects treated with Invisalign aligners (Align Technology, Santa Clara, Calif) and those with fixed appliances during the first week of orthodontic treatment. **Methods:** A prospective, longitudinal cohort study involving 60 adult orthodontic patients (33 with Invisalign aligners, 27 with fixed appliances) was completed by using a daily diary to measure treatment impacts including functional, psychosocial, and pain-related outcomes. A baseline survey was completed before the start of treatment; diary entries were made for 7 consecutive days to measure various impacts of the subjects' orthodontic treatment over time. The data were then analyzed for differences between treatment modalities in terms of the subjects' reported impacts from their orthodontic treatment. **Results:** The baseline mean values did not differ between groups for pain reports ( $P = .22$ ) or overall quality of life impact ( $P = .51$ ). During the first week of treatment, the subjects in the Invisalign group reported fewer negative impacts on overall quality of life ( $P < .0001$ ). The Invisalign group also recorded less impact in each quality of life subscale evaluated (functional, psychosocial, and pain-related, all  $P < .003$ ). The visual analog scale pain reports showed that subjects in the Invisalign group experienced less pain during the first week of treatment ( $P < .0001$ ). The subjects in the fixed appliance group took more pain medications than those in the Invisalign group at days 2 and 3 (both  $P < .007$ ). **Conclusions:** Adults treated with Invisalign aligners experienced less pain and fewer negative impacts on their lives during the first week of orthodontic treatment than did those treated with fixed appliances. (*Am J Orthod Dentofacial Orthop* 2007;131:302.e1-302.e9)

The body of literature addressing orthodontic patients' experiences during treatment is relatively small. Most studies in this area focused on the pain experiences of orthodontic patients throughout treatment. Pain resulting from orthodontic treatment was shown to be significant. Jones and Chan<sup>1</sup> found that the pain experienced after initial archwire placement is much greater than pain after extractions. The pain progression after initial archwire placement is

well established in the literature. The pain increases 4 hours after placement of the initial archwire, peaks at 24 hours, and decreases to almost baseline levels at 7 days.<sup>1-4</sup> Stewart et al<sup>5</sup> found that the first 4 to 7 days after initial wire placement are the most critical for the patient in terms of general discomfort. Sergl et al<sup>6</sup> found that patients adapt to new appliances within 7 days after appliance placement. From these studies, it can be concluded that the first 7 days after archwire placement are the crucial times for the patient's adaptation to appliances and when most orthodontic pain is experienced.

Past studies examined the differences in the pain response between different modalities of treatment. Stewart et al<sup>5</sup> observed that subjects with fixed appliances had more problems with comfort, tension, pressure, tightness, pain, and sensitivity than did subjects with removable appliances. They found that functional appliances disturbed speech and swallowing more than fixed appliances. Sergl and Zentner<sup>7</sup> and Sergl et al<sup>8</sup> corroborated these results and found that subjects treated with fixed appliances reported more pain and discomfort than did subjects wearing removable plates,

<sup>a</sup>Private practice, Rock Hill, SC.

<sup>b</sup>Research assistant professor, Department of Epidemiology and Health Policy Research, College of Medicine, University of Florida, Gainesville.

<sup>c</sup>Private practice, Glendale, Ariz.

<sup>d</sup>Private practice, Miami, Fla.

<sup>e</sup>Private practice, Louisville, Ky.

<sup>f</sup>Private practice, San Antonio, Tex.

<sup>g</sup>Professor, Department of Operative Dentistry, dean, College of Dentistry, University of Florida, Gainesville.

<sup>h</sup>Professor and chairman, Department of Orthodontics, College of Dentistry, University of Florida, Gainesville.

Reprint requests to: Susan P. McGorray, Box 100177, Department of Epidemiology and Health Policy Research, University of Florida College of Medicine, Gainesville, FL 32610-0177; e-mail, spmcg@biostat.ufl.edu.

Submitted, February 2006; revised and accepted May 2006.

0889-5406/\$32.00

Copyright © 2007 by the American Association of Orthodontists.

doi:10.1016/j.ajodo.2006.05.031

## Systematic Review Article

# Efficacy of clear aligners in controlling orthodontic tooth movement A systematic review

Gabriele Rossini<sup>a</sup>; Simone Parrini<sup>a</sup>; Tommaso Castroflorio<sup>b</sup>; Andrea Deregibus<sup>c</sup>;  
Cesare L. Debernardi<sup>d</sup>

### ABSTRACT

**Objective:** To assess the scientific evidence related to the efficacy of clear aligner treatment (CAT) in controlling orthodontic tooth movement.

**Materials and Methods:** PubMed, PMC, NLM, Embase, Cochrane Central Register of Controlled Clinical Trials, Web of Knowledge, Scopus, Google Scholar, and LILACs were searched from January 2000 to June 2014 to identify all peer-reviewed articles potentially relevant to the review. Methodological shortcomings were highlighted and the quality of the studies was ranked using the Cochrane Tool for Risk of Bias Assessment.

**Results:** Eleven relevant articles were selected (two Randomized Clinical Trials (RCT), five prospective non-randomized, four retrospective non-randomized), and the risk of bias was moderate for six studies and unclear for the others. The amount of mean intrusion reported was 0.72 mm. Extrusion was the most difficult movement to control (30% of accuracy), followed by rotation. Upper molar distalization revealed the highest predictability (88%) when a bodily movement of at least 1.5 mm was prescribed. A decrease of the Little's Index (mandibular arch: 5 mm; maxillary arch: 4 mm) was observed in aligning arches.

**Conclusions:** CAT aligns and levels the arches; it is effective in controlling anterior intrusion but not anterior extrusion; it is effective in controlling posterior buccolingual inclination but not anterior buccolingual inclination; it is effective in controlling upper molar bodily movements of about 1.5 mm; and it is not effective in controlling rotation of rounded teeth in particular. However, the results of this review should be interpreted with caution because of the number, quality, and heterogeneity of the studies. (*Angle Orthod.* 0000;00:000–000.)

**KEY WORDS:** Orthodontics; Clear aligner therapy; Invisible orthodontics; Invisalign<sup>®</sup>

### INTRODUCTION

In recent years, increasing numbers of adult patients have sought orthodontic treatment<sup>1</sup> and expressed a desire for esthetic and comfortable alternatives to

conventional fixed appliances.<sup>2</sup> The possibility of using clear overlay orthodontic appliances was introduced in 1946, when Kesling<sup>3</sup> devised the concept of using a series of thermoplastic tooth positioners to progressively move misaligned teeth to improved positions. In 1997, Align Technology<sup>®</sup> (Santa Clara, Calif) adapted and incorporated modern technologies to introduce the clear aligner treatment (CAT) as we know it, rendering Kesling's concept a feasible orthodontic treatment option. Although CAT has been cited as a safe, esthetic, and comfortable orthodontic procedure for adult patients, only a few investigations<sup>4,5</sup> have focused on the predictability of orthodontic tooth movement (OTM). In 2005 Lagravère and Flores-Mir<sup>6</sup> published a review in which only two studies met their inclusion criteria related to Invisalign therapy efficacy. The authors stated that no strong conclusions could be made regarding the treatment effects of this kind of orthodontic treatment. Thus, clinicians who plan to use CAT on their patients have to rely on their clinical

<sup>a</sup> Resident, Department of Orthodontics, Dental School, University of Turin, Turin, Italy.

<sup>b</sup> Visiting Professor, Department of Orthodontics, Dental School, University of Turin, Turin, Italy.

<sup>c</sup> Adjunct Professor, Department of Orthodontics, Dental School, University of Turin, Turin, Italy.

<sup>d</sup> Professor and Department Chairman, Department of Orthodontics, Dental School, University of Turin, Turin, Italy.

Corresponding author: Dr Gabriele Rossini, Orthodontic Resident, Department of Orthodontics, Dental School, University of Turin, Via Nizza 230, Turin, Italy  
(e-mail: dr.gabriele.rossini@gmail.com)

Accepted: September 2014. Submitted: June 2014.

Published Online: November 20, 2014

© 0000 by The EH Angle Education and Research Foundation, Inc.



## Comparative time efficiency of aligner therapy and conventional edgewise braces

Peter H. Buschang<sup>a</sup>; Steven G. Shaw<sup>b</sup>; Mike Ross<sup>b</sup>; Doug Crosby<sup>c</sup>; Phillip M. Campbell<sup>d</sup>

### ABSTRACT

**Objective:** To compare the time efficiency of aligner therapy (ALT) and conventional edgewise braces (CEB) based on large samples of patients treated by the same highly experienced orthodontist, with the same treatment goals for both groups of patients.

**Materials and Methods:** The retrospective portion of the study evaluated 150 CEB patients who were matched, based on mandibular crowding and number of rotated teeth, to 150 ALT patients. All records were obtained at one orthodontist's office. All of the patients had mild-to-moderate Class I malocclusions ( $\leq 5$  mm incisor crowding) and were treated nonextraction. Age, gender, total treatment time, total number of appointments, types of appointments, materials used, mandibular crowding, and number of rotated teeth were recorded from the patients' records. The prospective portion of the study timed the various types of appointments for both treatments with a stopwatch.

**Results:** Compared to ALT, CEB required significantly ( $P < .01$ ) more visits (approximately 4.0), a longer treatment duration (5.5 months), more emergency visits (1.0), greater emergency chair time (7.0 minutes), and greater total chair time (93.4 minutes). However, ALT showed significantly ( $P < .01$ ) greater total material costs and required significantly more total doctor time than CEB ( $P < .01$ ).

**Conclusions:** Whether the greater time efficiency of ALT offsets the greater material costs and doctor time required depends on the experience of the orthodontist and the number of ALT case starts. (*Angle Orthod.* 2014;84:391–396.)

**KEY WORDS:** Efficiency; Aligner therapy; Chair time; Doctor time

### INTRODUCTION

Time efficiency is an important outcome measure for private practice orthodontists because it often determines the type of treatment modality that is used. For example, self-ligating brackets have been shown to be more efficient than conventional edgewise brackets in terms of total chair time and treatment duration.<sup>1–4</sup>

For the orthodontist, it is just as important to base treatment efficiency on total doctor time, total chair time, and material costs.

In 1999, Align Technology introduced a new form of treatment, which consists of a series of computer-generated, clear, and removable aligners.<sup>5</sup> Esthetics has been shown to be the major concern of patients who elect to undergo the clear aligner treatment (ALT).<sup>6</sup> Other benefits include the ability to remove the aligners to eat, the enhanced ability to brush and floss, and treatment that does not involve metal that can irritate the cheeks and gums.<sup>7</sup> The total number of appointments required for ALT cases, the percentages of patients requiring midcourse corrections, and the number of patients requiring fixed appliances all depend on the pretreatment complexity of the treatments.<sup>8</sup>

It is presently unclear how—in terms of treatment efficiency—ALT compares to conventional edgewise braces (CEB) treatment. The present study was designed to evaluate ALT and CEB based on patients treated by one highly experienced orthodontist, who had the same objectives for all patients. The study goes beyond previous evaluations of efficiency by (1)

<sup>a</sup> Regent's Professor and Director of Orthodontic Research, Department of Orthodontics, Baylor College of Dentistry, Texas A&M Health Science Center, Dallas, Tex.

<sup>b</sup> Dental student, Texas A&M Baylor College of Dentistry, Dallas, Tex.

<sup>c</sup> Private practice, Dallas, Tex.

<sup>d</sup> Associate Professor and Chairman, Department of Orthodontics, Texas A&M Baylor College of Dentistry, Dallas, Tex.

Corresponding author: Dr Peter H. Buschang, Department of Orthodontics, Baylor College of Dentistry, 3302 Gaston Ave, Dallas, TX 75246

(e-mail: phbuschang@bcd.tamhsc.edu)

Accepted: October 2013. Submitted: June 2013.

Published Online: November 18, 2013

© 2014 by The EH Angle Education and Research Foundation, Inc.



# Evaluation of Invisalign treatment effectiveness and efficiency compared with conventional fixed appliances using the Peer Assessment Rating index

Jiafeng Gu,<sup>a</sup> Jack Shengyu Tang,<sup>b</sup> Brennan Skulski,<sup>c</sup> Henry W. Fields, Jr,<sup>a</sup> F. Michael Beck,<sup>d</sup> Allen R. Firestone,<sup>a</sup> Do-Gyoon Kim,<sup>a</sup> and Toru Deguchi<sup>a</sup>

Columbus and Mason, Ohio

**Introduction:** The purpose of this retrospective case-control study was to compare the treatment effectiveness and efficiency of the Invisalign system with conventional fixed appliances in treating orthodontic patients with mild to moderate malocclusion in a graduate orthodontic clinic. **Methods:** Using the peer assessment rating (PAR) index, we evaluated pretreatment and posttreatment records of 48 Invisalign patients and 48 fixed appliances patients. The 2 groups of patients were controlled for general characteristics and initial severity of malocclusion. We analyzed treatment outcome, duration, and improvement between the Invisalign and fixed appliances groups. **Results:** The average pretreatment PAR scores (United Kingdom weighting) were 20.81 for Invisalign and 22.79 for fixed appliances ( $P = 1.0000$ ). Posttreatment weighted PAR scores between Invisalign and fixed appliances were not statistically different ( $P = 0.7420$ ). On average, the Invisalign patients finished 5.7 months faster than did those with fixed appliances ( $P = 0.0040$ ). The weighted PAR score reduction with treatment was not statistically different between the Invisalign and fixed appliances groups ( $P = 0.4573$ ). All patients in both groups had more than a 30% reduction in the PAR scores. Logistic regression analysis indicated that the odds of achieving "great improvement" in the Invisalign group were 0.329 times the odds of achieving "great improvement" in the fixed appliances group after controlling for age ( $P = 0.0150$ ). **Conclusions:** Our data showed that both Invisalign and fixed appliances were able to improve the malocclusion. Invisalign patients finished treatment faster than did those with fixed appliances. However, it appears that Invisalign may not be as effective as fixed appliances in achieving "great improvement" in a malocclusion. This study might help clinicians to determine appropriate patients for Invisalign treatment. (Am J Orthod Dentofacial Orthop 2017;151:259-66)

The Invisalign system, introduced by Align Technology (Santa Clara, Calif) in 1999, involves moving teeth in increments with a series of removable clear polyurethane trays (aligners). Over the past few years, Align Technology has seen significant growth, with

more than 3 million patients treated with Invisalign worldwide.<sup>1</sup> Patients prefer Invisalign treatment over conventional fixed appliances because of its superior esthetics<sup>2</sup> and comfort.<sup>3</sup>

However, in the era of evidence-based dentistry, the scientific evidence on which to choose the treatment of more than 3 million patients is limited. The most recent systematic review of clear aligners only identified 11 relevant scientific articles.<sup>4</sup> Of those, 6 were published more than 5 years ago, and no evidence-based conclusions can be drawn from those studies due to poor quality levels.<sup>4</sup>

Randomized clinical trials have been conducted by a research group to evaluate the effects of aligner material stiffness and activation frequency on Invisalign treatment completion and outcome.<sup>5-7</sup> The authors concluded that patients with a 2-week activation protocol, no extractions, and a low initial Peer Assessment Rating (PAR) score were more likely to complete their initial series of aligners.<sup>5</sup> This study supports Align Technology's 2-week activation time

<sup>a</sup>Division of Orthodontics, College of Dentistry, The Ohio State University, Columbus, Ohio.

<sup>b</sup>Division of Dental Hygiene, College of Dentistry, The Ohio State University, Mason, Ohio.

<sup>c</sup>College of Dentistry, The Ohio State University, Columbus, Ohio.

<sup>d</sup>Division of Oral Biology, College of Dentistry, The Ohio State University, Columbus, Ohio.

All authors have completed and submitted the ICMJE Form for Disclosure of Potential Conflicts of Interest, and none were reported.

Address correspondence to: Toru Deguchi, Ohio State University College of Dentistry, 4088 Postle Hall, 305 W 12th Ave, Columbus, OH 43210; e-mail, [deguchi.4@osu.edu](mailto:deguchi.4@osu.edu).


Submitted, February 2016; revised and accepted, June 2016.

0889-5406/\$36.00

© 2017 by the American Association of Orthodontists. All rights reserved.

<http://dx.doi.org/10.1016/j.ajodo.2016.06.041>

# A systematic review of the accuracy and efficiency of dental movements with Invisalign®

Lidia Galan-Lopez<sup>a,b,c</sup>   
Jorge Barcia-Gonzalez<sup>d</sup>  
Eliseo Plasencia<sup>a,b</sup>

<sup>a</sup>Private Practice, Valencia, Spain

<sup>b</sup>Department of Orthodontics, School of Dentistry and Medicine, Catholic University of Valencia San Vicente Mártir, Valencia, Spain

<sup>c</sup>Doctoral School, Catholic University of Valencia San Vicente Mártir, Valencia, Spain

<sup>d</sup>School of Dentistry and Medicine, Catholic University of Valencia San Vicente Mártir, Valencia, Spain

We are currently living in an era where the use of computer-aided design/computer-aided manufacturing has allowed individualized orthodontic treatments, but has also incorporated enhanced digitalized technology that does not permit improvisation. The purpose of this systematic review was to analyze publications that assessed the accuracy and efficiency of the Invisalign® system. A systematic review was performed using a search strategy to identify articles that referenced Invisalign®, which were published between August 2007 and August 2017, and listed in the following databases: MEDLINE, Embase, Cochrane Library, Web of Knowledge, Google Scholar, and LILACS. Additionally, a manual search of clinical trials was performed in scientific journals and other databases. To rate the methodological quality of the articles, a grading system described by the Swedish Council on Technology Assessment in Health Care was used, in combination with the Cochrane tool for risk of bias assessment. We selected 20 articles that met the inclusion criteria and excluded 5 due to excess biases. The level of evidence was high. Although it is possible to treat malocclusions with plastic systems, the results are not as accurate as those achieved by treatment with fixed appliances.

[Korean J Orthod 2019;49(3):140-149]

**Key words:** Clear aligners, Invisalign®, Invisible orthodontics, Treatment outcomes

Received June 18, 2018; Revised September 20, 2018; Accepted October 5, 2018.

**Corresponding author:** Lidia Galan-Lopez.

Professor, Department of Orthodontics, School of Dentistry and Medicine, Doctoral School, Catholic University of Valencia San Vicente Mártir, C/Quevedo, 2. 46001 Valencia, Spain.

Tel +34-963637412 e-mail lidia.galan@ucv.es

**How to cite this article:** Galan-Lopez L, Barcia-Gonzalez J, Plasencia E. A systematic review of the accuracy and efficiency of dental movements with Invisalign®. Korean J Orthod 2019;49:140-149.

© 2019 The Korean Association of Orthodontists.

This is an Open Access article distributed under the terms of the Creative Commons Attribution Non-Commercial License (<http://creativecommons.org/licenses/by-nc/4.0>) which permits unrestricted non-commercial use, distribution, and reproduction in any medium, provided the original work is properly cited.



# Physical properties of root cementum: Part 10. Comparison of the effects of invisible removable thermoplastic appliances with light and heavy orthodontic forces on premolar cementum. A microcomputed-tomography study

Laura J. Barbagallo,<sup>a</sup> Allan S. Jones,<sup>b</sup> Peter Petocz,<sup>c</sup> and M. Ali Darendeliler<sup>d</sup>

Sydney, Australia

**Introduction:** Orthodontic treatment with clear sequential removable thermoplastic appliances (TAs) is gaining popularity as an alternative to treatment with fixed appliances. The amount of orthodontically induced inflammatory root resorption generated by such appliances has not been investigated. In this prospective randomized clinical trial, we used x-ray microtomography to quantify resorption generated by treatment with ClearSmile appliances (ClearSmile, Woollongong, Australia) and compared the effects with those of heavy and light conventional orthodontic forces and no force. **Methods:** The sample consisted of 54 maxillary first premolars in 27 patients who required bilateral extractions as part of their planned orthodontic treatment. The subjects were randomly assigned to 3 groups, each with 9 subjects. A split-mouth design was used, and forces were applied to the first premolars. In group 1, TAs were used to move teeth on 1 side in a buccal direction at a rate of 0.5 mm every 2 weeks (TA movement); the contralateral teeth were not moved and served as controls. In group 2, TA movement was used on 1 side. A buccal force of 225 g from a beta-titanium alloy cantilever spring (heavy force) was used on the contralateral side. In group 3, TA movement was used on 1 side. A buccal force of 25 g from a cantilever spring (light force) was used on the contralateral side. The treatment duration was 8 weeks (56 days  $\pm$  1 day). The TAs were changed every 14 days, and each patient used 4 appliances. The springs were not reactivated. At the end of the study period, the teeth were extracted according to a strict protocol to prevent root damage. Resorption was measured with an x-ray microtomograph (1072, SkyScan, Aartselaar, Belgium). Software analysis determined quantity, location, and distribution of root resorption craters. **Results:** The control teeth had the least amount of resorption. The light-force teeth had approximately 5 times more resorption than the control teeth ( $P < .001$ ). The TA teeth had similar but slightly greater resorption than the light-force teeth, or approximately 6 times greater than the control teeth ( $P < .001$ ). The heavy-force teeth had the most resorption, about 9 times greater than the controls ( $P < .001$ ). **Conclusions:** Clear removable TAs have similar effects on root cementum as light (25 g) orthodontic forces with fixed appliances. (Am J Orthod Dentofacial Orthop 2008;133:218-27)

**E**xternal surface root resorption can be defined as the active removal of mineralized and nonmineralized cementum and dentin.<sup>1</sup> The types of factors that cause pathologic external root resorption are trauma, infection, and tooth movement.<sup>2,3</sup> Although the outcome of these root resorptive processes is frequently similar, orthodontic root resorption is distinct from the other types. Thus, the

term *orthodontically induced inflammatory root resorption* (OIIRR) has been suggested.<sup>4</sup>

When OIIRR extends beyond the cementum layer into the dentin, it is irreversible.<sup>5</sup> Extensive postorthodontic root resorption compromises the benefits of an otherwise successful orthodontic outcome. Thus, more knowledge is needed about the risk factors associated with new appliances and root resorption.

From the University of Sydney, Sydney, Australia.

<sup>a</sup>Postgraduate student, Discipline of Orthodontics, Faculty of Dentistry.

<sup>b</sup>Senior lecturer, Electron Microscope Unit, University of Sydney, Sydney, Australia.

<sup>c</sup>Honorary associate, Discipline of Orthodontics, Faculty of Dentistry; University of Sydney; statistician, Department of Statistics, Macquarie University, Sydney, Australia.

<sup>d</sup>Professor and chair, Discipline of orthodontics, Faculty of Dentistry.

Reprint requests to: M. Ali Darendeliler, Discipline of Orthodontics, Faculty of Dentistry, University of Sydney, Level 2, 2 Chalmers St, Surry Hills NSW 2010 Australia. e-mail, [adarende@mail.usyd.edu.au](mailto:adarende@mail.usyd.edu.au).

Submitted, August 2005; revised and accepted, January 2006.

0889-5406/\$34.00

Copyright © 2008 by the American Association of Orthodontists.

doi:10.1016/j.ajodo.2006.01.043

## Guest Editorial

# The Clear Plastic Appliance

*A Biomechanical Point of View*

**Naphtali Brezniak**

In the last decade the clear plastic appliance (CPA) treatment received remarkable attention from the orthodontic profession and general practitioners. Different companies emerged and all are using vigorous advertisement to promote their products mainly directly to the patients.<sup>1,2</sup>

Following the first 'treatment experiences' with the CPA, and several published case reports, practitioners realized that bodily movements and extrusions are not accomplished as expected.<sup>3</sup> Therefore, two modifications were implemented in order to improve crown and especially root control; bonded metal or clear attachments and composite attachments.<sup>4</sup>

A force and a moment are needed to move teeth bodily.<sup>5</sup> In the edgewise system, the moment is developed in the bracket itself by full engagement of the wire in the bracket. This engagement in the bracket is a must, since moments are produced by the couple (two equal and opposite forces) resulting from contact of the wire with the opposite walls of the bracket's slot.

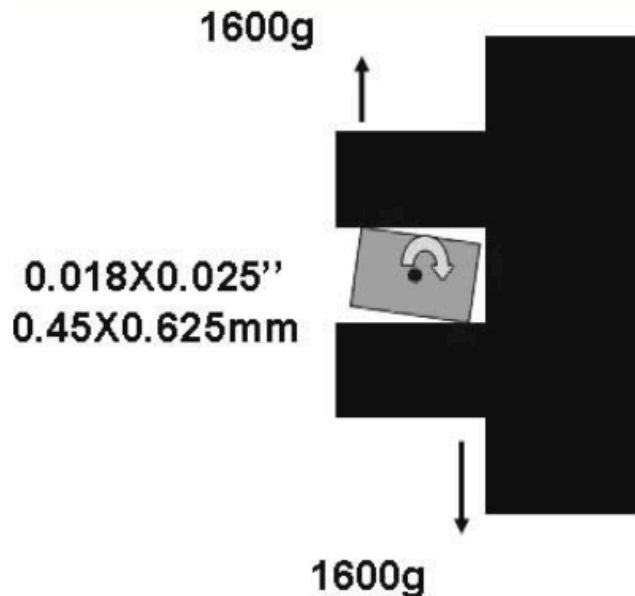
In order to move a central incisor bodily palatally when a 100g of direct force is applied 10 mm away from its center of resistance, a moment of 1000 g-mm is needed. 1600g is needed to develop this moment in the bracket (Figure 1). This number is dramatically increased by hundreds of grams when the distance from the bracket to center of resistance becomes larger as with periodontitis.

Can any CPA, without or with different attachment, produce and deliver such heavy forces in its occlusal and especially in its gingival parts? From careful analyses of the appliance it is apparent that the answer is negative. Even using an attachment cannot change this basic structure and the behavior of the CPA, and cannot change physical laws. Moreover, it is very unlikely that the CPA can deliver hundreds or thousands of grams to the teeth without being distorted. Only the occlusal part of the CPA can deliver relatively heavier forces to the teeth. Those forces can mainly tip the teeth or intrude them.

When the CPA first appeared in the market as a comprehensive treatment option, many orthodontists thought that this clear and esthetic device might be the ideal system since it envelops the whole crown. The index and thumb were used to demonstrate its effect,

but this finger demonstration is deceptive. When the fingers grasp a body, most of the forces exert at the edges of the fingers, not at their base. If we look at the CPA, we understand that most of its force is exerted at the very occlusal part and is rapidly reduced going gingivally.

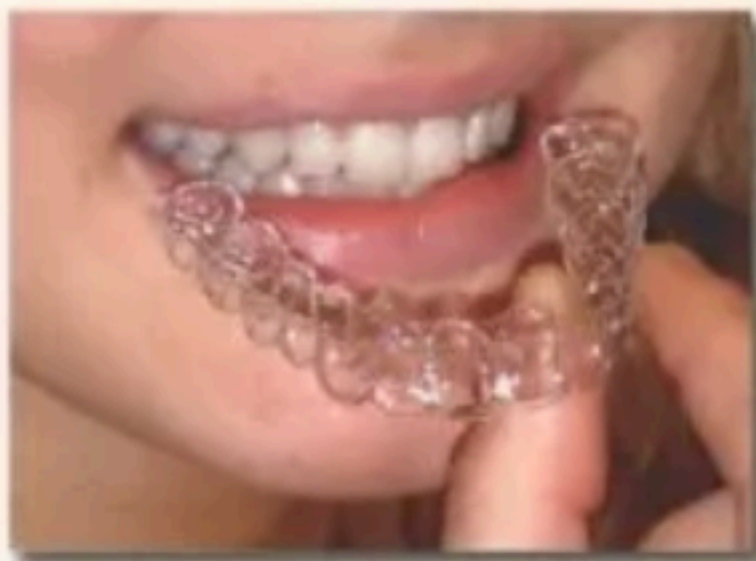
When we place the CPA on the teeth we expect the desired tooth movement to occur. If this does not happen, the CPA surrenders to the stiffer teeth and becomes distorted. Its gingival edges move away from the teeth and no force can be exerted in the gingival area while the force is concentrated only in the occlusal part. This distortion prevents any possible couple to be developed and no bodily movement of the tooth is possible. This occlusal force encourages intrusion. Therefore, it is not uncommon to see teeth that were undesirably intruded using the CPA and it is described as the water melon seed effect. Unfortunately, when



**Figure 1.** The way the forces in each side of the brackets are calculated when the moment developed by the force is 1000 g-mm, 100g of force are placed on a tooth where the center of resistance is 10mm away from the vector on the bracket and has to be counteracted in order to develop bodily movement. The counteracting moment is derived from the couple at the bracket ( $0.625 \text{ mm} \times 1000 \text{ g}$ ).

*Réussir*

Les Traitements Orthodontiques  
**invisalign®**



Richard BOUCHEZ



## Research Article

# Orthodontic Tooth Movement with Clear Aligners

**Carl T. Drake,<sup>1</sup> Susan P. McGorray,<sup>2</sup> Calogero Dolce,<sup>3</sup> Madhu Nair,<sup>4</sup> and Timothy T. Wheeler<sup>3</sup>**

<sup>1</sup> Private Practice 310 Susan Drive, Suite 1, Normal, IL 61761, USA

<sup>2</sup> Department of Biostatistics, University of Florida, Box 117450, FL 32611, USA

<sup>3</sup> Department of Orthodontics, School of Advanced Dental Sciences, College of Dentistry, University of Florida, Gainesville, FL 32610, USA

<sup>4</sup> Department of Oral and Maxillofacial Diagnostic Sciences, College of Dentistry, University of Florida, Gainesville, FL 32610, USA

Correspondence should be addressed to Susan P. McGorray, spmcg@ufl.edu

Received 13 April 2012; Accepted 1 July 2012

Academic Editors: D. J. Manton and G. Perinetti

Copyright © 2012 Carl T. Drake et al. This is an open access article distributed under the Creative Commons Attribution License, which permits unrestricted use, distribution, and reproduction in any medium, provided the original work is properly cited.

Clear aligners provide a convenient model to measure orthodontic tooth movement (OTM). We examined the role of in vivo aligner material fatigue and subject-specific factors in tooth movement. Fifteen subjects seeking orthodontic treatment at the University of Florida were enrolled. Results were compared with data previously collected from 37 subjects enrolled in a similar protocol. Subjects were followed prospectively for eight weeks. An upper central incisor was programmed to move 0.5 mm. every two weeks using clear aligners. A duplicate aligner was provided for the second week of each cycle. Weekly polyvinyl siloxane (PVS) impressions were taken, and digital models were fabricated to measure OTM. Initial and final cone beam computed tomography (CBCT) images were obtained to characterize OTM. Results were compared to data from a similar protocol, where subjects received a new aligner biweekly. No significant difference was found in the amount of OTM between the two groups, with mean total OTM of 1.11 mm. (standard deviation (SD) 0.30) and 1.07 mm. (SD 0.33) for the weekly aligner and biweekly control groups, respectively ( $P = 0.72$ ). Over eight weeks, in two-week intervals, material fatigue does not play a significant role in the rate or amount of tooth movement.

## 1. Introduction

Research of orthodontic tooth movement (OMT) using clear aligners is limited. Most of the literature consists of case reports, editorials, or articles written by authors with biases. There have been few evidence-based attempts to describe the type of OTM resulting from treatment with clear aligners. Conventional thinking suggests that the movement is mostly uncontrolled tipping, with the center of rotation located between the center of resistance and the apex of the tooth. The center of resistance of a single-rooted tooth has been reported to be on the long axis of the tooth between one-third and one-half of the root length apical to the alveolar crest [1].

Clinical trials of aligners have examined the entire course of treatment. Bollen et al. [2] report on the comparisons of two types of material (hard, soft) and two activation frequencies (1 week, 2 week). Fifty-one subjects were randomized to the four groups and evaluated for the primary endpoint: completion of initially prescribed aligner series. More

subjects completed the initial series (37% versus 21%) in the two-week activation group, and no difference due to the fact that material was detected. Clements et al. [3] examined the end-of-study models of the above subjects, focusing on weighted Peer Assessment Ratings (PAR scores), PAR components, average incisor irregularity, and papillary bleeding scores. No significant differences were observed between the four groups. Kravitz et al. [4] reviewed results of 37 patients (401 teeth) treated with clear aligners and compared predicted tooth movement to achieved tooth movement. The mean accuracy over all types of movement was only 41%. Many subjects who begin clear aligner treatment deviate from the programmed progression of aligners and require reevaluation, midcourse correction, and/or use of fixed appliances to achieve treatment goals. A better understanding of the mechanics of tooth movement using aligners could lead to more appropriate selection of patients, better sequencing of tooth movement stages, and more efficient treatment.

# Variables affecting orthodontic tooth movement with clear aligners

Justin R. Chisari,<sup>a</sup> Susan P. McGorray,<sup>b</sup> Madhu Nair,<sup>c</sup> and Timothy T. Wheeler<sup>d</sup>  
West Palm Beach and Gainesville, Fla

**Introduction:** In this study, we examined the impacts of age, sex, root length, bone levels, and bone quality on orthodontic tooth movement. **Methods:** Clear aligners were programmed to move 1 central incisor 1 mm over the course of 8 weeks. Thirty subjects, ages 19 to 64, were enrolled, and measurements were made on digital models (percentage of tooth movement goal achieved). Morphometric features and bone quality were assessed with cone-beam computed tomography. Data from this study were combined with data from 2 similar studies to increase the power for some analyses. **Results:** The mean percentage of tooth movement goal achieved was 57% overall. Linear regression modeling indicated a cubic relationship between age and tooth movement, with a decreasing rate of movement from ages 18 to 35 years, a slightly increasing rate from ages 35 to 50, and a decreasing rate from ages 50 to 70. The final decreasing trend was not apparent for women. As would be expected, the correlation was significant between the percentage of the goal achieved and the cone-beam computed tomography superimposed linear measures of tooth movement. A significant negative correlation was found between tooth movement and the measurement apex to the center of rotation, but bone quality, as measured by fractal dimension, was not correlated with movement. **Conclusions:** The relationship between age and tooth movement is complex and might differ for male and female patients. Limited correlations with cone-beam computed tomography morphology and rate of tooth movement were detected. (Am J Orthod Dentofacial Orthop 2014;145:S82-91)

The use of clear aligners to produce orthodontic tooth movement (OTM) provides an opportunity to measure incremental movement and investigate factors that might affect the rate of movement. The broad principles of OTM are based largely on bone and tissue remodeling, specifically the resorption and deposition of alveolar bone as force is applied. The biology of OTM has proven to be an extremely complex process involving an array of coordinated biochemical reactions, including critical cell signaling pathways and a wide range of cellular differentiation, leading to bone remodeling.<sup>1</sup> As the science of bone biology continues to evolve, several theories of OTM have surfaced. The

pressure-tension theory has emerged as the most popular concept behind the movement of teeth.

Bone remodeling involves an intricate arrangement of coordinated cellular activity leading to bone resorption performed by osteoclasts, followed by bone formation carried out by osteoblasts.<sup>2</sup> Dolce and Holliday<sup>3</sup> have reported that although the precise biologic response to orthodontic force has not been identified, several hypotheses regarding the mechanisms by which osteoblasts and osteocytes sense this initial mechanical stimulus have been proposed, including strain-sensitive ion channels, shear stress receptors, integrin activation, and cytoskeleton reorganization. Three phases of tooth movement have been described in the literature: initial phase, lag phase, and secondary phase.<sup>4,5</sup> The secondary stage accounts for most of the tooth movement, and teeth during this period move at a faster, more continuous pace.<sup>6</sup>

The magnitude and direction of force placed on teeth during OTM, in addition to the length of time these forces are in place, also play critical roles in how teeth move. Forces applied to teeth cause various types of tooth movement depending on the location of the center of resistance of that tooth and the direction in which the force is applied. It is understood that the center of resistance for a given tooth changes based on tooth size,

<sup>a</sup>Private practice, West Palm Beach, Fla.

<sup>b</sup>Assistant professor, Department of Biostatistics, University of Florida, Gainesville.

<sup>c</sup>Chairman and professor, Department of Oral & Maxillofacial Diagnostic Sciences, University of Florida, Gainesville.

<sup>d</sup>Professor, Department of Orthodontics, University of Florida, Gainesville.

All authors have completed and submitted the ICMJE Form for Disclosure of Potential Conflicts of Interest, and none were reported.

Supported by Align Technology, San Jose, Calif, and the Southern Association of Orthodontists.

Address correspondence to: Susan P. McGorray, Department of Biostatistics, Box 117450, Gainesville, FL 32611; e-mail, [spmcg@ufl.edu](mailto:spmcg@ufl.edu).

Submitted, June 2012; revised and accepted, October 2013.

0889-5406/\$36.00

Copyright © 2014 by the American Association of Orthodontists.

<http://dx.doi.org/10.1016/j.ajodo.2013.10.022>




REVIEW

Open Access



# Clinical effectiveness of Invisalign® orthodontic treatment: a systematic review

Aikaterini Papadimitriou<sup>1</sup>, Sophia Mousoulea<sup>2</sup>, Nikolaos Gkantidis<sup>3</sup> and Dimitrios Kloukos<sup>1,3\*</sup> 

## Abstract

**Background:** Aim was to systematically search the literature and assess the available evidence regarding the clinical effectiveness of the Invisalign® system.

**Methods:** Electronic database searches of published and unpublished literature were performed. The reference lists of all eligible articles were examined for additional studies. Reporting of this review was based on the Preferred Reporting Items for Systematic Reviews and Meta-Analyses (PRISMA) guidelines.

**Results:** Three RCTs, 8 prospective, and 11 retrospective studies were included. In general, the level of evidence was moderate and the risk of bias ranged from low to high, given the low risk of bias in included RCTs and the moderate ( $n = 13$ ) or high ( $n = 6$ ) risk of the other studies. The lack of standardized protocols and the high amount of clinical and methodological heterogeneity across the studies precluded a valid interpretation of the actual results through pooled estimates. However, there was substantial consistency among studies that the Invisalign® system is a viable alternative to conventional orthodontic therapy in the correction of mild to moderate malocclusions in non-growing patients that do not require extraction. Moreover, Invisalign® aligners can predictably level, tip, and derotate teeth (except for cuspids and premolars). On the other hand, limited efficacy was identified in arch expansion through bodily tooth movement, extraction space closure, corrections of occlusal contacts, and larger antero-posterior and vertical discrepancies.

**Conclusions:** Although this review included a considerable number of studies, no clear clinical recommendations can be made, based on solid scientific evidence, apart from non-extraction treatment of mild to moderate malocclusions in non-growing patients. Results should be interpreted with caution due to the high heterogeneity.

**Keywords:** Orthodontics, Invisalign, Aligner, Clinical efficiency

## Background

Orthodontic developments, especially during the last years, have been accompanied by a significant increase in the esthetic demands of the patients. Patients often express the need to influence, or even determine, treatment aspects or objectives, along with the orthodontist, driven by the effects that orthodontic appliances have in their appearance. Conventional orthodontic methods have been associated with a general compromise in facial appearance [1] raising a major concern among patients seeking orthodontic treatment [2]. Thus, esthetic

materials and techniques have been introduced in clinical practice aiming to overcome these limitations [3].

Since its development in 1997, Invisalign® technology has been established worldwide as an esthetic alternative to labial fixed appliances [4–7]. CAD/CAM stereolithographic technology has been used to forecast treatment outcomes and fabricate a series of custom-made aligners using a single silicone or digital impression [6]. After its introduction, the system has been drastically developed and continually improved in many aspects; different attachment designs, new materials, and new auxiliaries, such as “Precision Cuts” and “Power Ridges” were designed to enable additional treatment biomechanics. According to the manufacturer, Invisalign® can effectively perform major tooth movements, such as bicuspid derotation up to 50° and root movements of upper central incisors up to 4 mm [8]. Despite the advocated

\* Correspondence: [dimitrios.kloukos@zmk.unibe.ch](mailto:dimitrios.kloukos@zmk.unibe.ch)

<sup>1</sup>Department of Orthodontics and Dentofacial Orthopedics, 251 Hellenic Air Force General Hospital, P. Kanellopoulou 3, 11525 Athens, Greece

<sup>3</sup>Department of Orthodontics and Dentofacial Orthopedics, University of Bern, Freiburgstrasse 7, CH-3010 Bern, Switzerland

Full list of author information is available at the end of the article

## **Influence of Attachments and Interproximal Reduction on the Accuracy of Canine Rotation with Invisalign**

*A Prospective Clinical Study*

**Neal D. Kravitz<sup>a</sup>; Budi Kusnoto<sup>b</sup>; Brent Agran<sup>c</sup>; Grace Viana<sup>d</sup>**

### **ABSTRACT**

**Objective:** To evaluate the influence of attachments and interproximal reduction on canines undergoing rotational movement with Invisalign.

**Materials and Methods:** In this prospective clinical study, 53 canines (33 maxillary and 20 mandibular) were measured from the virtual TREAT models of 31 participants treated with anterior Invisalign. The pretreatment virtual model of the predicted final tooth position was superimposed on the posttreatment virtual model using ToothMeasure, Invisalign's proprietary measurement software. A one-way analysis of variance (ANOVA) ( $P < .05$ ) compared three treatment modalities: attachments only (AO), interproximal reduction only (IO), and neither attachments nor interproximal reduction (N). Student's *t*-tests ( $P < .05$ ) compared the mean accuracy of canine rotation between arches.

**Results:** The mean accuracy of canine rotation with Invisalign was 35.8% (SD = 26.3). Statistical analyses indicated that there was no significant difference in accuracy between groups AO, IO, and N ( $P = .343$ ). There was no statistically significant difference ( $P = .888$ ) in rotational accuracy for maxillary and mandibular canines for any of the treatment groups. The most commonly prescribed attachment shape was the vertical-ellipsoid (70.5%).

**Conclusions:** Vertical-ellipsoid attachments and interproximal reduction do not significantly improve the accuracy of canine rotation with the Invisalign system.

**KEY WORDS:** Invisalign; Accuracy; Superimposition; Attachments; Interproximal reduction

### **INTRODUCTION**

Since its advent nearly a decade ago, Invisalign has grown rapidly in worldwide consumer demand and professional use leading to a paradigm shift in patient marketing and orthodontic treatment. Despite its growing popularity, questions remain regarding the limitations and proper use of this system. In particular, many clinicians have reported difficulty correcting rotations

with Invisalign, especially canines and premolars. A randomized survey study by Sheridan<sup>1</sup> reported that "uncorrected rotations" was one of the most prevalent problems encountered by orthodontists using Invisalign, often resulting in the need for refinement impressions or conversion to fixed appliances.

The derotation of cylindrical teeth presents a biomechanical challenge due to the lack of interproximal undercuts causing the aligner to slip as it attempts to rotate the tooth.<sup>2</sup> Align Technology Inc recommends the use of resin attachments, interproximal reduction, thermopliers, overcorrection or auxiliaries to aid rotational movement.<sup>3</sup> However, it remains the responsibility of the clinician to accurately diagnose difficult movement and prescribe treatment within the limitations of the aligner material.

An internal study by Nguyen and Cheng<sup>2</sup> first evaluated the performance of aligners for canine and premolar rotations by superimposing virtual models with ToothMeasure, Align's propriety superimposition software. The results of their study revealed that the overall accuracy of canine and premolar rotation was only

<sup>a</sup> Private practice in orthodontics, Chantilly, Va.

<sup>b</sup> Assistant Professor and Clinical Chair, Department of Orthodontics, University of Illinois at Chicago, Chicago, Ill.

<sup>c</sup> Research Assistant, Department of Orthodontics, School of Dentistry, University of Illinois at Chicago, Chicago, Ill.

<sup>d</sup> Statistician, Department of Orthodontics, University of Illinois at Chicago, Chicago, Ill.

Corresponding author: Dr Neal D. Kravitz, Department of Orthodontics, University of Illinois at Chicago, 801 S Paulina Street, MC 841, Chicago, IL 60612 (e-mail: nealkravitz@gmail.com)

Accepted: August 2007. Submitted: June 2007.

© 2008 by The EH Angle Education and Research Foundation, Inc.



# Periodontal health status in patients treated with the Invisalign® system and fixed orthodontic appliances: A 3 months clinical and microbiological evaluation

Luca Levrini<sup>1</sup>, Alessandro Mangano<sup>2</sup>, Paola Montanari<sup>1</sup>, Silvia Margherini<sup>1</sup>,  
Alberto Caprioglio<sup>1</sup>, Gian Marco Abbate<sup>1</sup>

**Correspondence:** Dr. Luca Levrini  
Email: luca.levrini@uninsubria.it

<sup>1</sup>Department of Morphological and Surgical Sciences, University of Insubria, Varese, Italy,  
<sup>2</sup>Oro Cranio Facial Disease and Medicine Research Centre, University of Insubria, Varese, Italy

## ABSTRACT

**Objective:** The aim of this prospective study was to compare the periodontal health and the microbiological changes via real-time polymerase chain reaction (PCR) in patients treated with fixed orthodontic appliances and Invisalign® system (Align Technology, Santa Clara, California). **Materials and Methods:** Seventy-seven patients were enrolled in this study and divided into three groups (Invisalign® group, fixed orthodontic appliances group and control group). Plaque index, probing depth, bleeding on probing were assessed. Total biofilm mass and periodontal pathogens were analyzed and detected via real-time PCR. All these data were analyzed at the T0 (beginning of the treatment) T1 (1-month) and T2 (3 months); and statistically compared using the Mann–Whitney test for independent groups. **Results:** After 1-month and after 3 months of treatment there was only one sample with periodontopathic anaerobes found in patient treated using fixed orthodontic appliances. The Invisalign® group showed better results in terms of periodontal health and total biofilm mass compared to the fixed orthodontic appliance group. A statistical significant difference ( $P < 0.05$ ) at the T2 in the total biofilm mass was found between the two groups. **Conclusion:** Patients undergoing orthodontic treatment with the Invisalign® System show a superior periodontal health in the short-term when compared to patients in treatment with fixed orthodontic appliances. Invisalign® should be considered as a first treatment option in patients with risk of developing periodontal disease.

**Key words:** Clear aligners, fixed orthodontic treatment, Invisalign, microbiological evaluation, periodontal health

## INTRODUCTION

Treatment with fixed orthodontic devices such as brackets and bands creates numerous plaque accumulation sites impeding oral hygiene procedures and thus potentially leading to develop white spot lesions, caries, and periodontitis.<sup>[1,2]</sup>

It is recognized that microbial dental plaque is the main etiologic factor in the development of dental caries and periodontal disease.<sup>[3]</sup>

Plaque accumulation can favor the transition of the microbial biofilm to a more aggressive periodontopathogenic flora in subgingival periodontal pockets and the production of proinflammatory cytokines.<sup>[4,5]</sup>

During fixed orthodontic treatment inflammation occurs and pathologic phenomena such as gingivitis, gingival bleeding, gingival enlargement, and increased gingival pocket depth are observed.<sup>[6]</sup>

This is an open access article distributed under the terms of the Creative Commons Attribution-NonCommercial-ShareAlike 3.0 License, which allows others to remix, tweak, and build upon the work non-commercially, as long as the author is credited and the new creations are licensed under the identical terms.

**For reprints contact:** reprints@medknow.com

**How to cite this article:** Levrini L, Mangano A, Montanari P, Margherini S, Caprioglio A, Abbate GM. Periodontal health status in patients treated with the Invisalign® system and fixed orthodontic appliances: A 3 months clinical and microbiological evaluation. Eur J Dent 2015;9:404-10.

**DOI:** 10.4103/1305-7456.163218

## Systematic Review

# Periodontal health during clear aligners treatment: a systematic review

Gabriele Rossini, Simone Parrini, Tommaso Castroflorio, Andrea Deregibus and Cesare L. Debemardi

Department of Orthodontics, Dental School, University of Turin, Italy

Correspondence to: Gabriele Rossini, Department of Orthodontics, Dental School, University of Turin, Via Nizza 230, Turin 10125, Italy. E-mail: [dr.gabriele.rossini@gmail.com](mailto:dr.gabriele.rossini@gmail.com)

### Summary

**Background:** Clear aligner treatment (CAT) has been cited as a safe and comfortable orthodontic procedure for adult patients. However, the available evidence is scarce.

**Objective:** To perform a systematic review of the existing literature in order to assess periodontal health during CAT.

**Search methods and selection criteria:** Pubmed, Pubmed Central, National Library of Medicine's Medline, Embase, Cochrane Central Register of Controlled Clinical trials, Web of Knowledge, Scopus, Google Scholar, and LILACS were searched from January 1945 to September 2014 to identify all peer-reviewed papers potentially relevant to the review.

**Data collection and analysis:** After duplicate selection and extraction procedures, the risk of bias was assessed according to the Centre for Reviews and Dissemination criteria, and a 3-point grading system, as described by the Swedish Council on Technology Assessment in Health Care (SBU), was used to rate the methodological quality of the selected papers. A PICOS table was used for data extraction.

**Results:** Five relevant articles were selected from the 1247 identified articles. The level of evidence was moderate for all the studies. A significant improvement of the periodontal health indexes was revealed, in particular when CAT was compared to fixed appliances. No periodontal CAT adverse effects were observed in the selected studies.

**Conclusions:** Periodontal health indexes were significantly improved during CAT. The results of this review should be interpreted with some caution because of the number, quality, and heterogeneity of the included studies.

### Introduction

Direct or indirect effects of orthodontic treatments on periodontal status and oral health are well known and quite extensively described in the existing literature (1). The periodontal reaction to an orthodontic appliance depends on several factors, such as host resistance, the presence of systemic conditions, and the amount and composition of dental plaque. Lifestyle factors, including smoking, can also compromise periodontal support. Oral hygiene procedures have a great impact on the periodontal health during orthodontic treatment (2). The existing literature supports the link between the increase

of plaque indexes (PIs) and the decrease in overall oral health conditions in orthodontic patients, especially when treated with fixed appliances (3–6). The use of removable appliances can minimize the orthodontics-related negative effects on periodontal health allowing patients easier oral hygiene procedures.

In recent years, increasing numbers of adult patients have sought orthodontic treatment and expressed a desire for aesthetic and comfortable alternatives to conventional fixed appliances (7, 8).

Clear aligners treatment (CAT) was introduced to answer this requests. Although CAT has been cited as a safe, aesthetic and comfortable orthodontic procedure for adult patients, only few trials

# Consequences of Poor Oral Hygiene During Clear Aligner Therapy

MAZYAR MOSHIRI, DMD, MS  
JAMES E. ECKHART, DDS  
PATRICK MCSHANE, DMD  
DANIEL S. GERMAN, DDS

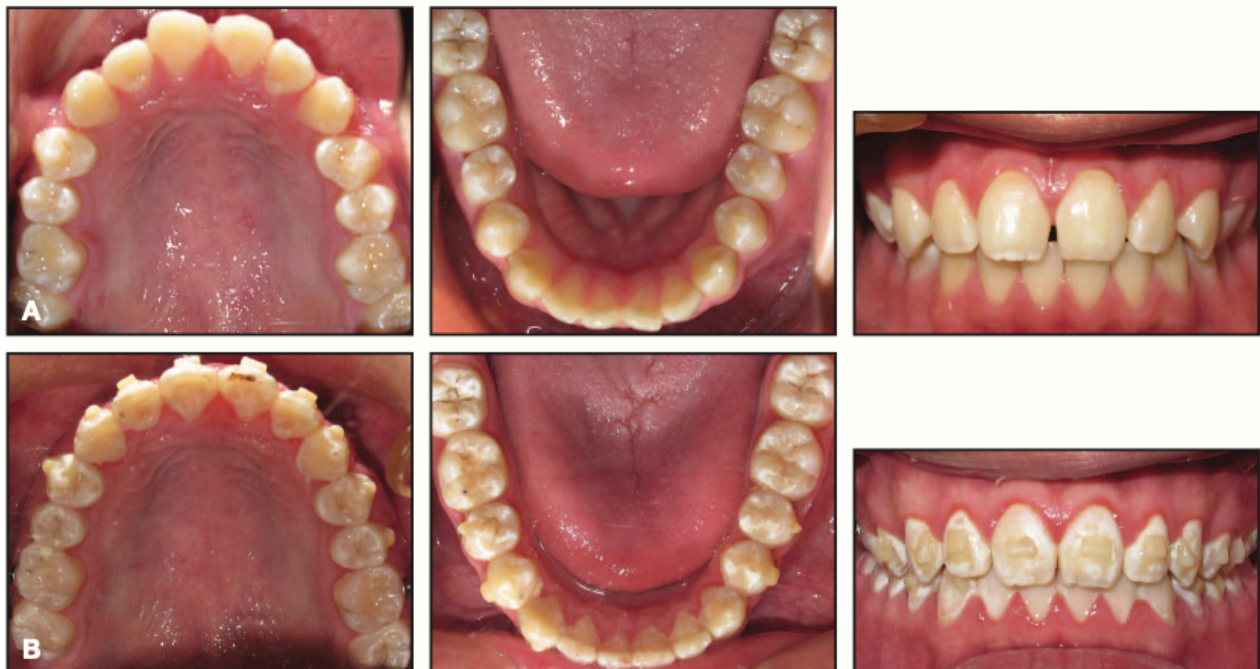
**W**hile the use of clear aligners has become increasingly common in orthodontic therapy, information regarding decalcification or caries in patients undergoing aligner therapy has not been widely disseminated. Although the general assumption is that these appliances are hygienic by design, perhaps it is an assumption that needs to be questioned.

Invisalign\* and other clear aligner trays are usually prescribed to be worn about 22 hours per day for optimal results. A plastic aligner or vacuum-formed retainer is a protective environment that

limits the flow of saliva, negating saliva's natural cleansing, buffering, and remineralizing properties. Additionally, the usual cleansing activities of the lips, cheeks, and tongue are interrupted, allowing further entrapment and development of plaque under the appliances.

Most patients will drink liquids without removing their aligners, providing the opportunity for pooling of these liquids beneath the trays. This

\*Registered trademark of Align Technology, Inc., San Jose, CA; www.invisalign.com.



**Fig. 1** Case 1. **A.** 14-year-old male patient during aligner therapy. **B.** Significant decalcification observed around bonded attachments, upper incisal edges, and lower first-molar cusp tips after 10 weeks without oral hygiene.




RESEARCH

Open Access



# Root resorption during orthodontic treatment with Invisalign®: a radiometric study

Giulia Gay<sup>1</sup>, Serena Ravera<sup>1\*</sup> , Tommaso Castroflorio<sup>1</sup>, Francesco Garino<sup>1</sup>, Gabriele Rossini<sup>1</sup>, Simone Parrini<sup>1</sup>, Giovanni Cugliari<sup>2</sup> and Andrea Deregibus<sup>1</sup>

## Abstract

**Background:** Root resorption (RR) is described as a permanent loss of tooth structure from the root apex. Many reports in the literature indicate that orthodontically treated patients are more likely to have severe apical root shortening, interesting mostly maxillary, followed by mandibular incisors. The aim of the study was to investigate the incidence and severity of RR in adult patients treated with aligners. The study group consisted of 71 class I adult healthy patients (mean age  $32.8 \pm 12.7$ ) treated with aligners (Invisalign®, Align Technologies, Santa Clara, CA, USA). All incisors, canines, upper first premolars, and first molars were assessed. Root and crown lengths of 1083 teeth were measured in panoramic radiographs at the beginning (T0) and at the end (T1) of clear aligner therapy. Individual root-crown ratio (RCR) of each tooth and therefore the relative changes of RCR (rRCR) were determined. A decrease of rRCR was assessed as a reduction of the root length during treatment.

**Results:** All patients had a minimum of one teeth affected with a reduction of root length, on average  $6.38 \pm 2.28$  teeth per patient. Forty one, 81% of the 1083, measured teeth presented a reduction of the pre-treatment root length. A reduction in percentage of >0% up to 10% was found in 25.94% ( $n = 281$ ), a distinct reduction of >10% up to 20% in 12.18% ( $n = 132$ ) of the sample. 3.69% ( $n = 40$ ) of the teeth were affected with a considerable reduction (>20%).

**Conclusions:** Orthodontic treatment with Invisalign® aligners could lead to RR. However, its incidence resulted to be very similar to that described for orthodontic light forces, with an average percentage of RR < 10% of the original root length.

**Keywords:** Adult patients, Aligners, Root resorption

## Background

Root resorption (RR) is a permanent loss of tooth structure from the root apex [1]. Its clinical outcomes in orthodontic patients are highly variable and depend on genetic predisposition, individual biologic variability, and mechanical factors [2]. Several authors demonstrated that RR occurs even without orthodontic treatment [3–6], but patients who underwent orthodontic treatment are more likely to show severe apical root shortening [7].

In histological studies, orthodontically moved teeth show an occurrence of RR greater than 90% [8–10]. Lower

percentages are reported for diagnostic radiographic techniques. The average amount of tissue loss is less than 2.5 mm [11–14] or varies from 6 to 13% for different teeth [15] in radiographic studies.

RR is usually classified as minor or moderate in most orthodontic patients. Severe resorption, if exceeding 4 mm or one-third of the original root length, is seen in 1–5% of teeth<sup>7</sup> [16–18].

Root resorption has two phases: during the first phase, the damage of the external surface of the root causes the exposition of denuded mineralized tissue, while in the second one, multinucleated cells are stimulated to colonize the denuded mineralized tissue, getting to a resorption process [19]. Without any

\* Correspondence: serenaravera@gmail.com

<sup>1</sup>Department of Surgical Sciences, University of Torino, Turin, Italy  
Full list of author information is available at the end of the article





## Association of Orthodontic Clear Aligners with Root Resorption Using Three-dimension Measurements: A Systematic Review

<sup>1</sup>Arwa Aldeeri, <sup>1</sup>Lulu Alhammad, <sup>1</sup>Amjad Alduham, <sup>1</sup>Waad Ghassan, <sup>2</sup>Sanaa Shafshak, <sup>3</sup>Eman Fatani

### ABSTRACT

**Aim:** This paper aims to assess the evidence in the literature reporting orthodontically induced inflammatory root resorption (OIIRR) in treatment with orthodontic clear aligners using 3D measurements.

**Materials and methods:** Following preferred reporting items for systematic reviews (PRISMA) statement, eight electronic databases were searched for relevant published and unpublished records. Data collected according to restricted inclusion and exclusion criteria.

**Results:** A total of 236 articles were identified as relevant to our topic. Duplicates were excluded resulting in 226 papers, out of which 31 papers were relevant after screening titles and abstracts. Only 2 high-level evidence papers out of the 31 met the inclusion criteria for the qualitative synthesis.

**Conclusion:** Based on the available studies with high level of evidence in the literature, we conclude that orthodontic clear aligners are non-inferior to light-force fixed orthodontic appliances, and superior to heavy-force fixed orthodontic appliances in terms of the risk for developing apical root resorption.

**Clinical significance:** Orthodontists can be more assured about the low-risk of OIIRR associated with clear aligners compared to other orthodontic treatment modalities, and it remains up to the practitioner's assessment to select the appropriate treatment on a case by case basis.

**Keywords:** Aligners, Orthodontic appliances, Removable, Root resorption, Systematic review.

**How to cite this article:** Aldeeri A, Alhammad L, Alduham A, Ghassan W, Shafshak S, Fatani E. Association of Orthodontic Clear Aligners with Root Resorption Using Three-dimension Measurements: A Systematic Review. *J Contemp Dent Pract* 2018;19(12):1559-1565.

**Source of support:** Nil

**Conflict of interest:** None

### INTRODUCTION

External apical root resorption (ARR) is defined as the permanent loss of the apical part of the root structure.<sup>1</sup> It is multifactorial in etiology, with pulpal and periodontal infection and pressure from tumors in the jaws being stimulating factors.<sup>2</sup> It is also an unwanted consequence to orthodontic treatment, where it is called orthodontically induced inflammatory root resorption (OIIRR).<sup>2,3</sup> Local inflammatory response induced by the application of orthodontic forces is crucial for tooth movement. However, this inflammation is the basis for OIIRR.<sup>4</sup> For decades, this topic has been a fertile soil of research in the field of a fixed orthodontic appliance.<sup>5-8</sup> In 1994, Hendrix et al. showed, using orthopantograms, that OIIRR was not different across genders, age groups, extraction *vs.* non-extraction technique and different durations of active treatment.<sup>5</sup> In 2012 Lund et al. showed similar findings using cone beam computed tomography (CBCT).<sup>7</sup> Other studies on OIIRR were conducted as more orthodontic systems and techniques were developed.<sup>7,9,10</sup> In 2000, Janson et al. compared three conventional orthodontic techniques of which bio-efficient therapy was associated with less root resorption compared to simplified standard edgewise technique and edgewise straight wire system.<sup>6</sup> Another study showed no difference between self-ligating and conventional brackets systems.<sup>8</sup> There is compelling evidence that root resorption is worse in fixed orthodontic

<sup>1</sup>College of Dentistry, Riyadh Elm University, Riyadh, Kingdom of Saudi Arabia

<sup>2</sup>College of Dentistry, Preventive Department, Division of Periodontics, Riyadh Elm University, Riyadh, Kingdom of Saudi Arabia

<sup>3</sup>College of Dentistry, Preventive Department, Division of Orthodontics, Riyadh Elm University, Riyadh, Kingdom of Saudi Arabia

**Corresponding Author:** Arwa Aldeeri, College of Dentistry, Riyadh Elm University, Riyadh, Kingdom of Saudi Arabia, e-mail: arwaaldeeri@gmail.com.

Access this article online

Quick Response Code:



Website:

www.jorthodsci.org

DOI:

10.4103/jos.JOS\_120\_17

# Evaluation of root length following treatment with clear aligners and two different fixed orthodontic appliances. A pilot study

Osama Eissa, Terry Carlyle<sup>1</sup> and Tarek El-Bialy<sup>2</sup>

## Abstract:

**OBJECTIVES:** The purpose of this pilot study was to evaluate the root lengths of upper incisors as an indication of the degree of orthodontically-induced apical root resorption following treatment with Smart Track® aligners and compare it with two different fixed orthodontic appliances – regular and Damon brackets – using cone-beam computerized tomography (CBCT).

**MATERIALS AND METHODS:** The sample comprised 33 patients with class I malocclusion and 4–6 mm crowding divided in 3 groups; Group I: 11 patients treated with Smart Track® aligners, group II: 11 patients treated with Damon brackets, and group III: 11 patients with regular brackets. Maxillary incisors teeth lengths were assessed using Dolphin imaging software before and after treatment. All data were analyzed using analysis of variance and *t*-test.

**RESULTS:** All groups showed statistically significant root resorption, 0–1.4 mm for clear aligners, 0.1–2.3 mm for Damon, and 0–2.5 mm for regular brackets group. However, cases treated with fixed appliance in general showed significantly higher resorption than those treated with Smart Track® aligners ( $P < 0.05$ ).

**CONCLUSION:** Orthodontically-induced root resorption, as evaluated by root length, is an inevitable drawback with different orthodontic techniques. However, the use of Smart Track® aligners showed less root resorption relative to regular fixed appliances.

## Keywords:

Apical root resorption, clear aligner, self-ligating brackets

## Introduction

Orthodontically-induced root resorption is one of the common undesirable sequelae of orthodontic treatment. Literature has shown that most orthodontically-treated patients experience variable degrees of root resorption. The incidence of root resorption during orthodontic treatment varies widely among investigators.<sup>[1]</sup> In a study by Taithongchai *et al.*,<sup>[2]</sup> one-third of the patients treated with fixed appliances showed more than 3 mm of root resorption

whereas at least 2% of orthodontic patients showed more than 5 mm of root resorption.

Orthodontically-induced root resorption can affect any tooth in the oral cavity. However, the maxillary central and lateral incisors are considered the most susceptible to resorption.<sup>[3]</sup>

The exact mechanism of orthodontically-induced root resorption is not clearly understood. However, this phenomenon presents with multifactorial etiology. Several biological, mechanical, and clinical factors were considered for root resorption following orthodontic treatment.<sup>[4]</sup> Biomechanically,

This is an open access journal, and articles are distributed under the terms of the Creative Commons Attribution-NonCommercial-ShareAlike 4.0 License, which allows others to remix, tweak, and build upon the work non-commercially, as long as appropriate credit is given and the new creations are licensed under the identical terms.

For reprints contact: reprints@medknow.com

**How to cite this article:** Eissa O, Carlyle T, El-Bialy T. Evaluation of root length following treatment with clear aligners and two different fixed orthodontic appliances. A pilot study. *J Orthodont Sci* 2018;7:11.

Department of  
Orthodontics, Faculty of  
Dentistry, Tanta University,  
Egypt, <sup>1</sup>Clinical Professor,  
Graduate Orthodontic  
Program, <sup>2</sup>Department  
of Orthodontics, School  
of Dentistry, University of  
Alberta, Canada

## Address for correspondence:

Dr. Osama Eissa,  
Department of  
Orthodontics, Faculty of  
Dentistry, Tanta University,  
Egypt.  
E-mail: oeissa@ualberta.  
ca



RESEARCH

Open Access



# Prevalence and severity of apical root resorption during orthodontic treatment with clear aligners and fixed appliances: a cone beam computed tomography study

Yuan Li<sup>1†</sup>, Shiyong Deng<sup>1†</sup>, Li Mei<sup>2</sup>, Zhengzheng Li<sup>1</sup>, Xinyun Zhang<sup>1</sup>, Chao Yang<sup>3</sup> and Yu Li<sup>1\*</sup> 

## Abstract

**Background:** Fixed appliances have been the mainstream for orthodontic treatment, while clear aligners, such as Invisalign system, have become increasingly popular. The prevalence of apical root resorption (ARR) in patients with clear aligners is still controversial. The aim of this study was to investigate and compare the prevalence and severity of ARR in patients treated with clear aligners and fixed appliances using cone beam computed tomography (CBCT).

**Materials and methods:** A total of 373 roots from 70 subjects, with similar baseline characteristics and the ABO discrepancy index scores (i.e., treatment difficulty), were included into two groups: the clear aligners group (Invisalign, Align Technology, California, USA) and fixed appliances group (Victory Series; 3 M Unitek, California, USA). Root length of each anterior tooth was measured on the CBCT images by two blinded investigators. The ARR on each tooth was calculated as the difference of root length before and after orthodontic treatment. Chi-square test and paired t test was used to compare the ARR between the two groups as well as before and after orthodontic treatments.

**Results:** Prevalence of ARR in the clear aligners group (56.30%) was significantly lower than that in the fixed appliances group (82.11%) ( $P < 0.001$ ). The severity of ARR in the clear aligners group ( $0.13 \pm 0.47$  mm) was significantly less than that in the fixed appliances group ( $1.12 \pm 1.34$  mm) ( $P < 0.001$ ). The most severe ARR was found on the maxillary canine ( $1.53 \pm 1.92$  mm) and lateral incisor ( $1.31 \pm 1.33$  mm) in the fixed appliances group; the least ARR was found on the mandibular canine ( $-0.06 \pm 0.47$  mm) and lateral incisor ( $0.04 \pm 0.48$  mm) in the clear aligners group ( $P < 0.001$ ).

**Conclusions:** The prevalence and severity of ARR measured on CBCT in patients with clear aligners were less than those in patients with fixed appliances.

**Keywords:** Root resorption, Invisalign, Clear aligners, Braces, CBCT

## Background

Apical root resorption (ARR), a permanent loss of hard tissue on the root apex of a tooth, is one of the most undesirable side effects during orthodontic treatment. The prevalence of ARR varies from 20 to 100% among orthodontic patients [1]. Severe ARR is rare with an incidence

between 1 and 5% but the resorption can be more than 5 mm or one-fourth of root length [2]. ARR can cause an imbalanced ratio of crown and root in the affected teeth, and even teeth loss, affecting patients' quality of life and orthodontic treatment result.

Fixed appliances have been the mainstream for orthodontic treatment. Clear aligners, such as Invisalign system, have become increasingly popular due to its advantages, such as esthetics and comfort, in comparison with fixed appliances [3, 4]. It has been found that the type of fixed appliances used for orthodontic treatment was associated

\* Correspondence: [yuli@scu.edu.cn](mailto:yuli@scu.edu.cn)

<sup>†</sup>Yuan Li and Shiyong Deng contributed equally to this work.

<sup>1</sup>State Key Laboratory of Oral Diseases & National Clinical Research Center for Oral Diseases, West China Hospital of Stomatology, Sichuan University, Chengdu, China

Full list of author information is available at the end of the article

## How accurate is Invisalign in nonextraction cases? *Are predicted tooth positions achieved?*

Thorsten Grünheid<sup>a</sup>; Charlene Loh<sup>b</sup>; Brent E. Larson<sup>c</sup>

### ABSTRACT

**Objective:** To evaluate the accuracy of Invisalign technology in achieving predicted tooth positions with respect to tooth type and direction of tooth movement.

**Materials and Methods:** The posttreatment models of 30 patients who had nonextraction Invisalign treatment were digitally superimposed on their corresponding virtual treatment plan models using best-fit surface-based registration. The differences between actual treatment outcome and predicted outcome were computed and tested for statistical significance for each tooth type in mesial-distal, facial-lingual, and occlusal-gingival directions, as well as for tip, torque, and rotation. Differences larger than 0.5 mm for linear measurements and 2° for angular measurements were considered clinically relevant.

**Results:** Statistically significant differences ( $P < .05$ ) between predicted and achieved tooth positions were found for all teeth except maxillary lateral incisors, canines, and first premolars. In general, anterior teeth were positioned more occlusally than predicted, rotation of rounded teeth was incomplete, and movement of posterior teeth in all dimensions was not fully achieved. However, except for excess posttreatment facial crown torque of maxillary second molars, these differences were not large enough to be clinically relevant.

**Conclusions:** Although Invisalign is generally able to achieve predicted tooth positions with high accuracy in nonextraction cases, some of the actual outcomes may differ from the predicted outcomes. Knowledge of dimensions in which the final tooth position is less consistent with the predicted position enables clinicians to build necessary compensations into the virtual treatment plan. (*Angle Orthod.* 2017;87:809–815.)

**KEY WORDS:** Invisalign; aligner; treatment outcome

### INTRODUCTION

In the past two decades, the field of orthodontics has been revolutionized by technological advancements. Three-dimensional imaging has expanded diagnostic and treatment planning abilities,<sup>1</sup> intraoral scanners now provide an alternative to traditional impressions, and digital models can replace plaster models for both

treatment planning and appliance fabrication.<sup>2,3</sup> Combined with increasing patient demand for esthetic treatment options and the drive toward personalized treatment, these developments have given rise to a number of clear aligner systems now serving as alternatives to conventional bracket-and-archwire systems.<sup>4</sup>

In 1999, Align Technology (Santa Clara, Calif) introduced Invisalign as the pioneer clear aligner system for comprehensive orthodontic treatment. Invisalign has continually evolved through the development of new aligner materials, attachments on teeth, staging of tooth movement, and incorporation of interproximal reduction and interarch elastics to address a wider range of malocclusions.<sup>5,6</sup>

According to the company's internal data, more than 3 million patients have been treated with the Invisalign system in more than 90 countries worldwide. Despite its widespread use, relatively few studies have quantified the system's efficacy. This is significant because it has been suggested that aligners have limitations when it

<sup>a</sup> Assistant Professor, Division of Orthodontics, School of Dentistry, University of Minnesota, Minneapolis, Minn.

<sup>b</sup> Private Practice, Richmond, British Columbia, Canada

<sup>c</sup> Professor and Director, Division of Orthodontics, School of Dentistry, University of Minnesota, Minneapolis, Minn.

Corresponding author: Dr Thorsten Grünheid, Division of Orthodontics, School of Dentistry, University of Minnesota, 6-320 Moos Health Science Tower, 515 Delaware Street S.E., Minneapolis, MN 55455 (e-mail: tgruenhe@umn.edu)

Accepted: May 2017. Submitted: February 2017.

Published Online: July 7, 2017

© 2017 by The EH Angle Education and Research Foundation, Inc.



# Accuracy of clear aligners: A retrospective study of patients who needed refinement

Orfeas Charalampakis,<sup>a</sup> Anna Iliadi,<sup>b</sup> Hiroshi Ueno,<sup>a</sup> Donald R. Oliver,<sup>a</sup> and Ki Beom Kim<sup>a</sup>  
St Louis, Mo, and Athens, Greece

**Introduction:** The purpose of this study was to determine the accuracy of specific tooth movements with Invisalign (Align Technology, Santa Clara, Calif). **Methods:** The study sample included 20 Class I adult patients treated with Invisalign; they completed their first series of aligners and had to have a "refinement" series. Initial and predicted models were obtained from the initial ClinCheck (Align Technology). The starting point of the refinement ClinCheck was used to create the achieved models. Predicted and achieved models were superimposed over the initial ones on posterior teeth using the 3-dimensional Image Analysis open-source software Slicer CMF. Three hundred ninety-eight teeth were measured for vertical, horizontal, and rotational movements, and transverse widths were measured. The amount of predicted tooth movement was compared with the achieved amount for each movement. **Results:** Horizontal movements of all incisors seemed to be accurate, with small (0.20-0.25 mm) or insignificant differences between predicted and achieved amounts. Vertical movements and particularly intrusions of maxillary central incisors were found to be less accurate, with a median difference of 1.5 mm ( $P < 0.001$ ). All achieved rotations were significantly smaller than those predicted, with the maxillary canines exhibiting the greatest difference of 3.05° ( $P < 0.001$ ). **Conclusions:** The most inaccurate movements identified in this study were intrusion of the incisors and rotation of the canines. (Am J Orthod Dentofacial Orthop 2018;154:47-54)

The Invisalign appliance was introduced to the public in the late 1990s by Align Technology (Santa Clara, Calif) as a novel method of straightening teeth without braces. Since then, Invisalign has made great progress in terms of treatment planning methods, materials, and manufacturing. The company's powerful marketing has helped to increase the public's demand for clear aligners to the point where Invisalign is an essential part of any orthodontic practice today. There is much speculation regarding its future and the future of orthodontics; however, there is no strong evidence regarding the capabilities and limitations of clear aligners.

In recent years, researchers have used several methods including the American Board of Orthodontics objective grading system, Peer Assessment Rating scores, and other objective occlusal criteria to assess the quality of Invisalign treatment.<sup>1-12</sup> The most notable conclusions were

that Invisalign is not as effective as fixed appliances for expansion,<sup>6</sup> it seems to cause more relapse,<sup>5</sup> and it is not very effective in controlling buccolingual inclination,<sup>4,10,11</sup> occlusal contacts,<sup>4,10,11</sup> occlusal relationships,<sup>4,11</sup> overjet,<sup>4</sup> and overbite.<sup>7</sup> Although these are relatively simple and objective methods of evaluating treatment outcomes, they have some limitations and do not explain the etiology of unsatisfactory results in depth.

A different way of evaluating the accuracy of Invisalign is 3-dimensional (3D) superimposition of predicted and achieved models. A few studies have used 3D superimpositions to measure the accuracy of different types of tooth movements, but the results have been unclear.<sup>13-17</sup> A major limitation of 3D superimpositions is the lack of stable anatomic structures on the predicted models, since ClinCheck (Align Technology) only contains clinical crowns and virtual gingiva. Well-conducted studies of this kind could provide valuable information for efficient treatment planning with ClinCheck. For example, if the accuracy percentage of a specific tooth movement is known, overcorrecting it by the appropriate amount or staging the movement in smaller increments may result in the desired outcome.

Previous studies have obtained valuable information, but there is still much to be learned about the biomechanics and limitations of clear aligners. According to a recent systematic review, the quality of available

<sup>a</sup>Department of Orthodontics, Saint Louis University, St Louis, Mo.

<sup>b</sup>Private practice, Athens, Greece.

All authors have completed and submitted the ICMJE Form for Disclosure of Potential Conflicts of Interest, and none were reported.

Address correspondence to: Ki Beom Kim, Department of Orthodontics, Saint Louis University, 3320 Rutger St, St Louis, MO 63104; e-mail, [kkim8@slu.edu](mailto:kkim8@slu.edu).

Submitted, April 2017; revised and accepted, November 2017.

0889-5406/\$36.00

© 2018 by the American Association of Orthodontists. All rights reserved.

<https://doi.org/10.1016/j.ajodo.2017.11.028>

# Has Invisalign improved? A prospective follow-up study on the efficacy of tooth movement with Invisalign

Nada Haouili,<sup>a</sup> Neal D. Kravitz,<sup>b</sup> Nikhilesh R. Vaid,<sup>a</sup> Donald J. Ferguson,<sup>a</sup> and Laith Makki<sup>a</sup>  
Dubai, United Arab Emirates, and South Riding, Va

**Introduction:** The purpose of this research was to provide an update on the accuracy of tooth movement with Invisalign (Align Technology, Santa Clara, Calif). **Methods:** This prospective clinical study included 38 patients treated with Invisalign Full or Invisalign Teen. All teeth, from the central incisor to the second molar, were measured on digital models created from intraoral scans. Predicted values were determined by superimposing the initial and final ClinCheck models, and achieved values were determined by superimposing the initial ClinCheck models and the digital models from the posttreatment scans. Individual teeth were superimposed with a best-fit analysis and measured using Compare software (version 8.1; GeoDigm, Falcon Heights, Minn). The types of tooth movements studied were a mesial-distal crown tip, buccal-lingual crown tip, extrusion, intrusion, and mesial-distal rotation. **Results:** The mean accuracy of Invisalign for all tooth movements was 50%. The highest overall accuracy was achieved with a buccal-lingual crown tip (56%), whereas the lowest overall accuracy occurred with rotation (46%). The accuracies for mesial rotation of the mandibular first molar (28%), distal rotation of the maxillary canine (37%), and intrusion of the mandibular incisors (35%) were particularly low. **Conclusions:** There was a marked improvement in the overall accuracy; however, the strengths and weaknesses of tooth movement with Invisalign remained relatively the same. (Am J Orthod Dentofacial Orthop 2020;158:420-5)

In 2009, Kravitz et al<sup>1</sup> conducted the first prospective clinical study on Invisalign (Align Technology, Santa Clara, Calif) to evaluate its efficacy. Prior published data included case reports, material studies, technical articles, editorials, surveys, studies comparing Invisalign to conventional fixed appliances, and a systematic review, none of which provided scientific evidence regarding the efficacy or limitations of Invisalign.<sup>2-23</sup> Ten years after Invisalign was introduced, orthodontists were just beginning to quantify how well it moved teeth.

The landmark study by Kravitz et al<sup>1</sup> evaluated the accuracy of anterior tooth movements with Invisalign. Measurements were made by superimposing the predicted and achieved ClinCheck digital models over

the stationary premolars and molars, using ToothMeasure, Align's tooth measurement software.<sup>24</sup> The most accurate movement was lingual constriction (47%), and the least accurate movements were incisor extrusion (18%) and mandibular canine rotation (28%). The overall mean accuracy of Invisalign was 41%.

In a second study, using the same sample and methodology, Kravitz et al<sup>25</sup> specifically evaluated the influence of interproximal reduction (IPR) and ellipsoid attachments on canine rotation. The mean accuracy of this rotation with Invisalign was 36%. The authors reported that canines which received IPR achieved the highest accuracy (43%). Most importantly, the accuracy of canine rotation significantly dropped with rotational movements greater than 15°.

Since these 2 studies were published, significant contributions have been made, further evaluating the efficacy of tooth movement with Invisalign.

In 2012, Krieger et al<sup>26</sup> also evaluated anterior tooth position with Invisalign, but they studied different parameters. Rather than assessing individual tooth movements, the authors evaluated arch length, intercanine distance, overbite, overjet, and midlines by comparing initial and final plaster casts, which were measured with digital calipers. They provided a general

<sup>a</sup>Department of Orthodontics, European University College, Dubai Healthcare City, Dubai, United Arab Emirates.

<sup>b</sup>Private practice, South Riding, Va.

All authors have completed and submitted the ICMJE Form for Disclosure of Potential Conflicts of Interest, and none were reported.

Address correspondence to: Neal D. Kravitz, 25055 Riding Plaza, Ste 110, South Riding, VA 20152; e-mail, [nealkravitz@gmail.com](mailto:nealkravitz@gmail.com).

Submitted, June 2019; revised and accepted, October 2019.

0889-5406

© 2020 by the American Association of Orthodontists. All rights reserved. This is an open access article under the CC BY-NC-ND license (<http://creativecommons.org/licenses/by-nc-nd/4.0/>).

<https://doi.org/10.1016/j.ajodo.2019.12.015>



## Invisalign® treatment in the anterior region Were the predicted tooth movements achieved?

## Invisalign®-Behandlungen im Frontzahnbereich Wurden die vorhergesagten Zahnbewegungen erreicht?

Elena Krieger<sup>1</sup>, Jörg Seiferth<sup>2</sup>, Ivana Marinello<sup>1</sup>, Britta A. Jung<sup>1</sup>, Susanne Wriedt<sup>1</sup>, Collin Jacobs<sup>1</sup>, Heinrich Wehrbein<sup>1</sup>

### Abstract

**Objective.** Based on our previous pilot study, the objective of this extended study was to compare (a) casts to their corresponding digital ClinCheck® models at baseline and (b) the tooth movement achieved at the end of aligner therapy (Invisalign®) to the predicted movement in the anterior region.

**Materials and methods.** Pre- and post-treatment casts as well as initial and final ClinChecks® models of 50 patients (15–63 years of age) were analyzed. All patients were treated with Invisalign® (Align Technology, Santa Clara, CA, USA). Evaluated parameters were: upper/lower anterior arch length and intercanine distance, overjet, overbite, dental midline shift, and the irregularity index according to Little. The comparison achieved/predicted tooth movement was tested for equivalence [adjusted 98.57% confidence interval (–1.00; +1.00)].

**Results.** Before treatment the anterior crowding, according to Little, was on average 5.39 mm (minimum 1.50 mm, maximum 14.50 mm) in the upper dentition and 5.96 mm (minimum 2.00 mm, maximum 11.50 mm) in the lower dentition. After treatment the values were reduced to 1.57 mm (minimum 0 mm, maximum 4.5 mm) in the maxilla and 0.82 mm (minimum 0 mm, maximum 2.50 mm) in the mandible. We found slight deviations between pretreatment casts and initial ClinCheck® ranging on average from –0.08 mm (SD ± 0.29) for the overjet and up to –0.28 mm (SD ± 0.46) for the upper anterior arch length. The difference between achieved/predicted tooth movements ranged on average from 0.01 mm (SD ± 0.48) for the lower anterior arch length, up to 0.7 mm (SD ± 0.87) for the overbite. All parameters were significantly equivalent except for the overbite (–1.02; –0.39).

**Conclusion.** Performed with aligners (Invisalign®), the resolution of the partly severe anterior crowding was successfully accomplished. Resolving lower anterior crowding by protrusion of the anterior teeth (i.e., enlargement of the anterior arch length)

### Zusammenfassung

**Ziel.** Basierend auf unserer vorangegangenen Pilotuntersuchung war das Ziel dieser erweiterten Studie, a) Anfangsmodelle zu Behandlungsbeginn mit der korrespondierenden Anfangsposition im ClinCheck® und b) die mittels Aligner-Therapie (Invisalign®) erreichten Zahnbewegungen mit den prognostizierten Bewegungen im anterioren Bereich zu vergleichen.

**Material und Methode.** Anfangs- und Endmodelle sowie Anfangs- und Endpositionen des ClinChecks® von insgesamt 50 Patienten (15 bis 63 Jahre alt) wurden analysiert. Alle Patienten waren ausschließlich mit Invisalign® (Align Technology, Santa Clara, CA, USA) behandelt worden. Die evaluierten Parameter waren: anteriore Zahnbogenlänge in Maxilla und Mandibula, intercanine Distanz in Maxilla und Mandibula, Overjet, Overbite, dentale Mittellinienverschiebung (Maxilla zu Mandibula) sowie der Irregularitätsindex nach Little. Der Vergleich prognostizierte und erreichte Zahnbewegung wurde getestet auf Äquivalenz [adjustiertes 98,57%-Konfidenzintervall (–1,00; +1,00)].

**Ergebnisse.** Die prätherapeutisch vorliegenden frontalen Engstände (nach Little) von im Mittel 5,39 mm (minimal 1,50 mm, maximal 14,50 mm) in der Maxilla und 5,96 mm (minimal 2,00 mm, maximal 11,50 mm) in der Mandibula wurden durch die Behandlung auf 1,57 mm (minimal 0 mm, maximal 4,5 mm) in der Maxilla und 0,82 mm (minimal 0 mm, maximal 2,50 mm) in der Mandibula reduziert. Es zeigten sich lediglich geringe Abweichungen zwischen Anfangsmodell und Anfangs-ClinCheck® von im Durchschnitt –0,08 mm (SD ± 0,29) für den Parameter Overjet und von bis zu –0,28 mm (SD ± 0,46) für die obere anteriore Zahnbogenlänge. Die Differenz zwischen erreichter und prognostizierter Zahnbewegung betrug von durchschnittlich 0,01 mm (± 0,48) für die untere anteriore Zahnbogenlänge bis 0,7 mm (± 0,87) für den Overbite. Alle Parameter waren signifikant äquivalent außer dem Overbite (–1,02; –0,39).

**Schlussfolgerung.** Die Auflösung der teilweise sehr starken frontalen Engstände wurde durch die Aligner-Behandlung (Invisalign®) erfolgreich durchgeführt. Die Engstandsauflösung mittels Protrusion der Unterkieferfrontzähne (d. h. Vergrößerung der

<sup>1</sup> Department of Orthodontics, Medical Centre of the Johannes Gutenberg-University, Mainz, Germany

<sup>2</sup> Private practice, Mainz, Germany



Research

## Assessment of Invisalign treatment outcomes using the ABO Model Grading System

Waseem Kassas<sup>a</sup>, Thikriat Al-Jewair<sup>b,\*</sup>, C. Brian Preston<sup>c</sup>, Sawsan Tabbaa<sup>d</sup>

<sup>a</sup>Orthodontist and Chairman, Specialized Medical Center Hospital, Riyadh, KSA

<sup>b</sup>Clinical Instructor, Department of Orthodontics, State University of New York, Buffalo, New York

<sup>c</sup>Professor and Chairman, Department of Orthodontics, State University of New York, Buffalo, New York

<sup>d</sup>Assistant Professor, Department of Orthodontics, State University of New York, Buffalo, New York

### ARTICLE INFO

*Article history:*

Received 26 January 2013

Received in revised form

25 February 2013

Accepted 18 March 2013

Available online 18 April 2013

*Keywords:*

Invisalign

Orthodontics

Tooth movement

Treatment outcome

### ABSTRACT

**Background:** A systematic review to determine the treatment effects of the Invisalign system showed that no treatment indications for, or limitations of, Invisalign treatment were supported with scientific evidence. This study was designed to evaluate Invisalign treatment outcomes in mild to moderate malocclusions using the Model Grading System (MGS) of the American Board of Orthodontics.

**Methods:** A total of 425 Invisalign cases were identified from an orthodontic private practice in Buffalo, New York. Of the 425 cases, 119 met the inclusion criteria of having full permanent dentition with a Discrepancy Index (DI) score between 10 and 20 and having been treated completely with Invisalign without extraction. From those 119 cases, 31 had a complete set of records pre- and post-treatment. The pre- and post-treatment models were assessed using the MGS of the American Board of Orthodontics. The Wilcoxon signed rank test was used to compare the pre- and post-treatment MGS scores in all categories.

**Results:** The mean scores of all of the MGS categories were improved after treatment, with the exceptions of the *occlusal contacts* and *occlusal relationships* categories. The improvements were statistically significant in scores in the *alignment* category ( $15.16 \pm 5.00$  vs.  $6.00 \pm 3.78$ ;  $P < 0.001$ ) and the *buccolingual inclination* category ( $7.00 \pm 3.14$  vs.  $6.26 \pm 3.58$ ;  $P = 0.024$ ) and the total MGS score ( $45.03 \pm 7.47$  vs.  $35.87 \pm 9.36$ ;  $P < 0.001$ ).

**Conclusion:** Invisalign treatment when used in mild to moderate malocclusions was effective in correcting tooth alignment and buccolingual inclination; however, it had a negative effect on posterior occlusal contacts and occlusal relationships.

© 2013 World Federation of Orthodontists.

### 1. Introduction

Since the introduction of the Invisalign system (Align Technology, Inc., Santa Clara, California) to the public in 1999, concern has arisen among clinicians regarding the efficacy of Invisalign treatment. Several studies have shown significant limitations of this technique, especially in treating complex malocclusions, whereas other studies have reported successfully treated cases with this removable appliance [1–4]. A systematic review of the literature conducted in 2005 to determine the treatment effects of the Invisalign system showed that no treatment indications for, or limitations of, Invisalign treatment were supported with scientific

evidence [5]. Therefore, clinical trials were still required to investigate the effectiveness of the Invisalign system.

Clements et al. [6] evaluated Invisalign treatment outcomes using weighted peer-assessment rating scores and average incisor irregularity indexes to measure the pretreatment and end-point study models. They found that Invisalign was most successful in improving anterior alignment, transverse relationships, and over bite, whereas buccal occlusion was least improved after treatment. Midline and over jet were moderately improved. In cases of extraction, incisor extraction sites showed a significantly greater percentage of closure than did either maxillary or mandibular premolar extraction sites. Invisalign also caused statistically significant reductions in plaque and gingivitis during treatment. Another study found significant improvement in alignment and over jet scores followed by midline correction after Invisalign treatment [4]. Significant increases in intermolar and intercanine width were also observed. However, over bite

\* Corresponding author: 140 Squire Hall, School of Dental Medicine, State University of New York, Buffalo, NY 14214.

E-mail address: [taljewair@gmail.com](mailto:taljewair@gmail.com) (T. Al-Jewair).



# Upper-Incisor Root Control with Invisalign Appliances

TOMMASO CASTROFLORIO, DDS, PHD  
FRANCESCO GARINO, MD, DO  
ALBERTO LAZZARO  
CESARE DEBERNARDI, MD, DDS

In defining the ideal orthodontic appliance, Proffit wrote that it “must meet certain basic design criteria: it (1) should not interfere with function; (2) should cause no harm to the oral tissues or interfere with the maintenance of good oral hygiene; (3) should be as light and inconspicuous as possible, yet sufficiently strong to withstand masticatory forces and a reasonable amount of abuse; (4) must be firmly retained in position; (5) must be capable of exerting an appropriately controlled force in the correct direction and delivering this force for as long as possible between adjustment visits; and (6) should allow control of anchorage so that tooth movements other than those intended are minimized”.<sup>1</sup>

Although clear aligners would seem to meet all these criteria, some of their biomechanical limits have yet to be overcome.<sup>2-8</sup> One of the most difficult problems to address is control of root movement, especially the buccolingual inclination of the upper incisors. The force couple generated by a thermoplastic aligner torquing an upper incisor consists of a tipping force near the gingival margin and a resulting force produced by movement of the tooth against the opposite inner surface of the appliance, near the incisal edge.<sup>9</sup> Since the gingival margin of the aligner is elastic, it is not surprising that an aligner would have difficulty controlling the forces applied in this region.<sup>10</sup>

Align Technology’s Power Ridge\* is a “twist” of the aligner surface designed to maintain a perfect fit of the aligner at the gingival margin, controlling the force couple and effectively spinning the tooth around its center of resistance (Fig. 1). The twist in the aligner material does not affect its

uniform thickness, avoiding unwanted intrusion from the “watermelon seed effect,”<sup>9,10</sup> in which distortion of the gingival edge moves it away from the tooth surface and thus concentrates force in the occlusal region.<sup>9</sup>

The aim of this study was to test the efficiency of Align Technology’s Power Ridge in controlling the buccolingual inclination of upper incisors.

## Materials and Methods

To assess the efficacy of the Invisalign Power Ridge feature, we examined 12 upper incisors in Invisalign patients needing lingual root torque as part of their treatment. Six consecutive patients (four female, two male, age  $26.3 \pm 10.2$  years) were recruited prospectively from two private orthodontic clinics in a metropolitan area of northwest Italy. Written informed consent was obtained from each patient or parent to take part in the study.

No patient had any record of anterior cross-bite, anterior prosthodontic work, previous orthodontic treatment, craniofacial trauma, surgery, TMD, or orofacial pain. Each patient had been advised to undergo Invisalign treatment using the Power Ridge feature, with no auxiliaries, for lingual root torquing of the upper central incisors. Although two senior clinicians with extensive experience in the Invisalign technique were responsible for the treatment, these six cases were their first with the Power Ridges.

\*Registered trademark of Align Technology, Inc., San Jose, CA; www.aligntech.com.

## Effect of clear aligner therapy on the buccolingual inclination of mandibular canines and the intercanine distance

Thorsten Grünheid<sup>a</sup>; Sara Gaalaas<sup>b</sup>; Hani Hamdan<sup>c</sup>; Brent E. Larson<sup>d</sup>

### ABSTRACT

**Objective:** To compare the changes in buccolingual inclination of mandibular canines and intercanine distance in patients treated with clear aligners to those treated with preadjusted edgewise appliances.

**Materials and Methods:** The buccolingual inclination of mandibular canines and the intercanine distance were measured on pre- and posttreatment cone-beam computed tomograms of 30 patients who had been treated with clear aligners and 30 patients who had been treated with fixed preadjusted edgewise appliances. Differences between the aligner and fixed appliance groups and between pre- and posttreatment measurements were tested for statistical significance.

**Results:** In both groups, most of the mandibular canines had positive buccolingual inclinations (ie, their crowns were positioned lateral to their roots) both before and after treatment. While there was no difference between the groups pretreatment, the posttreatment buccolingual inclination was significantly greater in the aligner group. In the fixed appliance group, the canines became more upright with treatment, while the buccolingual inclination did not change significantly in the clear aligner group. The intercanine distance did not differ between the groups either before or after treatment. However, it increased significantly over the course of treatment in the aligner group, whereas it did not change significantly in the fixed appliance group.

**Conclusions:** Orthodontic treatment with clear aligners tends to increase the mandibular intercanine distance with little change in inclination in contrast to treatment with fixed appliances, which leaves the intercanine distance unchanged but leads to more upright mandibular canines. (*Angle Orthod.* 0000;00:000–000.)

**KEY WORDS:** Aligner; Buccolingual inclination; Cone-beam computed tomography; Intercanine distance; Mandibular canine

### INTRODUCTION

Among the various clear aligner treatment modalities available to orthodontists today, Invisalign<sup>®</sup> is one of the most widely recognized. Developed by Align

Technology Inc in the late 1990s, Invisalign uses three-dimensional (3-D) technology to create a series of aligners to move teeth.<sup>1</sup> Advantages of aligner therapy have been suggested to include improved oral hygiene and periodontal health, superior esthetics, high patient acceptance, and flexibility in terms of their ability to be used in combination with other orthodontic treatment modalities.<sup>1,2</sup> Disadvantages of aligner therapy have been reported to include limited control of root movement and intermaxillary correction, inability to alter course of treatment once aligners are fabricated, limited treatment success with more complex cases, and reliance on patient compliance for treatment success.<sup>1–3</sup> While the efficacy of aligner therapy is well documented,<sup>4–6</sup> objective evidence of its treatment effects is limited. In an effort to gain more knowledge about the clinical effects of aligner therapy, the present study measured its effects on the buccolingual inclination and intercanine distance of mandibular

<sup>a</sup> Assistant Professor, Division of Orthodontics, School of Dentistry, University of Minnesota, Minneapolis, Minn.

<sup>b</sup> Dental Student, School of Dentistry, University of Minnesota, Minneapolis, Minn.

<sup>c</sup> Dentist in Private Practice, Lakeville, Minn.

<sup>d</sup> Associate Professor and Director, Division of Orthodontics, School of Dentistry, University of Minnesota, Minneapolis, Minn.

Corresponding author: Dr Thorsten Grünheid, Division of Orthodontics, School of Dentistry, University of Minnesota, 6-320 Moos Health Science Tower, 515 Delaware Street SE, Minneapolis, MN 55455 (e-mail: tgruenhe@umn.edu)

Accepted: March 2015. Submitted: January 2015.

Published Online: May 22, 2015

© 0000 by The EH Angle Education and Research Foundation, Inc.

# Self-ligating versus Invisalign: analysis of dento-alveolar effects

Chiara Pavoni, DDS  
 Roberta Lione, DDS  
 Giuseppina Laganà, DDS, MS  
 Paola Cozza, MD, DDS, MS

University of Rome "Tor Vergata", Rome, Italy  
 Department of Orthodontics

Corresponding author:  
 Giuseppina Laganà  
 Via G. Baglivi, 5-E  
 00161 Rome, Italy  
 Mobile +39 335 5310894, fax +39 06 44232321  
 E-mail: giuseppinalagana@libero.it

## Summary

**Self-ligating versus Invisalign: analysis of dento-alveolar effects.**

**Aim.** *The aim of this study was to evaluate the changes in the transverse dimension and the perimeter of the maxillary arch produced by low friction self-ligating brackets TIME 3 compared to the Invisalign technique. Materials and methods. Both the self-ligating sample and the Invisalign group were composed of 20 subjects, evaluated at the beginning (T0) and at the completion of therapy (T1). All subjects presented a Class I malocclusion with mild crowding in a permanent dentition, without craniofacial anomalies, missing teeth or a history of orthodontic treatment. Dento-alveolar measurements were made on the maxillary dental casts at T0 and T1. Significant differences between the treated groups were assessed with Independent Samples t test ( $p < 0.05$ ).*

**Results.** *Statistically significant differences between self-ligating sample and Invisalign group were recorded for CWC, FPWF, FPWL, SPWF, SPWL, and AP measurements. No significant changes were found for CWL, MWF, MWL, and AD values. There was not a statistically significant difference between the treatment durations of the groups: 1.8 years for both patients. These data suggest that Invisalign treatment cannot be somewhat faster than fixed appliances. Moreover the final occlusion might not be as ideal.*

**Conclusions.** *The low friction self-ligating system produced statistically significant different outcomes in the transverse dento-alveolar width and the perimeter of the maxillary arch during treatment when compared to Invisalign technique.*

**Key words:** self-ligating, crowding, Invisalign.

## Introduction

The Invisalign system (Align Technology, Santa Clara, Ca, USA) an esthetic orthodontic treatment with removable, clear semielastic polyurethane aligners has become more often a common treatment choice since its first appearance in 1997. This computer-aided modeling technique can fabricate numerous aligners to move teeth with relative precision to obtain a good occlusion. These aligners are made from a thin, transparent plastic that fits over the buccal, lingual/palatal and occlusal surfaces of the teeth. They conventionally are worn for a minimum of 20 hours per day and are changed sequentially every two weeks. Invisalign has been indicated by its manufacturer to be used in adults and adolescents who have fully erupted permanent dentitions (1,2).

Align Technology provides guidelines for the types of malocclusion that can be successfully treated with Invisalign. Cases for which Invisalign is indicated include mild to moderate crowding (1-6 mm), mild to moderate spacing (1-6 mm), nonskeletal constricted arches, and relapse after fixed appliance therapy (3). The manufacturer claims that Invisalign can effectively perform the following orthodontic movements: space closure, alignment after interproximal reduction, dental expansion, flaring, and distalization (4). The Invisalign system has become a popular treatment choice for clinicians because of the esthetics and comfort of the removable clear aligners compared with traditional appliances.

One of the more commonly encountered types of patients who request Invisalign treatment are those who have previously received orthodontic treatment using fixed appliances and do not want fixed appliances for their present orthodontic treatment. Esthetic concerns during follow-up orthodontic treatment may be a significant factor, with many patients not wanting to show metal or partially clear fixed appliances with arch wires when they smile. Another group of patients who want Invisalign are teenagers who wish to improve their esthetics, but are not interested in having the appearance of fixed appliances (5).

To this date, little clinical research has been published to comprehensively study the effectiveness of Invisalign treatment (1-3). The lack of such objective information on this product has made it difficult for clinicians to objectively characterize the efficacy of Invisalign as compared to fixed appliances.

In the last 20 years self-ligating brackets have undergone a renaissance because the concept of self-ligation having been pioneered in 1930s. Self-ligating brackets have a built-mechanism to close off the edgewise slot, obviating the need for elastomers or steel ties to secure the archwire in the bracket slot. The chief advantages of self-ligating system over conventional appliances are claimed to include reduced friction, more robust ligation, more efficient tooth movement and sliding mechanics that can reduce treatment time (6,7).



RESEARCH

Open Access



# Maxillary molar distalization with aligners in adult patients: a multicenter retrospective study

Serena Ravera<sup>1\*</sup>, Tommaso Castroflorio<sup>1</sup>, Francesco Garino<sup>2</sup>, Sam Daher<sup>3</sup>, Giovanni Cugliari<sup>4</sup> and Andrea Deregiibus<sup>1</sup>

## Abstract

**Background:** The aim of the present study was to test the hypothesis that bodily maxillary molar distalization was not achievable in aligner orthodontics.

**Methods:** Forty lateral cephalograms obtained from 20 non-growing subjects (9 male, 11 female; average age 29.73 years) (group S), who underwent bilateral distalization of their maxillary dentition with Invisalign aligners (Align Technology, Inc., San José, CA, USA), were considered for the study. Skeletal class I or class II malocclusion and a bilateral end-to-end class II molar relationship were the main inclusion criteria. Cephalograms were taken at two time points: (T0) pretreatment and (T2) post-treatment. Treatment changes were evaluated between the time points using 39 variables by means of paired *t* test. The level of significance was set at  $P < 0.05$ . Reproducibility of measurements was assessed by the intraclass correlation coefficient (ICC).

**Results:** The mean treatment time was  $24.3 \pm 4.2$  months. At the post-treatment point, the first molar moved distally 2.25 mm without significant tipping ( $P = 0.27$ ) and vertical movements ( $P = 0.43$ ). The second molar distalization was 2.52 mm without significant tipping ( $P = 0.056$ ) and vertical movements ( $P = 0.25$ ). No significant movements were detected on the lower arch. SN<sup>^</sup>GoGn and SPP<sup>^</sup>GoGn angles showed no significant differences between pre- and post-treatment cephalograms ( $P = 0.22$  and  $P = 0.85$ , respectively).

**Conclusions:** Aligner therapy in association with composite attachments and class II elastics can distalize maxillary first molars by 2.25 mm without significant tipping and vertical movements of the crown. No changes to the facial height were revealed.

**Keywords:** Class II, Aligners, Molar distalization, Adult patients

## Background

The distalization of maxillary molars is frequently required in class II non-extraction patients. Resolving class II molar relationships by distalizing maxillary molars may be indicated for patients with minor skeletal discrepancies [1].

The upper molars can be distalized by means of extra or intraoral forces [2]. In recent years, several techniques have been developed to reduce the dependence on patient compliance, such as intraoral appliances with and

without skeletal anchorage. However, even these devices can produce undesirable tipping of the maxillary molars and/or loss of anterior anchorage during distalization [3–9]. In the last decades, increasing numbers of adult patients have sought orthodontic treatment and expressed a desire for esthetic and comfortable alternatives to conventional fixed appliances [10, 11]. Invisalign (Align Technology, Inc., Santa Clara, CA, USA) is an orthodontic system that has been introduced to answer this request. Several case reports [12–14] have shown the possibility of obtaining class II correction with a sequential maxillary molar distalization in non-growing subjects. However, a sound clinical judgment should always be made on the basis of a higher level of evidence.

\* Correspondence: serenaravera@gmail.com

<sup>1</sup>Post-Graduate School of Orthodontics, Lingotto – Dental School, Department of Surgical Sciences, University of Turin, Turin, Italy  
Full list of author information is available at the end of the article

# How effective is the Invisalign® system in expansion movement with Ex30' aligners?

B. Solano-Mendoza<sup>1</sup> · B. Sonnemberg<sup>2</sup> · E. Solano-Reina<sup>1</sup> · Alejandro Iglesias-Linares<sup>3</sup>

Received: 12 October 2015 / Accepted: 7 July 2016 / Published online: 19 July 2016  
© Springer-Verlag Berlin Heidelberg 2016

## Abstract

**Objectives** The aims of this study are to validate a new method for quantifying the predictability of expansion movement with the Invisalign® system and to determine whether there are statistically significant differences between planned expansion with ClinCheck® and actual clinical quantification using upper post-treatment model comparisons.

**Materials and methods** A sample of 116 patients subjected to expansion with Invisalign® was studied. The following variables were measured at T1 and T2 on 3D models and ClinCheck®: canine gingival width, first premolar gingival width, second premolar gingival width, first molar gingival width, canine cuspid width, first premolar cuspid width, second premolar cuspid width, first molar cuspid width, canine depth, arch depth, first molar rotation, first right and left molar rotation, and first molar inclination.

**Results** Measurement error was tested, showing good precision for all variables. The paired test showed non-significant differences between the 3D model and ClinCheck® at T1 for all variables except first molar cuspid width and arch depth. Statistically significant

differences were found for canine gingival width, first premolar gingival width, second premolar gingival width, first molar gingival width, canine cuspid width, first premolar cuspid width, second premolar cuspid width, first molar cuspid width, and canine depth when the 3D model and ClinCheck® were compared at T2.

**Conclusions** Differences between the 3D model and ClinCheck® at T2 showed that planned expansion at the end of treatment is not predictable.

**Clinical relevance** This is the first in vivo human study to quantify the predictability of expansion in patients with Invisalign® Ex30 material.

**Keywords** Invisalign · Orthodontics · ClinCheck · Predictability

## Introduction

The predictability of movements has been little studied to date [1]. Only a few articles are available on transversal expansion with the Invisalign® appliance, and none of them have studied the accuracy of ClinCheck®. Clements et al. [2] evaluated the peer assessment rating (PAR) index in 51 patients at the start and end of treatment. One of the components evaluated by the PAR index is transversal occlusion. The authors observed that 26 of the 51 patients started with correct transversal occlusion, and the latter was maintained until the end. Of the remaining 25 patients that started with a non-ideal transversal situation, 79 % were seen to improve, 17 % showed no change, and 4 % worsened. The patients were randomly assigned to four treatment protocols: change of aligner every 7 days with a soft material, change of aligner every 7 days with a hard material change of aligner every

---

**Electronic supplementary material** The online version of this article (doi:10.1007/s00784-016-1908-y) contains supplementary material, which is available to authorized users.

---

✉ Alejandro Iglesias-Linares  
aleigl01@ucm.es

<sup>1</sup> School of Dentistry, University of Seville, C/ avicena sn, Seville, Spain

<sup>2</sup> Stuttgart, Germany

<sup>3</sup> School of Dentistry, Complutense University of Madrid, Plaza Ramón y Cajal sn, 28040 Madrid, Spain

## Efficiency of upper arch expansion with the Invisalign system

Ning Zhou<sup>a</sup>; Jing Guo<sup>b</sup>

### ABSTRACT

**Objectives:** To investigate the efficiency and movement pattern of upper arch expansion using Invisalign aligners. The correlation between the amount of designed expansion and the efficiency of bodily expansion was evaluated, as were the initial molar torque and efficiency of bodily expansion.

**Materials and Methods:** Twenty Chinese adult patients who underwent arch expansion with Invisalign aligners were included in this study. Records of pretreatment (T0 stage) and immediately after completing the expansion phase (T1 stage) were collected, including digital models and cone-beam computed tomography. Dolphin 3D, Geomagic Studio 12.0, and Measure software were employed to measure data and calculate differences between the expected and actual outcomes.

**Results:** There were significant differences between the expected and actual expansion amounts ( $P < .05$ ). The average expansion efficiencies of the upper canine crown, first premolar crown, second premolar crown, and first molar crown were  $79.75 \pm 15.23\%$ ,  $76.1 \pm 18.32\%$ ,  $73.27 \pm 19.91\%$ , and  $68.31 \pm 24.41\%$ , respectively. The average efficiency of bodily expansion movement for the maxillary first molar was  $36.35 \pm 29.32\%$ . Negative correlations were found between preset expansion amounts and the efficiency of bodily expansion movement ( $P < .05$ ), and between initial maxillary first molar torque and efficiency of bodily expansion movement ( $P < .05$ ).

**Conclusions:** Aligners could increase the arch width, but expansion was achieved by tipping movement. The evaluation of initial position and preset of sufficient root-buccal torque of posterior teeth were necessary due to the lower efficiency of bodily buccal expansion by the Invisalign system. (*Angle Orthod.* 2020;90:23–30.)

**KEY WORDS:** Clear treatment; Expansion; Efficiency; Three-dimensional

### INTRODUCTION

In 1946, Kesling proposed to manufacture a series of removable appliances called “aligners.” The underlying concept was to move teeth in a series of planned individual stages using positioners fabricated by thermoplastic material molding technology.<sup>1</sup> In 1997, the company Align Technology converted Kesling’s idea into a feasible treatment approach: a series of

clear aligners, combining appliance production with computer-aided design/manufacturing (CAD/CAM) stereolithographic technology. Since its introduction as an esthetic alternative to fixed labial braces, the Invisalign appliance has evolved. Its unique advantages over traditional appliances include esthetics, comfort, removal for better hygiene, shorter appointment times, and 3D control of tooth movement.<sup>2,3</sup> However, a portion of Invisalign patients require mid-course correction, case refinement, or conversion to fixed appliances before the end of treatment,<sup>4</sup> so some doubts remain among clinicians about the efficiency and accuracy of teeth movement with the appliance.

Dental crowding is a leading reason that people seek orthodontic treatment. Expansion of a compressed arch as a method of resolving crowding can increase arch length, thus providing more space for tooth alignment. It can also improve the transverse dimension of the smile or correct dentoalveolar posterior crossbites.<sup>5,6</sup> Some literature<sup>7,8</sup> has stated that buccal expansion can be achieved by Invisalign to relieve dental crowding, as an alternative to interproximal reduction or to modify the arch form. Malik et al.<sup>9</sup>

<sup>a</sup> Graduate Student, Department of Orthodontics, School of Stomatology; and Shandong Provincial Key Laboratory of Oral Biomedicine, Shandong University, Jinan, Shandong, China.

<sup>b</sup> Professor and Department Chair, Department of Orthodontics, Stomatology Hospital, School of Stomatology, Shandong University, Jinan, Shandong, China.

Corresponding author: Dr Jing Guo, Department of Orthodontics, Room 201, Stomatology Hospital, School of Stomatology, Shandong University, 44-1 West Wenhua Street, Jinan 250012, Shandong, China  
(e-mail: guojing@sdu.edu.cn)

Accepted: May 2019. Submitted: February 2019.

Published Online: August 1, 2019

© 2020 by The EH Angle Education and Research Foundation, Inc.





# Management of overbite with the Invisalign appliance

Roozbeh Khosravi,<sup>a</sup> Bobby Cohanim,<sup>a</sup> Philippe Hujuel,<sup>b</sup> Sam Daher,<sup>c</sup> Michelle Neal,<sup>d</sup> Weitao Liu,<sup>a</sup> and Greg Huang<sup>a</sup>

Seattle and Kirkland, Wash, and Vancouver, British Columbia, Canada

**Introduction:** Most of the published literature on the management of overbite with the Invisalign appliance (Align Technology, Santa Clara, Calif) consists of case reports and case series. **Methods:** In this retrospective study of 120 patients, we sought to assess the nature of overbite changes with the Invisalign appliance. Records were collected from 3 practitioners, all experienced with the Invisalign technique. The patients were consecutively treated adults (>18 years old) who underwent orthodontic treatment only with the Invisalign appliance. Patients with major transverse or anteroposterior changes or extraction treatment plans were excluded. The study sample included 68 patients with normal overbites, 40 with deepbites, and 12 with open bites. Their median age was 33 years, and 70% of the patients were women. **Results:** Cephalometric analyses indicated that the deepbite patients had a median overbite opening of 1.5 mm, whereas the open bite patients had a median deepening of 1.5 mm. The median change for the normal overbite patients was 0.3 mm. Changes in incisor position were responsible for most of the improvements in the deepbite and open bite groups. Minimal changes in molar vertical position and mandibular plane angle were noted. **Conclusions:** The Invisalign appliance appears to manage the vertical dimension relatively well, and the primary mechanism is via incisor movements. (Am J Orthod Dentofacial Orthop 2017;151:691-9)

The Invisalign appliance (Align Technology, Santa Clara, Calif) consists of a series of computer-designed clear plastic shells that fit closely over the teeth and incrementally move the teeth to their correct position.<sup>1,2</sup> Orthodontic treatment with the Invisalign appliance may be more esthetically appealing to some patients when compared with conventional fixed appliances; this partly explains the increasing demand for this treatment method.<sup>3</sup>

The Invisalign technique was initially proposed to treat mild orthodontic cases.<sup>2,4-6</sup> Nonetheless, there are reports of complex orthodontic cases treated with the Invisalign appliance in the literature.<sup>7-9</sup> For example, a recent study demonstrated the successful closure of a

4-mm anterior open bite by extrusion of the anterior teeth using a series of 35 Invisalign aligners.<sup>9</sup>

Soon after the introduction of the Invisalign system in the late 1990s, practitioners noticed that the appliance commonly induced deepening of the overbite.<sup>10</sup> It was suggested that aligners covering all posterior teeth could function as a bite-block, thereby intruding the posterior teeth. This would result in a reduction of the posterior vertical dimension and consequent deepening of the overbite.<sup>11</sup>

The Invisalign system has evolved over the last 16 years, and various strategies have been developed to better manage the vertical dimension. For example, an early strategy to prevent bite deepening was the removal of occlusal coverage on the second molars. Align Technology recently developed new treatment options including specially designed attachments and virtual bite ramps. Attachments are composite buttons attached to the labial surfaces of the teeth, and they come in various shapes to assist with tooth movement. Specifically, these attachments increase retention, transmit desirable force to the teeth, and support auxiliary functions such as placement of elastics.<sup>12</sup> Virtual bite ramps function similar to bite plates or bite turbos. These bite ramps, incorporated into the maxillary aligner, contact the mandibular incisors to disocclude the posterior teeth when patients bring their teeth together.

<sup>a</sup>Department of Orthodontics, School of Dentistry, University of Washington, Seattle, Wash.

<sup>b</sup>Department of Oral Health Sciences, School of Dentistry, University of Washington, Seattle, Wash.

<sup>c</sup>Private practice, Vancouver, British Columbia, Canada.

<sup>d</sup>Private practice, Kirkland, Wash.

All authors have completed and submitted the ICMJE Form for Disclosure of Potential Conflicts of Interest, and none were reported.

Funded by the University of Washington Orthodontic Alumni Association.

Address correspondence to: Roozbeh Khosravi, University of Washington, Department of Orthodontics, Box 357446, Room location: HSB-D5691959, NE Pacific St., Seattle, WA 98195; e-mail, [Roozkh@uw.edu](mailto:Roozkh@uw.edu).

Submitted, May 2016; revised and accepted, September 2016.

0889-5406/\$36.00

<http://dx.doi.org/10.1016/j.ajodo.2016.09.022>

## **Invisalign and Traditional Orthodontic Treatment Postretention Outcomes Compared Using the American Board of Orthodontics Objective Grading System**

**Daniel Kuncio<sup>a</sup>; Anthony Maganzini<sup>b</sup>; Clarence Shelton<sup>c</sup>; Katherine Freeman<sup>d</sup>**

### **ABSTRACT**

**Objective:** To compare the postretention dental changes between patients treated with Invisalign and those treated with conventional fixed appliances.

**Materials and Methods:** This is a comparative cohort study using patient records of one orthodontist in New York City. Two groups of patients were identified that differed only in the method of treatment (Invisalign and Braces group). Dental casts and panoramic radiographs were collected and analyzed using the objective grading system (OGS) of the American Board of Orthodontics (ABO). The cases were evaluated immediately after appliance removal (T1) and at a postretention time (T2), three years after appliance removal. All patients had completed active orthodontic treatment and had undergone at least one year of retention. A Wilcoxon rank sum test was used to evaluate differences in treatment outcomes between the groups for each of the eight categories in the OGS, including four additional subcategories in the alignment category. A Wilcoxon signed rank test was used to determine the significance of changes within each group from T1 to T2.

**Results:** The change in the total alignment score in the Invisalign group was significantly larger than that for the Braces group. There were significant changes in total alignment and mandibular anterior alignment in both groups. There were significant changes in maxillary anterior alignment in the Invisalign group only.

**Conclusions:** In this sample for this period of observation, patients treated with Invisalign relapsed more than those treated with conventional fixed appliances.

**KEY WORDS:** Invisalign; Cohort study; Objective grading system; Treatment outcome; Relapse

### **INTRODUCTION**

In 1999, Align Technology Inc addressed the demand for an esthetic alternative to braces by developing an "invisible" method of orthodontic treatment (Invisalign) that uses a series of computer-generated, clear, removable aligners to move the dentition. Since

then, Invisalign has been used to treat over 300,000 orthodontic patients with a variety of malocclusions. The primary benefit of the Invisalign system is the superior esthetics during treatment compared to metal braces. Other advantages of the system include the ability to remove aligners to eat, brush and floss, and the superior comfort and ease of use.<sup>1</sup>

Based on case reports, this technique appears effective in treating mild malocclusions and is more visually appealing than conventional braces.<sup>2</sup> Align has claimed that 90% of orthodontic patients are candidates for Invisalign. These include patients with mild to moderate crowding (1–6 mm), mild to moderate spacing (1–6 mm), nonskeletal constricted arches, and those who have experienced relapse after fixed appliance therapy.<sup>3</sup>

To this date, little clinical research has been published to comprehensively study the effectiveness of Invisalign treatment. The lack of such objective information on this product has made it difficult for clini-

<sup>a</sup> Former orthodontic resident, Montefiore Medical Center/Albert Einstein College of Medicine, Bronx, NY.

<sup>b</sup> Department Head, Department of Orthodontics, Montefiore Medical Center/Albert Einstein College of Medicine, Bronx, NY.

<sup>c</sup> Assistant Professor, Department of Orthodontics, Montefiore Medical Center/Albert Einstein College of Medicine, Bronx, NY.

<sup>d</sup> Associate Professor, Department of Epidemiology and Population Health, Albert Einstein College of Medicine, Bronx, NY.

Corresponding author: Dr Daniel Kuncio, Montefiore Medical Center, Department of Orthodontics, 3332 Rochambeau Ave, New York, NY 10467 (e-mail: kuncioorthodontics@nyc.rr.com)

Accepted: November 2006. Submitted: October 2006.

© 2007 by The EH Angle Education and Research Foundation, Inc.



**TREATMENT AND POST-TREATMENT POSTERIOR OCCLUSAL  
CHANGES IN INVISALIGN® AND TRADITIONAL BRACES: A  
RANDOMIZED CONTROLLED TRIAL**

A Thesis

by

KATHRYN ANN PRESTON

Submitted to the Office of Graduate and Professional Studies of  
Texas A&M University  
in partial fulfillment of the requirements for the degree of

MASTER OF SCIENCE

Chair of Committee,	Peter H. Buschang
Committee Members,	Phillip M. Campbell
	Katie C. Julien
	William W. Nagy
Head of Department,	Larry Bellinger

May 2017

Major Subject: Oral Biology

Copyright 2017 Kathryn Ann Preston